

# OCCULT CANCER WITH CERVICAL LYMPH NODE METASTASIS: HISTOLOGIC PROFILE OF CERVICAL LYMPH NODE AND PAN-ENDOSCOPIC BIOPSIES AT UNIVERSITY COLLEGE HOSPITAL, IBADAN, NIGERIA.

John Emmanuel N<sup>1</sup>, Okani Chukwudi O<sup>2</sup>, Adeosun Ademola A<sup>1</sup>, Akang Effiong E.<sup>2</sup>

\* Department of Ear, Nose and Throat/Head & Neck Surgery, University College Hospital, Ibadan, Nigeria.

\*\* Department of Pathology, University College Hospital, Ibadan, Nigeria.

All correspondence and requests for reprints are to be directed to Dr. Okani CO,

Department of Pathology, Benue State University, Makurdi, Nigeria.

Email: chudiokani@yahoo.com

## ABSTRACT

**Background:** Occult cervical lymph node metastasis is a relatively rare oncologic disease presenting as a neck lump without an obvious mucosal lesion. Most cases arise from the upper aerodigestive tract and affect all ages. It is often a diagnostic dilemma when there is no facility to carry out a thorough evaluation.

**Methods:** A prospective study of all patients with neck lump with unknown primary tumor site evaluated within the periods, January 2010 to December 2012 at the ENT/Head and Neck Department of University College Hospital, Ibadan. The patients went through clinical, radiological and endoscopic assessments. Fine Needle Aspirate and Cytology (FNAC) of neck node and random pan-endoscopic specimens obtained were cytological and histological analysed.

**Results:** The prevalence of cervical nodal metastasis with unknown primary site was 9.7%. We found no gender predilection in the study. Majority of the patients with occult cervical node metastases were in the third decade of life. The histological yield of pan-endoscopy biopsy specimen was 72%. Undifferentiated nasopharyngeal squamous (39%) cell carcinoma was the commonest diagnosis following random biopsy during pan-endoscopy.

**Conclusion:** Despite limitations arising from lack of FDG PET, the yield from pan-endoscopy biopsy specimen was appreciable. Inadequate immunohistological stains and lack of FDG PET scan may have diminished the histological yield of the blind pan-endoscopy biopsy specimens.

**Key Words:** Cervical nodal metastasis with unknown primary site, pan-endoscopy biopsy, occult cancer

## INTRODUCTION

The definition of metastatic cancer of unknown primary is a biopsy-confirmed malignancy for which the site of origin at routine workup is not identified<sup>1</sup>. Cervical lymph node metastasis from unknown primary site is a relatively rare event. It presents as a neck lump without an obvious mucosal lesion. The majority of these tumors arise from upper aerodigestive tract. Studies of head and neck squamous cell carcinoma (HNSCC) <sup>2,3,4,5</sup> estimate that the incidence of cervical lymph node metastasis with no obvious primary site ranges from 3% to 9%, with squamous cell carcinoma (SCC) constituting about 75% of the tumor.

Due to the protean possible causes of neck masses, the assessment of the patients has to be fast-tracked

and this must follow a strict protocol for timely and appropriate diagnosis. The clinical evaluation of these patients includes a complete medical history and physical examination, chest radiography, indirect or flexible fiber-optic endoscopy. Computed tomography may be useful in evaluation of the chest, neck and skull base. Pan endoscopy often entails performing laryngoscopy, bronchoscopy, esophagoscopy, fiber-optic nasopharyngoscopy and biopsy of all suspicious lesions or areas (tongue base, nasopharynx, tonsils, piriform sinus and bronchus) needed to be done for the evaluation of the upper aerodigestive tract and lungs. The recommendation is that in cases of negative biopsy results from the random or blind biopsies, any identified solitary enlarged lymph

node with the capsule intact should be biopsied. Pre-operative FNAC of the cervical mass is also helpful in cases of diagnostic dilemma<sup>2,6</sup>.

The most frequent histopathologic diagnosis is SCC accounting for 65% to 76% of cervical lymph node metastasis from unknown primary site, followed by undifferentiated carcinoma (14%), adenocarcinoma (13%) and nasopharyngeal-type carcinoma (8%)<sup>7</sup>. Approximately one third of the metastasis from unknown primary site are found in lymph node<sup>8</sup> and over 90% of the neck metastasis comprises SCC<sup>9</sup>, whereas undifferentiated carcinoma, adenocarcinoma and other malignancies (thyroid carcinoma, malignant melanoma) are less common in western world. Undifferentiated carcinomas are commoner in countries with high prevalence of nasopharyngeal carcinoma.

There are two theories postulated to explain why the primary neoplasms may be occult in nature. The first theory suggests that the occult primary may be due to complete involution of the primary lesion or due to a genetic influence, which favors metastatic growth over primary tumor growth<sup>10</sup>.

Neck nodal metastases present mostly as firm solid masses but a distinct subset of lymph nodes with metastases may present as cystic masses and these frequently relate to thyroid carcinoma followed by SCC and melanoma<sup>11</sup>. Goldenberg et al<sup>12</sup> observed that certain SCCs of the tonsils are more likely to produce cystic metastasis. Nodal metastasis can be found in every neck level, while metastasis from unknown primary site are most frequently found in level II<sup>13,14,15,16</sup>. Neck nodes from unknown primary site present bilaterally in 10% of cases<sup>15,17</sup>. In general, nodes in levels I to III are presumably due to primary SCC located in the mucosa of the aerodigestive tract<sup>18,19</sup>, whereas nodes in levels IV and Vb more often arise from proximal esophageal and thyroid carcinoma<sup>20,21</sup>. Lymph nodes in level IIb and Vb are more typical of nasopharyngeal carcinoma<sup>11</sup>.

The purpose of this study is to determine the prevalence of cervical nodal metastasis with unknown primary tumor site in a tertiary health facility in West African sub-region and to find out the histological profile and yield of cervical nodal and/or random biopsies from pan-endoscopy.

## **PATIENTS AND METHOD**

We prospectively collated data of patients with

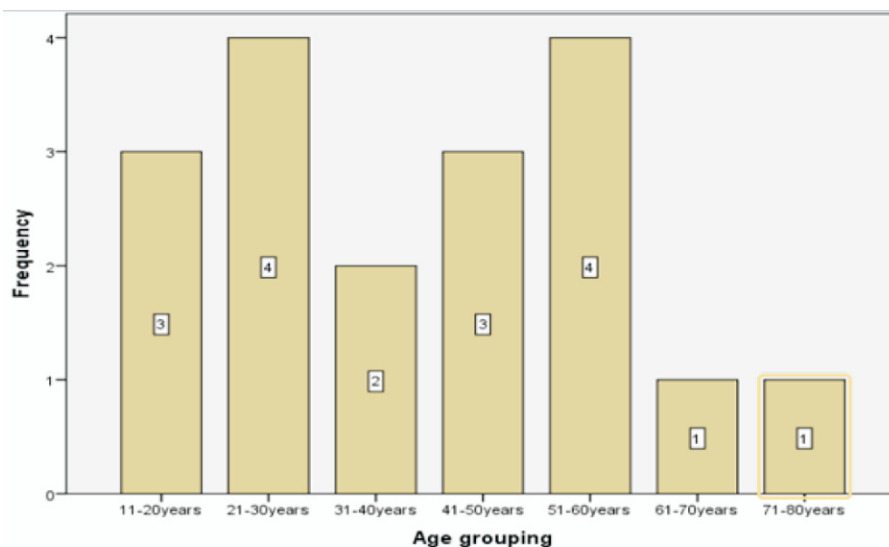
cervical lymph nodes with unknown primary sites who had FNAC, Computerized tomographic scan, pan-endoscopy and random surgical biopsies of upper aerodigestive tract and/or solitary cervical lymph node excision biopsy over a three years period from January 2010 to December 2013 at University College Hospital, Ibadan, Nigeria. Only patients with unknown primary tumor after clinical, computerized tomography scan of neck/thorax and endoscopic evaluations enrolled for the study.

## **RESULTS**

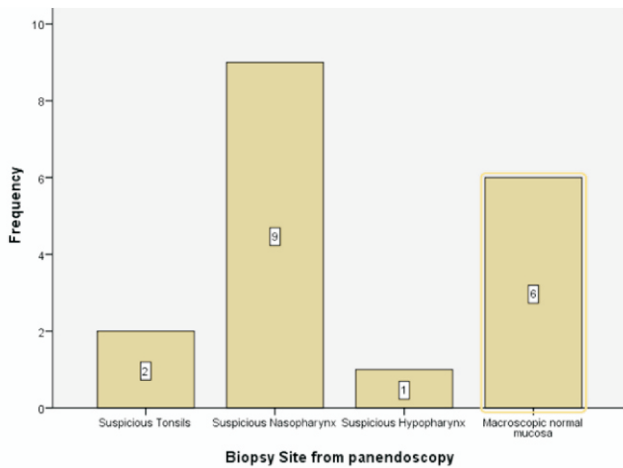
One hundred and eighty five patients with head and neck cancers admitted for evaluation and treatment by Otorhinolaryngology Department and Oral/Maxillofacial Department at the University College Hospital within the study period, January 2010 to December 2012. Eighteen patients out of the 185 patients had cervical lymph node metastasis with unknown primary site. The prevalence of cervical nodal metastasis with unknown primary site in this study is 9.7%. These patients with positive nodal metastasis had a male to female ratio of 0.8: 1. The mean age of the study population was 39.6 years with majority (22.2%) of the patients in the third decade of life. Ten (56%) patients had right sided neck swelling, 4(22%) patients had bilateral neck swellings and 4(22%) patients had left sided neck swelling. Three of the patients with bilateral neck swellings had nasopharyngeal undifferentiated squamous cell cancer and the fourth patient had nasopharyngeal neurofibrosarcoma. Cervical nodal level involvement of levels IIB, III and IV were consistent with nasopharyngeal cancer. The FNAC was only positive minimal invasive diagnostic investigation for cervical nodal metastatic thyroid malignancy. Pan endoscopy was often indicated when FNAC was reported to be suspicious of malignancy. The histologic yield of pan endoscopic biopsy was 72%. Two (15%) patients had well differentiated SCC of nasopharynx, 1(8%) patient had moderately differentiated SCC of nasopharynx, 5(39%) patients had undifferentiated SCC of nasopharynx, 2 (15%) patients had low grade NHL of nasopharynx, 2 (15%) patients had high grade large cell NHL of the tonsils and 1(8%) patient had moderately differentiated SCC of the hypo pharynx. Cervical nodal biopsy histology of NHL correlated positively with blind tissue histology obtained from pan-endoscopy specimen. Nine (50%) of the patients had unknown primary tumor site in the nasopharynx and this was found to be the commonest anatomic site for unknown primary site in the study population. The results of the study are summarized in table 1, figures 1, 2 and 3.

**Table 1: Showing Summary of Results in the study Population with Cervical Nodal Metastasis and unknown Primary Tumour Site**

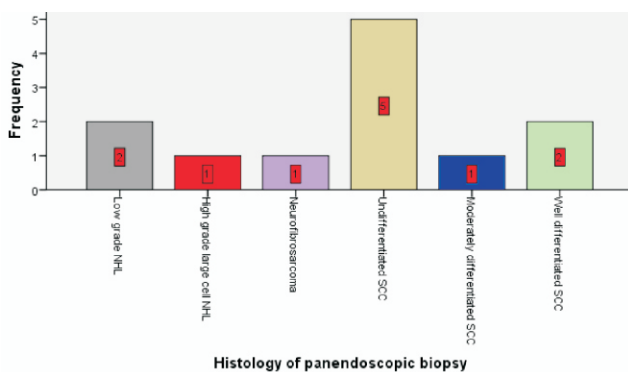
S/No	Age in years	Sex	Side of nodal metastasis	Nodal size in Cm	Nodal level	Nodal FNAC	Nodal Histology	Pan-endoscopic Tissue biopsy(Primary site)	Histological report of Tissue biopsies
1	12	F	Right	5 x 4	IIA,IIB	Suspicious of malignancy	NHL	Tonsils	High grade large cell NHL
2	22	F	Bilateral	8 x 6	IIB, III,IV	Suspicious of malignancy	NHL	Nasopharynx	Low grade NHL
3	20	F	Bilateral	10 x10	III,IV, VA	Not suspicious of malignancy	B <sub>2</sub> Thymoma	No suspicious site seen	All tissues biopsied were negative for malignancy
4	71	F	Right	8 x 6	III,IV	Metastatic follicular thyroid Ca	Not performed	No suspicious site seen	All tissues biopsied were negative for malignancy
5	54	F	Right	6 x 4	III,IV	Metastatic papillary thyroid Ca	Not performed	No suspicious site seen	All tissues biopsied were negative for malignancy
6	56	M	Right	8 x 6	IIB,III, IV	Suspicious of malignancy	Not performed	Nasopharynx	Undifferentiated SCC
7	28	M	Bilateral	9 x 8	III,IV	Not suspicious of malignancy	Not performed	Nasopharynx	Neurofibrosarcoma
8	24	M	Bilateral	10 x 7	IIB,III, IV	Suspicious of malignancy	Not performed	Nasopharynx	Undifferentiated SCC
9	44	M	Right	6x 4	IIB,III	Suspicious of malignancy	Not performed	Nasopharynx	Undifferentiated SCC
10	48	M	Left	4 x 3	IIA,III	Suspicious of malignancy	Not performed	Tonsils	High grade large cell NHL
11	46	F	Left	2 x 2	VB	Suspicious of malignancy	Moderate grade NHL	No suspicious site seen	All tissues biopsied were negative for malignancy
12	68	F	Right	5 x 3	III,IV	Suspicious of malignancy	Not performed	Hypopharynx	Well differentiated SCC
13	38	M	Right	7 x 5	III,IV, VA	Suspicious of malignancy	Low grade NHL	Nasopharynx	Low grade large cell NHL
14	32	M	Left	3 x 2	I,IIA	Suspicious of malignancy	Alveolar rhabdomyosarcoma	No suspicious site seen	All tissues biopsied were negative for malignancy
15	21	F	Right	4 x 3	III	Suspicious of malignancy	Not performed	Nasopharynx	Undifferentiated SCC
16	53	F	Left	4 x 4	III,IV	Suspicious of malignancy	Not performed	Nasopharynx	Well differentiated SCC
17	57	F	Right	6 x 4	III,IV	Suspicious of malignancy	Not performed	Nasopharynx	Undifferentiated SCC
18	19	F	Right	5 x 4	III,IV	Suspicious of malignancy	Not performed	Nasopharynx	Moderately differentiated SCC



**FIGURE 1- Showing Age Distribution by Decades in the study population**



**FIGURE 2:** Showing Macroscopic findings at Panendoscopy



**FIGURE 3:** Showing Histologic Profile of Panendoscopic Biopsies in the study population

**DISCUSSION**

Metastatic cancer with unknown primary tumor site is said to be the 7th most common malignancy<sup>22</sup>. The prevalence of cervical nodal metastasis with unknown primary site in our study population was 9.7%. The prevalence in our study agrees with earlier report in literature by de Braud and Al-Sarraf who found a prevalence of 3%-9%<sup>2</sup>.

While works by some authors<sup>23, 24</sup>, revealed a male preponderance for cervical nodal metastasis with unknown primary site in their series, we did not find a significant gender predilection. Neck lymph nodes with metastasis of unknown primary site were more common in the 3rd decade of life in our study population. This pattern is not in conformity with the works of Azlan and co-workers who found that the most common age group affected in their work was the middle age patients<sup>23</sup>. Furthermore, nodal cancer spread appears to favor involvement of the right side of the neck in 50% of the patients in our series. This observation may just be a chance finding. The most affected cervical nodal levels in

our work were levels IIB, III and IV. Nasopharyngeal carcinoma was the commonest cancer type responsible for level II, III and IV metastasis. These findings are in conformity with other reports in the literature linking metastasis to cervical nodal level I to III and primary SCC located in mucosa of the upper aerodigestive tract<sup>18, 25, 26</sup>.

Prior to pan-endoscopy and biopsy for the elusive primary tumor site, patients in the study underwent FNAC of neck nodes and CT scan of the neck. A positive FNAC result re-enforced the suspicion of malignancy in 14 cases and was the last resort as the only diagnostic investigation in the two cases of thyroid malignancies. Thirteen cases that had suspicious areas on the mucosa at upper aerodigestive tract pan-endoscopy were solitary cervical lymph node excisional biopsy were avoided. In these group of patients, the suspicious areas of the nasopharynx was randomly curetted using adenoid curette, the suspicious areas of the hypopharynx was blindly biopsied using cupped biting biopsy forceps while bilaterally biopsy tonsillectomy was done in 16 patients except the 2 cases with metastatic malignant thyroid diseases identified from FNAC of cervical lymph nodes.

The remaining 5 patients in our study population, solitary cervical lymph node excisional biopsy became necessary when macroscopically suspicious areas were not visualized during fiber-optic laryngoscopy, nasopharyngoscopy or rigid hypopharyngoscopy. Although, a direct effect of a neck node biopsy on tumor recurrence has not been demonstrated, incisional biopsy is strongly discouraged due to the risk of further dissemination or seeding of tumor and the adverse effect on subsequent surgery of the neck by scar formation<sup>27</sup>.

Out of the 16 randomly performed bilateral tonsillectomies in the 16 patients, only 2 patients had a report of malignancy in their tonsillar specimens. Generally, the histologic yield of pan-endoscopic biopsy in our study was 72.2%. This finding in our work is higher than the biopsy yield recorded in the works of Acquarelli et al and Coker et al<sup>28, 29</sup> but lower than the findings of Azlan and co-workers who had a biopsy yield of 90%. Didolker and colleagues reported that in patients with primary lesions, which have escaped detection by a staging workup, the unknown primary tumor site may be identified in 30% to 82% of the cases at autopsy<sup>24</sup>.

Fluoro-2-deoxy-D-glucose positron emission tomography (FDG PET) scan was a useful

investigation in the workup of patients with metastatic cancers with unknown primary site. Studies from literatures suggest that biopsies carried out after FDG PET can improve the number of occult primary detected compared with endoscopic examination with speculative biopsies<sup>30,32</sup>. The lack of FDP-PET CT in our center was a setback that would have increased the diagnostic yield of investigations for unknown primary tumor site.

## CONCLUSION

Metastasis to cervical lymph nodes with unknown primary tumor site is not uncommon. Due to limited facility for proper investigation in developing countries of the West African sub-region, the search for the definitive anatomic site of origin of head and neck malignancy is still a daunting task in many facilities. The dearth of investigative tools such as FDG PET scan and immunohistochemical stains may have diminished the yield of random pan endoscopy biopsies in our study. Irrespective of the age of the study population, nasopharyngeal squamous cell carcinoma was most common cause of cervical nodal metastasis with unknown primary site.

## REFERENCES

1. Abbruzzese JL, Raber MN. Unknown primary. In: Clinical oncology. New York: Churchill Livingstone Inc; 1995:1833-1845
2. de Braud F, al-Sarraf M. Diagnosis and management of squamous cell carcinoma of unknown primary tumor site of the neck. *Semin Oncol* 1993; 20:273-8
3. Lee DJ, Rostock RA, Harris A, Kashima H, Johns M. Clinical evaluation of patients with metastatic squamous carcinoma of the neck with occult primary tumor. *South Med J* 1986; 79:979-83
4. Fried MP, Diehl WH Jr, Brownson RJ, Sessions DG, Ogura JH. Cervical metastasis from an unknown primary. *Ann Otol Rhinol Laryngol* 1975; 84:152-7.
5. Comess MA, Beahrs OH, Dockerty MB. Cervical metastasis from occult carcinoma. *Surg Gynecol Obstet* 1957; 104:607-17.
6. Davidson BJ, Spiro RH, Patel S, Patel K, Shah JP. Cervical metastases of occult origin: the impact of combined modality therapy. *Am J Surg* 1994; 168:395-9.
7. Haas I, Hoffmann KT, Enger R, Ganzer U. Diagnostic strategies in cervical carcinoma of an unknown primary (CUP). *Eur Arch Otorhinolaryngol* 2002; 259:325-33.
8. Abbruzzese JL, Abbruzzese MC, Hess KR, Raber MN, Lenzi R, Frost P. Unknown Primary Carcinoma: Natural history and prognostic factors in 657 consecutive patients. *J Clin Oncol* 1994; 12(6):1272-1280.
9. Schmalbach CE, Miller FR. Occult primary head and neck carcinoma. *Curr Oncol* 2007; 9(2):139-146.
10. Chorost MI, McKinley B, Tschoi M, Ghosh BC. The management of the unknown primary. *J Am Coll Surg* 2001; 193(6):666677.
11. Ustun M, Risberg B, Davidson B, Berner A. Cystic change in metastatic lymph node. *Diagn Cytopathol*; 2002; 27(6): 387-393
12. Goldenberg D, Sciubba J, Koch WM. Cystic metastasis from head and neck squamous cell carcinoma: a distinct disease variant? *Head Neck*, 2006; 28(7):633-638.
13. Klop WM, Balm AJ, Keus RB, Hilgers FJ, Tan IB. Diagnosis and treatment of 39 patients with cervical lymph node metastasis of squamous cell carcinoma with an unknown primary, referred to the Netherlands Cancer Institute/Antoni van Leeuwenhoek hospital in the period 1979-98. *Nederlands Tijdschrift voor Geneeskunde*. 2000;144(28):1355-1360
14. Grau C, Johansen L, Jakobsen J, Geertseen EA, Jensen BB. Cervical lymph node metastasis from unknown primary tumors: Results from a national survey by the Danish Society for Head and Neck Oncology. *Radiother Oncol* 2000; 55(2):121-129
15. Erkal HS, Mandenhall W, Amdur RJ, Villaret DB, Stringer SP. Squamous cell carcinoma metastasis to cervical lymph nodes from an unknown head-and-neck mucosal site treated with radiation therapy alone or in combination with neck dissection. *Int J Radiation Oncol Biol Physics* 2001; 50:55-63
16. Strojjan P, Anicin A. Combined surgery and post-operative radiotherapy for cervical lymph node metastasis from unknown primary tumor. *Radiother Oncol* 1998; 49(1):33-40
17. Sinnathamby K, Peters LJ, Laidlaw C, Hughes PG. The occult head and neck primary: To treat or not to treat? *Clin Oncol* 1997; 9(5):322-329.
18. Million RR, Cassisi NJ, Mancuso AA. The unknown primary. In management of head and neck cancer: A multidisciplinary approach. 2<sup>nd</sup> Edition, Philadelphia, Lippincott, 1994.
19. Lee NK, Byers RM, Abbruzzese JL, Wolf P.

- Metastatic adenocarcinoma to the neck from an unknown primary source. *Am J Surg* 1991; 162(4): 306-309.
20. Zuur CL, Van Velthuysen MLF, Schornagel JH, Hilgers FJM, Balm AJM. Diagnosis and treatment of isolated neck metastasis of adenocarcinomas. *Eur J Surg Oncol* 2002; 28(2):147-152.
  21. Balm AJ, Kroon BB, Hilgers FJ, Jonk A, Mooi WJ. Lymph node metastasis in the neck and parotid gland from an unknown primary melanoma. *Clin Otolaryngol Appl Sci* 1994; 19(2): 161-165.
  22. Greenlee RT, Murray T, Bolden S, Wingo PA. Cancer statistics. *CA Cancer J Clin* 2000; 50:7-33
  23. Azlan II, Moh'd Razif MY, Mazita A, Primuharsa P. Role of panendoscopy and biopsy in cervical lymph node metastasis with unknown primary: a tertiary center experience. *Rawal Med J* 2010; 35(2):209-213
  24. Didolker MS, Fanous N, Elias EG, Moore RH. Metastatic carcinomas from occult primary tumors. A study of 254 patients. *Ann Surg* 1977; 186:625-630
  25. Koivunen P, Laranne J, Virtaniemi J. Cervical metastasis of unknown origin: a series of 72 patients. *Acta Otolaryngol* 2002; 122(5): 569-574
  26. Mendenhall WM, Mancuso AA, Parsons JT, Stringers SP, Cassisi NJ. Diagnostic evaluation of squamous cell carcinoma metastasis to cervical lymph nodes from an unknown head and neck primary site. *Head Neck*.1998; 20(8):735-744.
  27. Ellis ER, Mendenhall WM, Rao PV et al. Incisional and excisional neck node biopsy before definitive radiotherapy, alone or followed by neck dissection. *Head Neck* 1991; 13(3):177-183.
  28. Acquarelli M, Matsunaga R, Cruz K. Metastatic carcinoma of the neck of unknown primary origin. *Laryngoscope* 1961; 71:962-974
  29. Coker D, Casterline P, Chambers RG, Jacques DA. Metastases to the lymph nodes of the head and neck from an unknown primary site. *Am J Surg* 1977; 134:517-522.
  30. Safa A, Tran LM, Rege S, Brown CV, Mandelkernma, Wang MB et al. The role of positron emission tomography in occult primary head and neck cancers. *Cancer J Sci Ann*.1999;5: 205-207
  31. Jungehulsing M, Schneidhauer K, Damm M, Pietrzyk U, Eckel H, Schieha H, et al. 2(18F)-fluoro-2-deoxy-D-glucose positron emission tomography is a sensitive tool for detection of occult primary cancer (cancer of unknown syndrome) with head and neck lymph node manifestation. *Otolaryngol Head Neck Surg* 2000; 123:294-301.