

VESICOVAGINAL FISTULA FOLLOWING AN INDUCED ABORTION WITH A HUGE BLADDER STONE: CASE REPORT.

Ngwan SD*, Obekpa AS*, Eke BA**, Oguiche EI**.

*Department of Obstetrics and Gynaecology, Federal Medical Centre, Makurdi.

** Department of surgery, Benue State University Teaching Hospital, Makurdi.

ABSTRACT

A case of a 26 year old P_1^{+1} woman who developed vesico-vaginal fistula (VVF) following an induced abortion is presented.

She presented with five year history of continuous leakage of urine following a voluntary termination of pregnancy at about 11 weeks of gestation using metallic instruments in a chemist shop by a Nurse.

When she was examined, she had a suprapubic mass of about 14 weeks size, tender and mobile. Pelvic examination revealed a 1.5 x 2.0cm juxta cervical fistula with healthy looking cervix. Abdominopelvic ultrasound scan showed a huge bladder stone that measured 10 x 15cm. She had cystolithotomy and fistula repair transvaginally and was discharged home after 21 days of admission.

Key Words: Vesico-vaginal fistula, induced abortion, bladder stone.

INTRODUCTION

Vesico-vaginal fistula is a very serious cause of morbidity among women in developing countries, especially the Hausa and Fulani in northern Nigeria, Igbo women from southeastern part of Nigeria with obstructed labour accounting for about 80-95% of the causes^{1,2}. Other common causes of Vesico-vaginal fistula in developing countries include destructive operations such as craniotomy, forcep delivery, ruptured uterus, procedures like caesarean section and hysterectomy, cancer of the cervix^{1,2,3,4}. Coital laceration has been reported as a rare cause of VVF⁵.

Induced unsafe abortion is a rare cause of VVF as most complications of this procedure includes uterine perforation, haemorrhage and sepsis. The rarity of this cause of VVF occasioned this report and also its association with a huge bladder stone.

CASE REPORT

A 26 years old Igbo woman presented at Holy Trinity Private Specialist Hospital Makurdi with 5 years history of leakage of urine following an induced abortion carried out by a nurse in his chemist shop. She noticed she had started leaking urine 6 hours after the procedure 5 years ago, and never sort for medical advise. She got pregnant a year after the leakage and was delivered by elective caesarean section at Federal Medical Centre,

Makurdi but the VVF was not repaired. There was associated lower abdominal pain of 2 years duration which became severe necessitating her presentation.

Physical examination revealed a depressed young woman who was afebrile, not pale and anicteric. Abdominal examination revealed a pfannenstiel scar with a suprapubic mass of about 14 weeks size which was tender but mobile. We could get above it but not below it. Vaginal examination revealed vulva excoriations, juxta cervical fistula that measures 1.5 x 2.0cm, excessive scar tissue and healthy looking cervix.

She was admitted and investigated. Her packed cell volume was 33%, full blood count and urine microscopy, culture and sensitivity were essentially normal. Abdominopelvic ultrasound scan revealed a huge bladder stone that measures 10 x 15cm. The uterus was empty and normal in size.

She had cystolithotomy and transvaginal repair of the fistula. Intra operative findings were a huge bladder stone that measures 10 x 15cm, clean bladder mucosa, fistula defect of about 1.5 x 2.0cm with an estimated blood loss of 250mls.

An indwelling catheter was passed. She was placed on antibiotics, ascorbic acid and analgesics. She did

well and was discharged home after 21 days. Chemical pathological analysis of the stones showed phosphate and calcium deposits at follow-up clinic.

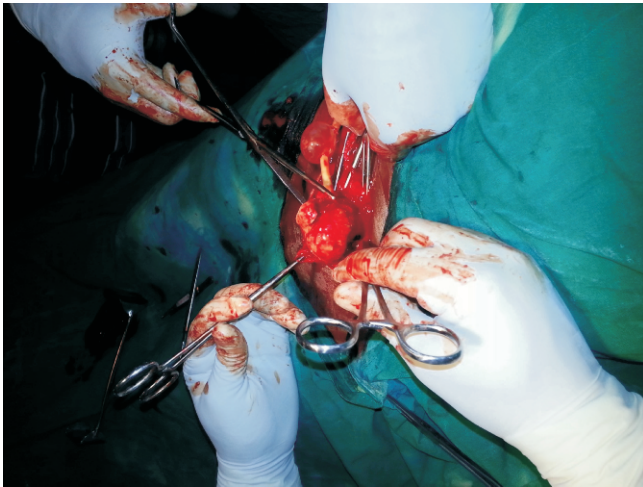


Figure 1: Bladder stone, intra operative

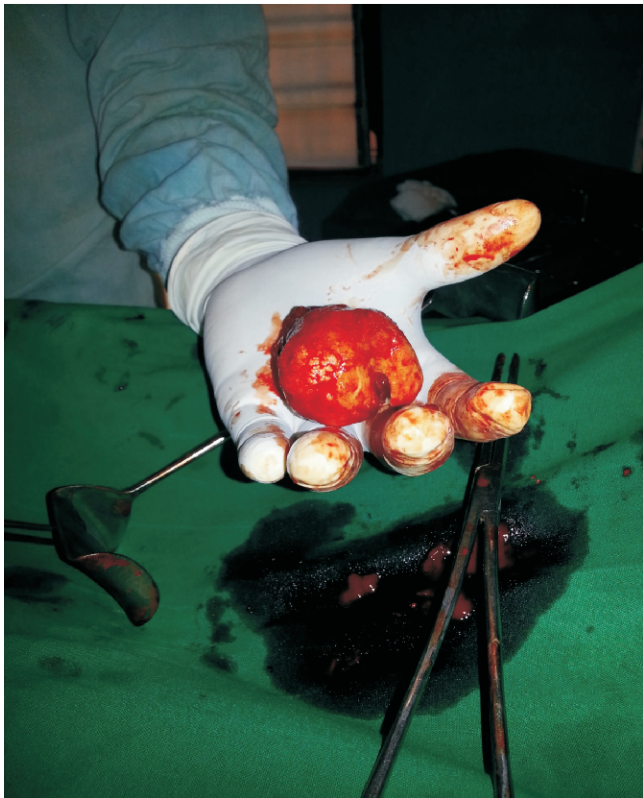

Figure 2: Bladder stone, post op

DISCUSSION

Pressure necrosis following prolonged obstructed labour is the major cause of VVF in Nigeria^{4,5}. VVF caused by induced abortion is rare. Injuries caused by induced procedures for terminating unwanted pregnancies surgically are mostly restricted to the uterus and cervix^{4,6}, but when they are performed by unskilled persons, injury may involve other structures like the bladder as occurs in this woman.

Most VVF are cured through surgical repair^{5,6} as was the case in this woman but some challenges may occur where there are associated complications with the fistula. This woman came with a huge bladder stone in association with the fistula. This complication can occur pre or post operatively and is caused by urinary sepsis due to outflow obstruction or due to decreased fluid intake, decreased urine output and concentrated urine. She had transabdominal, extraperitoneal, transvesical removal of the calculi because of its size which was difficult to remove through the small sized fistula of about 2cm. The fistula was repaired vaginally because it was small and easily accessible. Where the fistula is large, the calculi may be removed through the fistula opening as done in most instances.

Conservative management using indwelling urethral catheter is often recommended as a preliminary measure in VVF due to prolonged obstructed labour before surgical approach and in some cases spontaneous closure do occur⁷. This procedure was successful in an 11 year old girl that developed VVF following sexual assault^{4,7}.

REFERENCES;

1. Tahzib F. Epidemiology determinants of vesico vaginal fistula. *Br J obstet gynaecol*, 1983, 90:387 391.
2. Ibrahim T., Sadiq A. U., and Daniel S. O. Characteristics of VVF patients as seen in Specialist Hospital Sokoto, Nigeria. *West Afr J med*, 2000; 19:59 63.
3. K. A. Danso. Genital tract fistulas. In *Comprehensive Gynaecology in the Tropics* by E. Y. Kwawukume, E. E. Emuveyan (eds), Graphic packaging ltd, Accra. 2005: 19; 174 181.
4. Emmanuel I. Nwobodo. Vesico vaginal fistula following sexual assault: Case report. *Tropical J obstet Gynaecol*, 21 (2) oct. 2004; 186.
5. Victor E., Akintoye O. And Timothy A. Uretero cervical fistula following caesarean section. *Trop. J Obstet Gynaecol*, 21 (2) Oct. 2004; 183 185
6. Wadhawan S. and Wacha D. S. A review of urinary fistula in a University Teaching Hospital. *Int. J. Obs. Gynae*. 1983; 21: 381 385.
7. National Population Commission: Nigerian Demographic and Health Survey, 2003 and National Population Commission. Abuja 2004.