

HISTOLOGICAL TYPES OF CERVICAL MALIGNANCIES SEEN AT THE JOS UNIVERSITY TEACHING HOSPITAL: A FIVE YEAR RESTROSPECTIVE REVIEW

Cinjel P. Stephen^{1*}, Ajang F. Magaji¹, Kwaghe V. Barka², Da'ap I. Panan¹, Joel Kaura³

¹Department of Obstetrics and Gynaecology, Jos University Teaching Hospital, Jos, Plateau state, Nigeria

²Department of Histopathology, Jos University Teaching Hospital, Jos, Plateau state, Nigeria

³Department of Chemical Pathology, Obafemi Awolowo University Teaching Hospital, Ile-Ife, Osun state, Nigeria

ABSTRACT

Background

Cancer of the cervix is the most common gynaecologic malignancy and the fourth most frequent cancer in women worldwide.

Objectives

To determine the pattern and histological types of cervical cancer in Jos University Teaching Hospital (JUTH).

Material and Methods: This is a 5-year retrospective (January 2016 To December, 2020) study of all cervical cancers diagnosed at the Anatomical Pathology Department of JUTH.

Results: Within the 5 years' period (January 2016 To December, 2020), a total of 120 cases of cervical cancers were recorded in JUTH. Of these, Squamous cell carcinoma predominated with 95 (79%) of the cases, adenocarcinoma 14 (12%) cases, and adenosquamous 11 (9%) cases. Patients' ages ranged from 20 to 90 years with highest occurrence in the 4th and 7th decades, with a mean of 53.5 ± 10.1 years.

Conclusion: Squamous cell carcinoma is the commonest gynaecological malignancy distantly followed by adenocarcinoma in our study. This is consistent with most studies in Nigeria and Africa but less common in the developed world and afflicts more of the older age group.

Keywords: cervix, cancer, squamous cell carcinoma, histology, pattern, adenocarcinoma

INTRODUCTION

Cancer of the cervix is the most common gynaecologic malignancy and the fourth most frequent cancer in women worldwide.¹ Most of these cancers stem from infection with the human papillomavirus (HPV), although, other host factors affect neoplastic progression following initial infection.² HPV is the primary etiologic infectious agent associated with cervical cancer although other sexually transmitted factors, including herpes simplex virus², may play a concurrent causative role.^{1,2,4} Ninety-nine point seven percent of cervical cancers are associated with an oncogenic HPV

subtype.^{1,2} In one study, 57 percent of invasive cervical cancer cases were attributable to HPV serotype 16. Serotype 18 was associated with 16 percent of invasive disease cases.^{5,6} Each of these serotypes can lead to either squamous cell carcinoma or adenocarcinoma of the cervix.^{5,6} However, HPV 16 is more commonly associated with squamous cell carcinoma of the cervix, whereas HPV 18 is a risk factor for cervical adenocarcinoma. Lower educational attainment, older age, having multiple sexual partners, immunosuppression, long-term use of combined oral contraceptives, high parity, smoking, and

poverty are risk factors cervical cancer.^{1,3,4,5} Specifically, those living in impoverished neighborhoods have limited access to testing and may benefit from screening outreach programs.¹¹

Immunosuppressed women have an increased risk of developing cervical cancer. Cervical cancer is an acquired immune deficiency syndrome (AIDS)-defining illness.^{1,2} Women with autoimmune disease who use immunosuppressants do not appear to have an increased cervical cancer risk, except for azathioprine users.^{1,2,3,4} In general, progression from dysplastic to invasive cancer requires several years, although, duration can vary widely.^{1,2}

Amplification of viral replication and subsequent transformation of normal cells into tumor cells may follow infection with oncogenic HPV strains.¹ Specifically, the viral gene product E6 and E7 oncoproteins are implicated in this transformation.^{1,2} E7 protein binds to the retinoblastoma (RB) tumor suppressor protein, whereas E6 binds to the p53 tumor suppressor protein.^{1,2} In both instances, binding leads to degradation of this suppressor protein.¹ The E6 effect of p53 degradation is well studied and linked with the proliferation and immortalization of cervical cancer cells.¹ It is observed that HPV infections occurs mostly in sexually active women with 90% clearing spontaneously within months.^{2,7} Infected cells in the cervix could progress into premalignant lesions known as 'cervical intraepithelial neoplasm (CIN) graded as CIN1, CIN2 and CIN3, eventually carcinoma in-situ and invasive cervical cancer via a multistep process.^{2,7}

The two most common histologic subtypes of cervical cancer are squamous cell and adenocarcinoma.^{1,2,3} Of these, squamous cell tumors predominate, comprising about 70 percent of all cervical cancers, and arise from the ectocervix.¹ Over the past 30 years, the incidence of squamous cell cancers has declined, whereas that of cervical adenocarcinoma has risen.^{1,2,3} These changes may be attributed to an improved method of screening for early squamous lesions of the cervix and an

increase in HPV prevalence.¹ Squamous cell carcinomas can be subdivided into keratinizing and non-keratinizing carcinomas.^{1,2,3,4}

In contrast to squamous cell cervical carcinoma, adenocarcinomas make up 25 percent of cervical cancers and arise from the endocervical mucus-producing columnar cells.^{1,2} Because of its origin within the endocervix, adenocarcinomas are often occult and may be advanced before becoming clinically evident. They often give the cervix a palpable barrel shape during pelvic examination.^{1,2,3,4}

Adenocarcinomas exhibit various histologic patterns composed of diverse cell types.^{1,2} Of these, mucinous adenocarcinomas are the most common.^{1,2} The mucinous endocervical type retains resemblance to normal endocervical tissue.^{1,2,3} The intestinal type resembles intestinal cells and may include goblet cells.^{1,2,3} Minimal deviation adenocarcinoma, also known as adenoma malignum, is characterized by cytologically bland glands that are abnormal in size and shape.^{1,2} These tumors contain an increased number of glands positioned at a deeper level than normal endocervical glands.^{1,2} Women with Peutz-Jeghers syndrome are at increased risk of developing adenoma malignum. Villoglandular adenocarcinomas are made up of surface papillae.^{1,2,3}

Endometrioid adenocarcinomas are the second most frequently identified and display glands resembling those of the endometrium. Serous carcinoma is identical to serous carcinomas of the ovaries or uterus and is rare.^{1,2} Clear cell adenocarcinoma accounts for less than 5 percent of cervical adenocarcinomas and is named for its clear cytoplasm. Rarely, adenocarcinomas arise in mesonephric remnants in the cervix and are termed mesonephric adenocarcinoma.^{1,2,3,4,5}

Jos University Teaching Hospital (JUTH), Plateau State is one of the tertiary Health Centers offering histopathology services in the state with an estimated population of 3.5 million people. This study examines the pattern and histological types of

cervical cancers in JUTH and compares it with other parts of the country and the world in general.

METHODOLOGY

Study design:

This was a retrospective review of histopathology report of cervical specimen obtained at surgery during the study period.

Study Population:

Women who had cervical cancers within the last five years as confirmed by the histopathology department of the Jos University Teaching Hospital.

Sample Size:

This is a retrospective review of 120 histologically confirmed cases of cervical malignancies diagnosed at the department of histopathology JUTH.

Department of study:

Histopathology department of the Jos University Teaching Hospital.

Ethical Consideration:

Permission for the study was obtained from the Ethical and Research committee of the Jos University Teaching Hospital and Histopathological Department of the same institution

Sample Collection:

Data was obtained for this study using records of results of patients in the department of histopathology of JUTH over the last five years.

Data Analysis:

Data was analyzed descriptively using EPI info. Descriptive analysis using the simple bar chart, frequency distribution.

RESULTS

Within the 5 years' study period (January 2016 To December, 2020), a total of 120 cases of cervical cancers were recorded in JUTH. Of these, Squamous cell carcinoma predominated with 95 (79%) cases, adenocarcinoma 14 (12%) cases, and adenosquamous 11 (9%) cases.

Patients age ranged from 20 to 90 years with highest occurrence in the 4th and 7th decades with mean of 53.5 ± 10 years.

Table 1 showing the age distribution of cervical cancer in JUTH from January, 2016 to December, 2020.

Age group (years)	Frequency (N = 120)	Percentage %
21 – 30	2	2
31 – 40	21	17
41 – 50	28	23
51 – 60	31	26
61 – 70	25	21
71 – 80	12	10
81 – 90	1	1
Mean age	53.5 ± 10	100

Table 2: Showing the pattern of cervical cancer in JUTH from January 2016 to December, 2020.

Histologic type	Frequency (N = 120)	Percentage %
SCC	95	79
Adenocarcinoma	14	12
Adenosquamous	11	9
	120	100

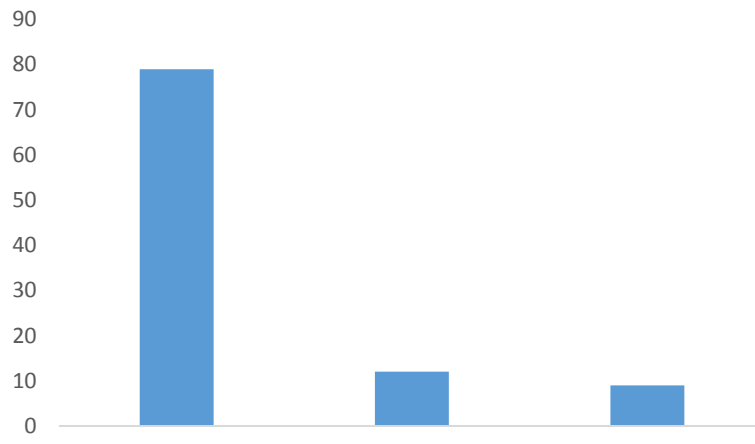


Figure 1: Bar Chart Showing Pattern of Cervical Cancer in JUTH

DISCUSSION

A total of 120 cases of cervical cancer were encountered over a 5-year period. This gave an average of 24 cases per year and similar findings were documented in BSUTH with 25.6 per year.³

The mean age of the women in this study was 53.5 ± 10.1 years which corroborated with other Nigerian studies (Table 1), 44.5 years in Maiduguri, 42 years in Ibadan, 48 years in Sokoto, 49.5 years in Abuja, and 47.5 in BSUTH. Findings in other parts of the world were as shown, 49 years in Ethiopia, 50 years in England, and 51.4 years in the USA.^{1,2,3,7,10,12} In this series, squamous cell carcinoma was by far the most common histological variant (Table 2) accounting for 79% (95 cases). Similar figures were documented in previous studies done in BSUTH 79%, UDUTH 80%, Lagos 92%, Port-Harcourt 90.2%, Nnewi 92.3%, and Benin 89.3%. Squamous cell carcinoma is also higher in Gabon 90% and England 70%.^{7,10,12} Generally, the incidence of squamous cell cancers has declined, whereas that of cervical adenocarcinoma has risen.

These changes may be attributed to an improved method of screening for early squamous lesions of the cervix and an increase in HPV prevalence.¹ Adenocarcinoma was the second most common histological variant in this study accounting for 12% of cervical cancers in JUTH. This is relatively small but consistent with the study done in BSUTH where cervical adenocarcinoma account for 10% of cervical cancers and slightly higher than the 6% previous study in Benin City.^{1,3,9}

Generally, other histological variants of cervical cancers seen in contrast to squamous cell cervical carcinoma, adenocarcinomas generally make up 25 percent of cervical cancers and arise from the endocervical mucus-producing columnar cells. Because of this origin within the endocervix, adenocarcinomas are often occult and may be advanced before becoming clinically evident.^{1,2} In this study, adenosquamous carcinoma constituted 9% of cervical cancer.

The study shows that 66% of cervical cancers occurs between the 3rd and 5th

decade which represent the most sexually active group and is consistent with findings in other parts of the country where most patients fell within the 40-69 years age bracket.

In conclusion, squamous cell carcinoma constitutes the highest histologic type of cervical cancer accounting for 79% of cervical cancers. 66% of these cancers occurs between the 3rd and 5th decades.

REFERENCE

1. Barbara L. Hoffman, John O. Schorge, Karen D. Bradshaw, Lisa M. Halvorson, Joseph I. Schaffer, Marlene M. Corton. Williams Gynaecology. 4th edition. Mc Graw Hill Education. 2020;30:657-675.
2. Alan H. DeCherney, Neri Laufer, Lauren Nathan, Ashley S. Roman. Current diagnosis and treatment: Obstetrics and Gynecology. 12th edition. McGraw-Hill Education. 2019;50:837-860
3. Joseph A. Ngbea, T.Z. Swende, R.A. Vhritherhire, M.N. Agwa, O.I. Akpor, T. Nyaga, et al. Histopathological Patterns of Cervical Cancer in Makurdi, North Central Nigeria. IJISMS.2019;3(5):1-3
4. Kwawukume EY, Emuveyan EE, Comprehensive Gynaecology in the Tropics, 2nd edition. Hittscher Publishing, 2017;44:565-434.
5. Cameron S, Glasier A. In: Dewhurst's Textbook of Obstetrics and Gynecology, 9th edition. Wiley-Blackwell. 2018; 61:859-871.
6. Agboola A. Textbook of Obstetrics and Gynaecology for medical students Vol 2, 2006;21:167-181.
7. Sule AA, Ochicha O. A histopathologic review of cervical cancer in kano, Nigeria. Sahel med j. 2017;20(1):16-20.
8. Franceschi S, Rajkumar T, Vaccarella S, Gajalakshmi V, Sharmila A, Snijders PJF, et al. human papillomavirus and risk factors for cervical cancer in Chennai, India: A case study. Int J Cancer. 2003;107:127-13.
9. Ibeanu OA. Molecular pathogenesis of cervical cancer. Cancer biology, and therapy. 2011;11(3):295-306.
10. Irabor GI, Omotoso AJ, Isiwele EM, Nnoli MA, Omoruyi KA. Histopathological study of cervical cancer specimen at the University of Calabar Teaching Hospital, Calabar. Med Res Chron. 2017;4(5):582-590.
11. Ijaila MA, Aboyeji AP, Olatinwo AW, Buhari MO. Clinicopathological presentation of primary cervical cancer seen in Ilorin, Nigeria. Niger J Surg Res. 2002;4:89-93.
12. Nwosu SO, Anya SE. Malignancies of the female genital tract at the University of Port Harcourt Teaching Hospital: A ten-year review-1990-1999. Niger Postgrad Med J. 2004; 11:107-9.