

## Monkeypox Outbreak, Harper District, Maryland County, Liberia, December 2017

Doebia Gweh<sup>1, &</sup>, Peter Adewuyi<sup>2</sup>, Maame Amo-Addae<sup>2</sup>, Lilian Bulage<sup>3</sup>, Himiede Wede Wilson<sup>2</sup>, Fulton Shannon IP<sup>2</sup>, Olayinka Stephen Ilesanmi<sup>2</sup>, Thomas Knue Nagbe<sup>2</sup>, Obafemi Joseph Babalola<sup>2</sup>

<sup>1</sup>Maryland County Health Team Harper City, Ministry of Health, Congo Town, Monrovia, Liberia, <sup>2</sup>Liberia Field Epidemiology Training Program, Monrovia, Liberia, <sup>3</sup>African Field Epidemiology Network, Kampala, Uganda

### ABSTRACT

**Introduction:** Monkeypox is a viral zoonotic disease caused by orthopoxvirus. In Liberia, one confirmed case of monkeypox constitutes an outbreak. A District Surveillance Officer (DSO) of Harper District, Maryland County reported a suspected case of monkeypox on December 5, 2017. We investigated to verify the diagnosis, identify the source of the disease, assess the magnitude of the outbreak, and implement evidence-based control measures. **Methods:** We interviewed family and community members, and health workers to identify additional cases and contacts, and to obtain information on the source of the illness. We collected samples (whole blood and lesion swabs) for confirmation of the disease. We monitored the contacts for 21 days for signs and symptoms of monkeypox signs. We also conducted environmental assessment on source of the infection. **Results:** We identified one confirmed case of monkeypox in a 5-year old male from Tenken Community Maryland County in Liberia, who tested positive for West African strain of monkeypox virus. The case-patient had no history of direct contact with wild animals nor consumption of bush, and no travel history or contact with a sick person. The patient was isolated and recovered after three weeks of treatment on analgesics and antibiotics. We identified 35 contacts, none of whom developed signs and symptoms during 21 days of follow up. **Conclusion:** This was a confirmed monkeypox outbreak in Maryland County. Laboratory confirmation was delayed, and the source of infection remained unknown.

**KEYWORDS:** Monkeypox, Orthopox virus, Zoonotic disease. Lymphadenopathy, Re-emerging disease

### <sup>&</sup>CORRESPONDING AUTHOR

Dedesco Doebia Gweh, Maryland County Health Team Harper City, Ministry of Health, Congo Town, Monrovia, Liberia.  
dedesco1212@yahoo.com

### RECEIVED

10/12/20219

### ACCEPTED

24/11/2020

### PUBLISHED

29/01/2021

### LINK

[www.afenet-journal.net/content/article/series/4/1/5/full/](http://www.afenet-journal.net/content/article/series/4/1/5/full/)

© Dedesco Doebia Gweh et al. Journal of Interventional Epidemiology and Public Health [Internet]. This is an Open Access article distributed under the terms of the Creative Commons Attribution International 4.0 License (<https://creativecommons.org/licenses/by/4.0/>), which permits unrestricted use, distribution, and reproduction in any medium, provided the original work is properly cited.

### CITATION

Dedesco Doebia Gweh et al. Monkeypox Outbreak, Harper District, Maryland County, Liberia, December 2017. J Interv Epidemiol Public Health. 2021 January; Suppl 1: 5

### DOI:

<https://doi.org/10.37432/jieph.supp.2021.4.1.01.5>

## Introduction

---

Monkeypox is a viral zoonotic disease caused by an orthopoxvirus [1]. The monkeypox virus causes a disease that is similar to smallpox, but has a milder rash and lower death rate [2, 3]. The virus was first identified in Copenhagen, Denmark in 1958 in crab-eating macaque monkeys (*Macaca fascicularis*), where the monkeys were used as laboratory experimental animals. The monkeypox virus was also seen in the giant Gambian rat as the source of the 2003 outbreak in the United States [4].

The disease can spread from animal to human and from human to human as well. Infections from animal to human are through the bite of an infected animal or through direct contact with an infected animal's body fluids. Secondary spread through human-to-human transmission is limited [5]. The incubation period of monkeypox, ranges from 5 to 21 days [6]. Signs and symptoms include lymphadenopathy (swelling of lymph nodes), muscle pain, headache, fever, chills, and skin lesions on face, legs, and the genitals [7]. The case fatality rate in monkeypox outbreaks has been between 1% and 10% but most deaths occur in the younger age-group [8].

Risk factors for monkeypox transmission include hunting and playing with wild monkeys, rodents, and other wild animals. Persons bitten by infected animals are at high risk of acquiring the disease [9].

Cases have been reported from North and South America, Asia and Africa. Democratic Republic of Congo has reported the highest cases in Africa [10]. In Liberia the last confirmed case of monkeypox before 2017 was reported in the 1970s in Grand Gedeh County [11, 12]. The Liberia Integrated Disease Surveillance and Response (IDSR) technical guidelines require a single case of suspected monkeypox, to be investigated as any other infectious diseases of epidemic potential [13]. A single confirmed case constitutes an outbreak.

On December 5, 2017, the District Surveillance Officer (DSO) of Harper District, Maryland County reported a suspected case of monkeypox, to the Maryland County Health Team.

The Maryland County Health Team activated the rapid response team to investigate the report. Investigation commenced on December 6, 2018. We investigated to verify the diagnosis, to identify the source of the disease, to assess the magnitude of the outbreak, and to implement evidence-based control and prevention measures.

## Methods

---

**Study setting:** The outbreak occurred in Tenken community, Barrobo Farjah District, located in northern part of Maryland County, Liberia [Figure 1](#). Barrobo Farjah District had an estimated population of 13,742 that is served by two clinics Tenken community, with 500 inhabitants is a hard-to-reach community requiring 3-4 hours walk to access the health facilities. The community is surrounded by a dense forest and bush meat is widely eaten by the inhabitants. Rodents from the forest commonly enter the homes of inhabitants in the community and even eat their foods or drink from their due to their utensils. Some of these rodents even live and breed in holes in their homes.

**Case and contact definition and case finding:** We defined a suspected case of monkeypox as anyone from Barrobo Farjah District who presented with fever and skin lesions with any three of the following: headache, muscle aches, backache, swollen lymph nodes, chills, exhaustion, from November 26 to December 30, 2017. We defined a probable case of monkeypox as a suspected case who had contact with a confirmed case, i.e., ate together, or slept in the same room or cared for confirmed case without the required infection control measures prior to developing the signs and symptoms. A confirmed case of monkeypox was defined as a suspected or probable case in whom monkeypox was confirmed by the laboratory through a real-time quantitative polymerase chain reaction (PCR) assay.

To obtain further information on the suspected case and identify additional suspected cases, we reviewed medical records at the health facilities where the patient had been managed, and conducted active case search in the affected community using the US CDC's monkeypox specific case investigation guidelines [14]. We obtained the medical history on the suspected case including signs and symptoms,

date of symptom onset, and duration of illness from the medical records. We also interviewed the patient's mother and close relatives to obtain additional information on the case-patient, including socio-demographics, travel history and contacts. We conducted face-to-face interviews with community leadership to obtain more information about the case-patient and the contacts using the US CDC monkeypox-specific guidelines. We defined contacts as any person who had slept in the same space, or bathed in same bucket or bathroom, or ate from the same utensil with the confirmed case, or cared for the confirmed case without observing the recommended infection prevention and control practices (IPC). We line-listed contacts, monitored and followed up for 21 days using the IDSR standard contact tracing forms. We assessed for risk factors by asking family and community members about exposure to animal bites, the presence of rodents in homes, eating of wild animals and caring for confirmed monkeypox case.

**Laboratory investigations:** We collected the required three samples (whole blood, skin snip, and wound swab) from the suspected case into EDTA red and purple test tubes with photo of the lesion on December 6, 2017, ten days after onset of the illness. Liberia lacks capacity for laboratory confirmation of monkeypox so the samples were triple-packaged, labelled and shipped to the US Centers for Disease Control and Prevention for confirmation through RT-PCR assays critical for laboratory diagnosis of monkeypox.

#### **Availability of data and material**

The data on which this write up is based belong to the Ministry of Health Liberia and are not publicly available. However, the data could be obtained from the corresponding author with permission from the Ministry of Health, Liberia.

#### **Ethics approval and consent to participate**

The National Public Health Institute of Liberia (NPHIL) and the Ministry of Health (MOH), Liberia gave clearance to County and District Surveillance Officers for the investigation of public health emergencies and events within twenty-four hours of notification. In addition, community members, contacts, and patient's family members were educated and informed about the investigation

and verbal consents were granted for the investigation.

---

## **Results**

### **Case description**

The case had been referred from Gbawiliken clinic in Barrobo Farjah District to JJ Dossen Hospital, Harper District, the referral hospital for Maryland County. The case had presented at Gbawiliken Clinic with fever, headache, muscle aches, backache, lymphadenopathy/swollen lymph nodes, chills, exhaustion, and papular skin lesions on the face and the genitals. The case had been managed at the Gbawiliken Clinic as chicken pox for nine days but was referred to JJ Dossen Hospital in Harper District when he was not responding to routine treatment for chicken pox; paracetamol, calamine and cooling gel to relieve the pain and ease the itching. At the affected community, family, and some community members suspected witchcraft as cause of the infection.

On December 5, 2017, the 5-year old male, accompanied by his mother, presented at JJ Dossen Hospital with a 9-day history of fever, extensive generalized papular rash, headache, malaise, and sore throat. Physical examination revealed generalized well-circumscribed papulopustular rashes on the trunk, face, palms, and soles of the feet, with subsequent umbilication ulcerations, crusting, and scab formation. The case-patient had associated oral and nasal mucosal lesions and ulcers and accompanying generalized lymphadenopathy. The clinical team and the District Surveillance Officer suspected monkeypox and the patient was immediately admitted to the isolation ward where the samples were taken for laboratory confirmation and treatment was commenced. Management at the isolation ward involved strictly abiding to the IPC guidelines. Thirty days after sample collection and 40 days after the onset of symptoms, laboratory results were received, which indicated that the case-patient had tested positive for the West African strain of monkeypox virus on RT-PCR.

The case-patient was an inhabitant of Tenken community in Barrobo Farjah District, Maryland County. He had no travel history nor contact with

wild animals or with a sick person, neither did he eat bush meat prior to the onset of disease. We identified, line-listed, and followed-up 35 contacts, 54.3% (19/35) of whom were females, and 25.7% (9/35) aged below the age of ten years. Of the 35 contacts line-listed, 77% (27/35) were high risk because they were family members who resided in the same house with the patient, play mates, or health workers who had provided medical care for the patient without the necessary IPC requirements. The eight low risk contacts did not have physical contact with the patient. They included community members who had visited and provided verbal psychosocial support to the case's family when the case was still at home. No contact developed signs and symptoms of the disease within 21 days of follow-up.

The case-patient was isolated and treated symptomatically on antiviral drugs, antibiotics to treat secondary infection, antipyretics for the fever, and topical applications to ease the itching. The case-patient recovered after 23 days of treatment and was discharged on December 28, 2017, ahead of the release of the laboratory test results.

## Discussion

Monkeypox was confirmed in a 5-year old male child in Tenken Community, Barrobo Farjah District, Maryland County. The source of infection could not be established, as in a monkeypox outbreak experienced in Cameroon in June, 2018. Monkeypox has re-emerged in Liberia forty years after the last confirmed case in the 1970s in Grand Gedeh County, as noted in a phylogeographic investigation of African Monkeypox [15].

The outbreak was contained through an active surveillance system and proper case management despite a delay in laboratory confirmation. Laboratory confirmation of the outbreak occurred 30 days after sample was collected for testing. The lack of testing facility for monkeypox in Liberia contributed to the delay, as the samples had to be shipped to Atlanta, USA. This calls for investment in the laboratory capacity by the Ministry of Health of Liberia since laboratories are key in attaining the global health security agenda and play a critical role in detection and response to outbreaks.

Although the clinicians at Gbawiliken Clinic who first saw the patient missed the diagnosis, their action of referring the child to a higher-level facility when he was not responding to treatment contributed to the positive outcome.

Similar to outbreaks experienced in the Democratic Republic of the Congo, there was no evidence of human-to-human transmission in the Tenken outbreak [16]. Health care workers at the Gbawiliken Clinic were exposed because of limited knowledge about the disease. However, none of the contacts developed signs and symptoms of monkeypox within 21 days of follow-up as compared to similar investigations conducted in the DRC [8]. Quick outbreak containment and no human-to-human spread may have been the case because the case-patient was infected with the West African strain of monkeypox virus which has been documented to cause milder disease symptoms, fewer deaths, and with limited human-to-human transmission. In addition, the prompt isolation of the patient at the referral hospital may have limited human-to-human transmission. Despite the lack of laboratory confirmation, the health care system put in place all the required measures for control of the suspected outbreak. The measures included the prompt activation of the rapid response team, putting in place all the infection control measures when handling the patient, strengthening surveillance including ensuring hand washing, isolation of patient, contact tracing, health education of the community, community meetings and the symptomatic treatment of patient.

## Limitations

Our investigation did not establish the source of infection. We suspect that the case could have been infected through eating and or handling bush meat, a habitual practice in the community. The case-patient's young age of 5 years may have contributed to inaccuracies in food consumption and contact history. Tenken community is rodent-infested, making contact with rodents likely.

## Conclusion

This was a confirmed monkeypox outbreak in Maryland County, Liberia involving one case, with delayed laboratory confirmation and an unidentified

source of infection. Death was averted and transmission was broken through effective case management and public health actions. Test result came a month after the patient has recovered and been discharged, due to the lack of testing facility for monkeypox in Liberia. No contact developed symptoms of the disease. We recommend strengthening the Liberian laboratory capacity to test for monkeypox and other priority pathogens. We also recommended that the Ministry of Health should sensitize all health workers and the general public in Liberia about the re-emerging disease.

### **What is known about this topic**

---

- That the disease was eradicated since 1970
- That the disease could only affect hunters
- That the disease transmission can only be contained by health workers.

### **What this study adds**

---

- That the disease has re-emerged in Liberia
- That the disease can affect non-hunters
- That health workers at all levels need to be sensitized about monkeypox

### **Competing interests**

---

The authors declare no competing interests.

### **Funding**

This investigation and response was funded by the National Public Health Institute of Liberia and the Ministry of Health, Liberia through the Maryland County Health Team.

### **Authors' contributions**

---

Dedesco Doebia Gweh was lead in the outbreak investigation, response and manuscript writing. Peter Adewuyi, Maame Amo-Addae, led the designing of the protocol, and field data collection as well as the analysis and interpretation. Thomas Knue Nagbe, Himiede Wilson and Ilesanmi assisted with the technical revision of the protocol, training, and field data collection, while Fulton Shannon assisted with the protocol review and analysis. Lilian

Bulage and Obafemi J. Babalola assisted with the technical review/editing of the manuscript for publication. Thomas Knue also provided oversight on the implementation of the study. All authors read and approved the final manuscript, provided technical guidance and mentorships during the response and also reviewed and made correction during the manuscript writing.

### **Acknowledgements**

---

We appreciate the National Public Health Institute of Liberia for the technical and logistical support during the outbreak response, Ministry of Health Liberia for the financial and logistical supports during the outbreak response, US CDC for their laboratory and other technical guidance, and the African Field Epidemiology Network for the financial and technical support during the response to this outbreak and manuscript writing.

### **Figures**

---

**Figure 1:** Map showing location of Barrobo Farjah District, Mary Land County

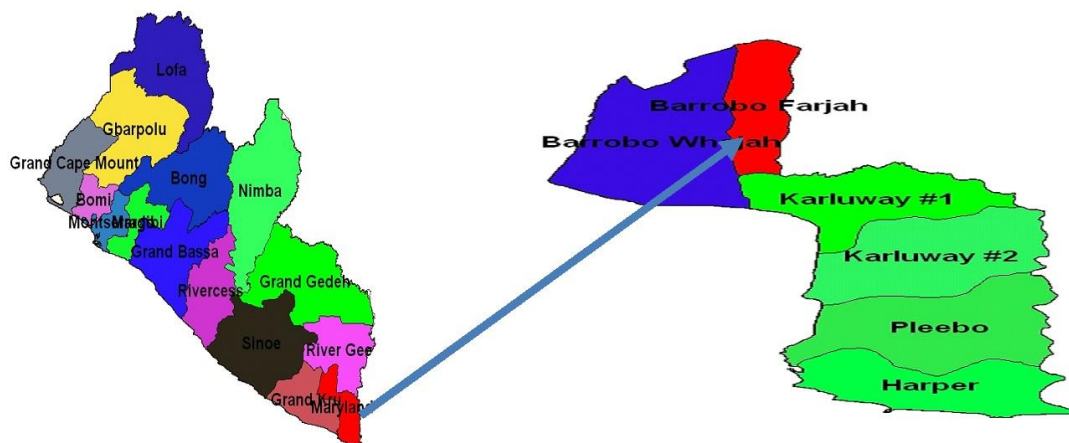
### **References**

---

1. Osadebe L, Hughes CM, Shongo Lushima R, Kabamba J, Nguete B, Malekani J, et al. Enhancing case definitions for surveillance of human monkeypox in the Democratic Republic of Congo. *PLoS Negl Trop Dis*. 2017 Sep; 11(9):e0005857. <https://doi.org/10.1371/journal.pntd.0005857>. [PubMed](#) | [Google Scholar](#)
2. Sklenovská N, Van Ranst M. Emergence of Monkeypox as the Most Important Orthopoxvirus Infection in Humans. *Front Public Health*. 2018; 6:241. <https://doi.org/10.3389/fpubh.2018.00241>. [PubMed](#) | [Google Scholar](#)

3. Russo AT, Grosenbach DW, Brasel TL, Baker RO, Cawthon AG, Reynolds E, et al. Effects of Treatment Delay on Efficacy of Tecovirimat Following Lethal Aerosol Monkeypox Virus Challenge in Cynomolgus Macaques. *J Infect Dis.* 2018 Sep 22;218(9):1490-9. <https://doi.org/10.1093/infdis/jiy326>. [PubMed](#) | [Google Scholar](#)
4. Zehender G, Lai A, Veo C, Bergna A, Ciccozzi M, Galli M. Bayesian reconstruction of the evolutionary history and cross-species transition of variola virus and orthopoxviruses. *J Med Virol.* 2018 Jun;90(6):1134-41. <https://doi.org/10.1002/jmv.25055> [Google Scholar](#)
5. Sale TA, Melski JW, Stratman EJ. Monkeypox: an epidemiologic and clinical comparison of African and US disease. *J Am Acad Dermatol.* 2006 Sep;55(3):478-81. <https://doi.org/10.1016/j.jaad.2006.0061> . [Google Scholar](#)
6. Mucker EM, Wollen-Roberts SE, Kimmel A, Shamblin J, Sampey D, Hooper JW. Intranasal monkeypox marmoset model: Prophylactic antibody treatment provides benefit against severe monkeypox virus disease. *PLoS Negl Trop Dis.* 2018;12(6):e0006581. <https://doi.org/10.1371/journal.pntd.0006581> . [PubMed](#) | [Google Scholar](#)
7. McCollum AM, Damon IK. Human monkeypox. *Clin Infect Dis.* 2014 Jan;58(2):260-7 <https://doi.org/10.1093/cid/cit703> . [PubMed](#) | [Google Scholar](#)
8. Chaudhri G, Kaladimou G, Pandey P, Karupiah G. Propagation and Purification of Ectromelia Virus. *Curr Protoc Microbiol.* 2018 Nov;51(1):e65. <https://doi.org/10.1002/cpmc.65>. [Google Scholar](#)
9. Quiner CA, Moses C, Monroe BP, Nakazawa Y, Doty JB, Hughes CM, et al. Presumptive risk factors for monkeypox in rural communities in the Democratic Republic of the Congo. *PLoS ONE.* 2017;12(2):e0168664. <https://doi.org/10.1371/journal.pone.0168664> . [PubMed](#) | [Google Scholar](#)
10. Hackett DW. [Nigeria Confirms 7 Monkeypox Virus Deaths](#). Precision Vaccinations. 2018. Accessed December 2018.
11. Durski KN, McCollum AM, Nakazawa Y, et al. Emergence of Monkeypox — West and Central Africa, 1970-2017. *MMWR Morb Mortal Wkly Rep.* 2018 Mar; 67(10):306-310. <https://doi.org/10.15585/mmwr.mm6710a5> . [PubMed](#) | [Google Scholar](#)
12. World Health Organisation. [African countries reporting human monkeypox cases, 1970 - 2017](#). WHO. 2018. Accessed September 2018.
13. Pal M, Mengstie F, Kandi V. Epidemiology, Diagnosis, and Control of Monkeypox Disease: A comprehensive Review. *Am J Infect Dis Microbiol.* 2017; 5(2):94-9. <https://dx.doi.org/10.12691/ajidm-5-2-4>. [Google Scholar](#)

14. Earl PL, Americo JL, Cotter CA, Moss B. Comparative live bioluminescence imaging of monkeypox virus dissemination in a wild-derived inbred mouse (*Mus musculus castaneus*) and outbred African dormouse (*Graphiurus kelleni*). *Virology*. 2015 Jan; 475: 150-158. <https://doi.org/10.1016/j.virol.2011.015> . [PubMed](#) | [Google Scholar](#)
15. Reynolds MG, Damon IK. Outbreaks of human monkeypox after cessation of smallpox vaccination. *Trends Microbiol*. 2012 Feb;20 (2):80-7. <https://doi.org/10.1016/j.tim.2011.12.001>. [Google Scholar](#)
16. Doshi RH, Guagliardo SAJ, Doty JB, Babeaux AD, Matheny A, Burgado J, et al. Epidemiologic and ecologic investigations of Monkeypox, Likouala department, Republic of the Congo, 2017. *Emerg Infect Dis*. 2019;25(2):273-81. <https://doi.org/10.3201/eid2502.181222> . [PubMed](#) | [Google Scholar](#)



**Figure 1:** Map showing location of Barrobo Farjah District, Mary Land County