

An unusual coexistence of Addison's disease and phaeochromocytoma

Atmaca H, MD, Professor; Gokosmanoglu F, MD, Fellow; Kan EK, MD, Fellow
Ecemis GC, MD, Fellow; Bahadir CT, MD, Fellow

Department of Endocrinology and Metabolism, Ondokuz Mayıs University Medical School, Samsun, Turkey

Correspondence to: Hulusi Atmaca, e-mail: mhatmaca@gmail.com

Keywords: Addison's disease, phaeochromocytoma, glucocorticoids, chromaffin cells

Peer reviewed. (Submitted: 2013-07-17. Accepted: 2013-08-26.) © SEMDSA

JEMDSA 2013;18(3):164-166

Introduction

The adrenal gland consists of two endocrine tissues of different embryological origin, namely the primarily steroid-producing adrenocortical tissue, and the catecholamine-producing chromaffin cells.¹ Adrenal catecholamines and steroids are important regulators of the stress response, immune function, blood pressure and energy homeostasis.² Chromaffin cells regulate steroid hormone release by the adrenal cortex. Steroids induce catecholamine production in the medulla. Consequently, disorders of the adrenal cortex have been shown to affect chromaffin cell function and vice versa.³

We report on a patient with an unusual combination of Addison's disease and phaeochromocytoma, whose initial presentation was adrenocortical failure. After replacement therapy for adrenocortical failure, a clinical presentation of phaeochromocytoma emerged.

Case study

A 51-year-old man presented with a three-month history of hypotension, weight loss and fatigue. His family history was unremarkable for tuberculosis and

autoimmune diseases. On physical examination, he had hypotension (90/60 mmHg), hyperpigmentation of the palmar creases and generalised brown hyperpigmentation. On laboratory examination, his serum sodium and basal morning cortisol levels were low. Plasma adrenocorticotrophic hormone was high. Plasma renin activity and potassium were at the upper limit of normal. Plasma aldosterone was at the lower limit of normal (Table I).

Peak cortisol response to the intravenous short synacthen test was 116 nmol/l. The chest X-ray was normal, and the purified protein derivative and anti-human immunodeficiency virus (HIV) tests negative following aetiological assessment. Antithyroglobulin (483 IU/ml) and antithyroid peroxidase (165 IU/ml) antibodies were strongly positive. The anti-21-hydroxylase antibody was not available. Both adrenal glands were atrophic on abdominal computed tomography (CT) scan, but a 2-cm homogenous adrenal mass in the right adrenal gland was prominent (Figure 1).

The patient was diagnosed with primary adrenocortical insufficiency, possibly owing to autoimmune adrenalitis. On unenhanced CT, the attenuation value was 40 Hounsfield units. On contrast-enhanced CT, marked contrast enhancement, with a delayed contrast washout (a washout of < 50%) was evident. Magnetic resonance imaging (MRI) showed a 2-cm right adrenal mass with low-signal intensity on T1-weighted images, and a very high-signal intensity on T2-weighted images. There was no change in tumour size after four months, as assessed by MRI. All of the symptoms were relieved following prednisolone and fludrocortisone replacement therapy. Six months later, the patient was readmitted with spells of ill health

Table I: Laboratory tests on presentation

Parameters (normal ranges)	Results	Parameters (normal ranges)	Results
Na (135-145 mmol/l)	130	Free T4 (11.9-21.8 pmol/l)	16.2
K (3.5-5.5 mmol/l)	5.4	ESR (0-20 mm/hour)	14
FBG (3.8-5.5 mmol/l)	5.4	Cortisol (138-690 nmol/l)	146
BUN (1.7-8.5 mmol/l)	11.7	ACTH (2-11.4 pmol/l)	175
Creatinine (35.3-123 µmol/l)	100	Aldosterone (22.1-477 pmol/l)	46
TSH (0.3-4.7 mIU/l)	0.75	PRA (0.5-1.9 ng/ml/hour)	1.76

ACTH: adrenocorticotrophic hormone, BUN: blood urea nitrogen, ESR: erythrocyte sedimentation rate, FBG: fasting blood glucose, K: potassium, Na: sodium, PRA: plasma renin activity, TSH: thyroid-stimulating hormone, T4: thyroxine

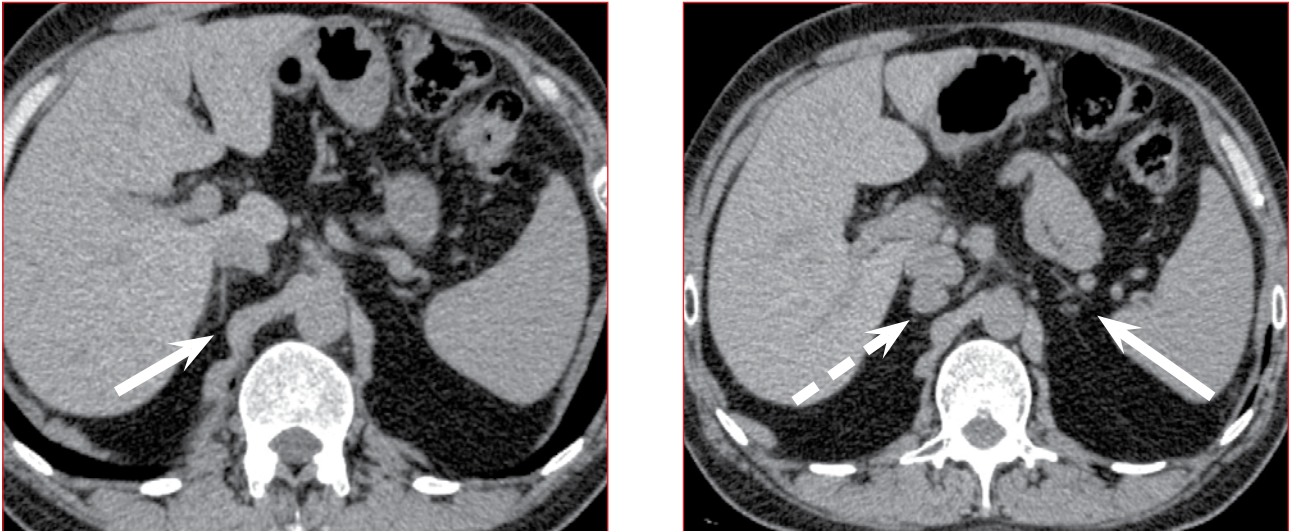


Figure 1: Bilaterally atrophic glands (straight arrows), and a 2-cm adrenal mass in the right adrenal gland (barred arrow)

Table II: Catecholamines and metanephrines in the 24-hour urinary specimen

Parameters (normal ranges)	Before adrenalectomy	After adrenalectomy
Vanillylmandelic acid (0-33 μmol)	16	14
Dopamine (0-3 262 nmol)	835	1187
Adrenalin (0-147 nmol)	79	0.54
Noradrenaline (0-573 nmol)	156	157
Metanephrine (0.38-1.51 μmol)	3.41	0.03
Normetanephrine (0.57-1.93 μmol)	0.60	0.13

that started one month previously. He complained about episodic blood pressure elevations associated with palpitations, dizziness, pallor and sweating. The patient was hospitalised again. During an attack, blood pressure was 220/140 mmHg, and the pulse, 106. The metanephrine in a 24-hour urine sample was significantly elevated (Table II).

A metaiodobenzylguanidine scan demonstrated abnormal isotope accumulation in the tumour region. Doxazosin and propranolol were administered consecutively. Blood pressure and heart rate normalised. After adequate hydration and coverage with stress doses of glucocorticoid, laparoscopic right adrenalectomy was performed. The histological examination was consistent with pheochromocytoma. The patient's blood pressure remained stable without antihypertensive drug use. His follow-up was uneventful after glucocorticoid and mineralocorticoid replacement therapy.

Discussion

Adrenocortical steroids influence the development and the function of adrenomedullary chromaffin cells. These interactions are relevant not only to

the regulation of the adrenal function under physiological conditions, but also to several pathological situations.⁴

Plasma adrenaline levels have been shown to be reduced in patients with Addison's disease⁵ with isolated glucocorticoid deficiency,⁶ and undergoing cortisol replacement therapy. The physiological adrenaline response to stress was also impaired in cases of isolated glucocorticoid deficiency.⁶ It has been concluded that intra-adrenal glucocorticoids are essential for normal adrenaline production.^{5,6} Glucocorticoids can induce enzymes that are necessary for catecholamine biosynthesis, especially the phenylethanolamine N-methyltransferase (PNMT) that converts norepinephrine to epinephrine, thereby favouring the more active catecholamine to be secreted into the bloodstream.⁷ It has been shown that glucocorticoid production by adrenocortical cells shows a 10-fold increase when co-cultured together with chromaffin cells, rather than with adrenocortical cells alone.⁸

Glucocorticoids are necessary for normal adrenomedullary development, as well as adrenal medullary catecholamine synthesis,¹ not only in normal chromaffin cells, but also in pheochromocytoma cells.⁹ In addition, glucocorticoids have an important permissive effect on the peripheral vasculature.³

Several cases of pheochromocytomas have been reported following the administration of exogenous glucocorticoids. Two patients with incidental adrenal masses underwent a high-dose dexamethasone suppression test, one of whom had a fatal outcome after glucocorticoid administration. In such cases, there was a time lag of 5-36 hours between steroid administration and the development of symptoms.⁹

The delayed effect in our case (five months) suggests factors other than catecholamine synthesis and vasculature responses.

This case has two distinct characteristics that were also present in other cases and studies. Firstly, in Addison's disease, with the decline of intra-adrenal glucocorticoid concentration, the provision of exogenous glucocorticoid therapy resulted in the appearance of symptoms of pheochromocytoma. Secondly, symptoms of pheochromocytoma appeared months after the initiation of exogenous glucocorticoid therapy. It is known that a symptomatic pheochromocytoma is typically > 4.5 cm in diameter.¹⁰ In our case, the mass was 2 cm in diameter, and initially, there were no symptoms of pheochromocytoma. It is recommended that patients with an adrenal tumour should be screened for pheochromocytoma, even in the absence of associated clinical signs.¹⁰ However, in our case, we focused on treating the adrenal insufficiency, and followed the course of the tumour. Five months later, typical pheochromocytoma symptoms developed in the absence of an increase in the size of the adrenal mass, as determined by MRI. It is possible that this state arose because of prolonged stimulation of the pheochromocytoma cells by the glucocorticoid replacement therapy in the face of intra-adrenal glucocorticoid insufficiency. The elevation of metanephrine alone also indicated that the defective PNMT enzyme had acquired functionality as a result of exogenous glucocorticoid administration. However, the late appearance of the clinical signs of pheochromocytoma cannot be explained solely on the basis of the induction of the catecholamine-synthesising enzymes.

Some cases with the simultaneous occurrence of two adrenal tumours with different hormone excesses have been described. Some of these are the coexistence of aldosterone-producing adenoma and pheochromocytoma,¹¹ and pheochromocytoma with contralateral cortisol-producing adrenal adenoma.¹² These cases may be coincidental. However, they may reflect that the adrenal cortex hormone excess affects the adrenal medulla, and

that excess adrenal medullary hormones may have an influence on the adrenal cortex.

The coexistence of autoimmune adrenalitis and pheochromocytoma has a further implication. It is likely that an adrenal tumour will always have its origins in either the adrenal cortex or the adrenal medulla.¹⁰ However, in our case, an adrenal tumour that was coexistent with autoimmune adrenalitis was likely to be medullary in origin. In other words, the coexistence of adrenal atrophy with an adrenal tumour should be taken as an indication of possible pheochromocytoma.

Conclusion

To our knowledge, this is the first case that has reported on the coexistence of Addison's disease and pheochromocytoma. Clinically, this case suggests that glucocorticoids as replacement therapy in adrenocortical failure may influence catecholamine-producing chromaffin cells, including pheochromocytoma cells.

References

1. Ehrhart-Bornstein M, Hinson JP, Bornstein SR, et al. Intraadrenal interactions in the regulation of adrenocortical steroidogenesis. *Endocr Rev*. 1998;19(2):101-143.
2. Whitworth JA, Williamson PM, Mangos G, Kelly JJ. Cardiovascular consequences of cortisol excess. *Vasc Health Risk Manag*. 2005;1(4):291-299.
3. Schinner S, Bornstein SR. Cortical-chromaffin cell interactions in the adrenal gland. *Endocr Pathol*. 2005;16(2):91-98.
4. Bornstein SR, Ehrhart-Bornstein M. Basic and clinical aspects of intraadrenal regulation of steroidogenesis. *Z Rheumatol*. 2000;59(Suppl 2):112-17.
5. Bornstein SR, Breidert M, Ehrhart-Bornstein M, et al. Plasma catecholamines in patients with Addison's disease. *Clin Endocrinol (Oxf)*. 1995;42(2):215-218.
6. Zuckerman-Levin N, Tiosano D, Eisenhofer G, et al. The importance of adrenocortical glucocorticoids for adrenomedullary and physiological response to stress: a study in isolated glucocorticoid deficiency. *J Clin Endocrinol Metab*. 2001;86(12):5920-5924.
7. Haase M, Willenberg HS, Bornstein SR. Update on the corticomedullary interaction in the adrenal gland. *Endocr Dev*. 2011;20:28-37.
8. Haidan A, Bornstein SR, Glasow A, et al. Basal steroidogenic activity of adrenocortical cells is increased 10-fold by coculture with chromaffin cells. *Endocrinology*. 1998;139(2):772-780.
9. Rosas AL, Kasperlik-Zaluska AA, Papierska L, et al. Pheochromocytoma crisis induced by glucocorticoids: a report of four cases and review of the literature. *Eur J Endocrinol*. 2008;158(3):423-429.
10. Young WF. Endocrine hypertension. In: Kronenberg HM, Melmed S, Polonsky KS, Larsen PR, editors. *Williams textbook of endocrinology*. 11th ed. Philadelphia: Saunders Elsevier, 2008; p. 505-537.
11. Sakamoto N, Tojo K, Saito T, et al. Coexistence of aldosterone-producing adrenocortical adenoma and pheochromocytoma in an ipsilateral adrenal gland. *Endocr J*. 2009;56(2):213-219.
12. Wolf A, Willenberg HS, Cupisti K, et al. Adrenal pheochromocytoma with contralateral cortisol-producing adrenal adenoma: diagnostic and therapeutic management. *Horm Metab Res*. 2005;37(6):391-395.