

Phaeochromocytoma – an update



Department of Chemical Pathology, University of the Witwatersrand, and National Health Laboratory Service, Johannesburg

N Lutchman, BSc, MB BCh, FCPATH (SA) (Chem Path), MMed (Chem Path)

J E Paiker, MB ChB, Dip PEC, FFPATH (SA) (Chem Path), MMed (Chem Path)

Phaeochromocytoma is a rare catecholamine-secreting neuroendocrine tumour of the chromaffin cells which occurs predominantly in the adrenal medulla. To date, germline mutations in five genes have been isolated and implicated in familial phaeochromocytomas. The syndromes include von Hippel-Lindau syndrome, multiple endocrine neoplasia type 2 syndrome, and neurofibromatosis type 1 syndrome. More recently familial paraganglioma syndromes have been described in which mutations of the genes encoding succinate dehydrogenase subunits B, C and D occur. The presenting features of phaeochromocytomas are due to the catecholamine excess and are variable in their expression as there is diversity in the phenotypes of these tumours. These tumours may result in severe morbidity and mortality from cardiovascular complications ranging from a typical paroxysmal pattern of hypertension to overt cardiac failure and sometimes sudden death. Diagnosis of phaeochromocytoma requires the biochemical confirmation of excessive catecholamine production based on measurement of either catecholamines or their metabolites in the plasma or urine, following which the tumour is localised using imaging studies. The measurement of plasma free metanephrines has recently become available for routine use. This test has generated much controversy, but has been advocated as the test of choice in many studies. The management of a phaeochromocytoma is mainly surgical and requires careful patient preparation to avoid catecholamine-induced complications during surgery. This review provides an update on phaeochromocytomas.

Introduction

Phaeochromocytoma is a rare catecholamine-secreting neuroendocrine tumour of the chromaffin cells, which occurs predominantly in the adrenal medulla. The term phaeochromocytoma originates from the Greek words *phaios* (dusky) and *chromo* (colour). The incidence is approximately 2 - 8 per million of the population, and it is thought to be present in approximately 0.2% of patients with hypertension.¹

More than 80% of these tumours are found in the adrenal gland, as this is this site where chromaffin cells remain viable after birth, the remainder being extra-adrenal. Extra-adrenal tumours are known as paragangliomas. Approximately 75% of paragangliomas occur in the organ of Zuckerkandl; however, they may also be found in the thorax, abdomen, pelvis, mediastinum and neck.² Phaeochromocytomas have traditionally been described by the 'rule of tens', i.e. 10% malignant, 10% extra-adrenal, 10% familial, and 10% in children. However, recent studies using molecular techniques have found that approximately 25% of patients have germ-line mutations of one of four susceptibility genes for phaeochromocytoma.³ Furthermore, the prevalence of extra-adrenal disease as well as malignancy far

exceeds 10%.⁴ The peak incidence of sporadic tumour occurrence is between the ages of 40 and 50 years, and there does not appear to be a gender preference.⁵⁻⁷ These tumours occur very rarely in children, and when they do occur they often present as extra-adrenal, multifocal, hereditary-type tumours.^{2,8,9} Phaeochromocytomas are associated with severe and fatal cardiovascular complications.^{1,10} The incidence of malignancy is low, but patients with a history of phaeochromocytoma appear to be at a greater risk of developing other tumours such as malignant melanoma, liver cancer, cervical cancer and central nervous system tumours.¹

Genetics

There is evidence to suggest that approximately 24% of phaeochromocytomas have a hereditary component.^{3,11} To date germline mutations in five genes have been isolated and implicated in familial phaeochromocytomas. The syndromes include von Hippel-Lindau syndrome with the tumour suppressor VHL gene, multiple endocrine neoplasia type 2 syndrome with the proto-oncogene RET gene, and neurofibromatosis type 1 syndrome with the tumour suppressor gene NF-1. More recently familial paraganglioma syndromes have been described in

which mutations of the genes encoding succinate dehydrogenase subunits B, C and D occur.¹² These genes encode proteins of mitochondrial complex II of the electron transport chain. The mechanism by which these mutations result in tumours has yet to be elucidated.

There is some controversy regarding the recommendations for genetic testing of patients with pheochromocytoma. It is believed by some authors that since approximately 25% of sporadic pheochromocytomas may carry mutations of the RET (multiple endocrine neoplasia type 2), VHL (von Hippel-Lindau syndrome), SDHD or SDHB (paraganglioma syndromes) genes, routine analysis for these mutations should be conducted on all patients presenting with pheochromocytomas.¹³

Furthermore patients with the syndromic hereditary forms present more commonly with multiple pheochromocytomas; they are also predisposed to develop other associated neoplasms as well as being subject to recurrences.⁴ They require more stringent follow-up, and screening of other family members is recommended.

However, others believe that screening of all patients is not cost-effective and recommend that only patients with a positive family history or those who present before 50 years of age, especially children, should have genetic testing.⁴

Clinical presentation

The presenting features of pheochromocytomas are due to catecholamine excess. The signs and symptoms may vary between patients, however, and can initially be fairly nonspecific resulting in a delay in diagnosis of up to 3 years. Pheochromocytomas are heterogeneous with diverse phenotypes. They may be of an epinephrine-producing and adrenergic biochemical type or norepinephrine-producing and noradrenergic biochemical type. It is this variable nature of hormone production that accounts for the variable clinical presentation of the disease.^{14,15} The most commonly encountered signs and symptoms are hypertension, palpitations, diaphoresis, headache, pallor, anxiety, and metabolic effects such as hyperglycaemia, weight loss, and lactic acidosis.⁴ Increased availability of genetic testing and abdominal imaging studies have facilitated the detection of pheochromocytomas in the preclinical phase.

The presentation of hypertension in these patients is variable. It may be paroxysmal in nature, either coupled with sustained hypertension or as paroxysms in between periods of normotension.¹⁶ Interestingly, some patients may present with orthostatic hypotension on the background of hypertension.¹⁷ The paroxysmal nature of the symptoms and signs is

due to the episodic nature of catecholamine secretion from the tumour. These paroxysms can be induced by food, micturition, some drugs such as glucagon, metoclopramide and tricyclic antidepressants, and other chemical compounds such as radiographic contrast materials.^{18,19}

These tumours also cause severe morbidity and mortality from cardiovascular complications, which include sudden death, heart failure as a consequence of cardiomyopathy, cerebrovascular accidents, hypertensive encephalopathy, neurogenic pulmonary oedema, dissecting aortic aneurysm, myocardial infarction, and cardiac arrhythmias.²⁰⁻²²

Pheochromocytomas can secrete other hormones such as neuropeptide Y, parathyroid hormone-related protein, calcitonin, adrenocorticotrophin hormone, neuron-specific enolase, interleukin-6, vasoactive intestinal peptide and chromogranin A. Patients can therefore present with additional symptoms and signs resulting from these secreted products.²³

Biochemical diagnosis

Diagnosis of pheochromocytoma requires the biochemical confirmation of excessive catecholamine production based on measurement of catecholamines or their metabolites in the plasma or urine.¹⁰ (Fig. 1). Following biochemical diagnosis the tumour is localised using imaging studies.²⁴ The associated morbidity and mortality of pheochromocytomas demand the use of a sufficiently sensitive initial test to reliably exclude the diagnosis.⁴ There is, however, a lack of consensus regarding the most efficient and cost-effective test protocol for the diagnosis of this tumour.²⁵

The indications for biochemical testing include patients presenting with paroxysmal signs and symptoms that suggest pheochromocytomas, recently diagnosed hypertension resistant to

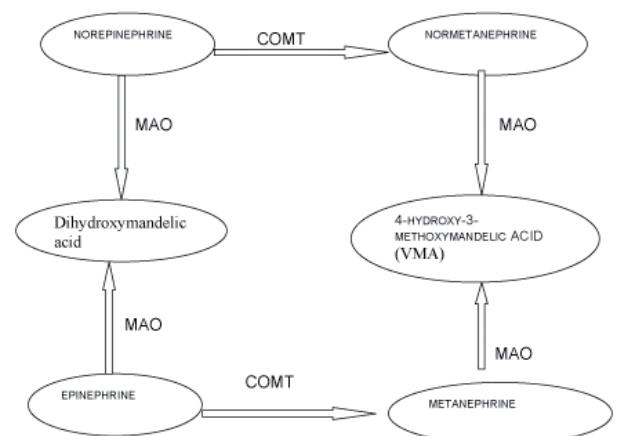


Fig. 1. Metabolism of catecholamines (adapted from Teitz⁴³) (COMT = catechol-O-methyltransferase; MAO = monoamine oxidase; VMA = vanillylmandelic acid).

therapy, paradoxical blood pressure readings during anaesthesia and surgery, any hereditary predisposition to phaeochromocytomas, sudden attacks of anxiety, and adrenal incidentalomas in asymptomatic patients.⁴

The measurement of plasma free normetanephrine and metanephrine has recently become available for routine use. (The combined measurement of unconjugated normetanephrine and metanephrine is referred to as plasma free metanephrines.) This test has generated much controversy, but has been advocated as the test of choice in many studies.^{4,25,26} Other studies, however, have shown that plasma metanephrines lack the specificity necessary for this to be recommended as a first-line screening test.²⁷⁻²⁹ They suggest that this test is the test of choice in high-risk patients with familial syndromic forms of this disease and that in lower-risk patients measurement of 24-hour urinary catecholamines and total metanephrines are more specific and yield fewer false-positive results. Other researchers suggest that the measurement of plasma free metanephrines or urinary fractionated metanephrines are the most sensitive tests for diagnosis, with sensitivities of 99% and 97%, respectively.⁴ The exceptions are small tumours < 1 cm in size, microscopic recurrences and rare dopamine-secreting paragangliomas.²⁵ The measurement of catecholamines either in plasma or

urine is not as sensitive owing to its episodic release, in contrast to metanephrine production, which occurs on a continuous basis via O-methylation by the tumour. Furthermore, some tumours do not always produce catecholamines. Although the sensitivity of these tests is high, false-positive results can complicate the reliability of these tests to exclude the diagnosis (Table I).⁴

Goldstein et al.²⁹ have suggested an algorithmic approach to the diagnosis of phaeochromocytoma, commencing with the measurement of plasma free metanephrines as the first-line diagnostic test. They also suggested using a negative plasma metanephrine result as a rule-out test for phaeochromocytoma. High results are consistent with the diagnosis of phaeochromocytoma, and one should then proceed to imaging studies to localise the tumour. If the plasma metanephrine results are only moderately increased (approximately four times the upper reference level), then a confirmatory test such as the clonidine stimulation test is indicated. Clonidine suppresses the release of catecholamines from the sympatho-adrenal axis, and failure to cause suppression of this axis is required for the diagnosis of a phaeochromocytoma. A decrease of < 50% from baseline or a consistently increased baseline of > 3 nmol/l after clonidine administration is diagnostic.^{4,29}

Table I. List of interferences causing false-positive results

Interference	Outcome	Recommendation
Physiological stimuli	Plasma epinephrine increase 100 times during hypoglycaemia, Plasma norepinephrine increases 2 - 3 times during standing, Plasma epinephrine and norepinephrine increase several times during vigorous exercise	Sampling of blood must be done after an overnight fast in a supine position to negate the effects of diet and physical activity on plasma measurements of catecholamines and their metabolites
Pharmacological agents	See Table II	See Table II
Medical conditions (heart failure, stroke, cardiogenic shock, renal insufficiency. Minor increases occur in hypothyroidism, and chronic obstructive pulmonary disease)	Increase sympathetic stimulation and therefore, increase in catecholamine levels	Patients with advanced renal insufficiency have elevated levels of plasma catecholamines, i.e. levels > 3 times the upper limit of normal is suspicious of phaeochromocytoma. ¹⁰
Diet	See Table III	See Table III
Incorrect urine sampling		Correct for incomplete or time exceeded collections by using the urine creatinine levels. 24-hour urine collections for catecholamine measurement should be acidified
Direct interference with analytical method	See Table III	See Table III

Table II. List of pharmacological agents known to cause interferences with the measurement of catecholamines and their metabolites²⁶

Pharmacological agent	Nature of interference
Tricyclic antidepressants	Blocks norepinephrine re-uptake, causing rises in plasma and urinary norepinephrine, normetanephrine, and VMA
Phenoxybenzamine	Blocks presynaptic α_2 -adrenoceptors causing increases in plasma and urinary norepinephrine, normetanephrine, and VMA
Monoamine oxidase inhibitors	Blocks deamination, causing up to fivefold increases in plasma and urinary metanephrines
Levodopa	Metabolised by enzymes that also convert catecholamines

VMA = 4-hydroxy-3-methoxymandelic acid.

Table III. List of agents known to cause interferences with the analysis of catecholamines and their metabolites.³⁰ Note that analysis using HPLC/mass spectrometry offers the best sensitivity and reliability

Interference	Analytical method and analyte affected
Coffee (including decaffeinated coffee)	HPLC assays/plasma catecholamines
Labetalol	Spectrophotometric and fluorometric assays/ urinary catecholamines and metanephrines
Sotalol	HPLC assays/plasma catecholamines
Buspirone	HPLC assays/urinary metanephrines
Paracetamol	HPLC assays/plasma free metanephrines
Levodopa	HPLC assays/catecholamines and metabolites
Sympathomimetics	Spectrophotometric and fluorometric assays/plasma and urinary catecholamines
α -methyl dopa	HPLC assays/catecholamines

HPLC = high-pressure liquid chromatography.

One of the major difficulties in the diagnosis of pheochromocytoma is distinguishing between true-positive and false-positive results. In general terms these can be distinguished by the magnitude of the increase of the test results above the reference range. The difficulty resides in those patients who show increases less than 2 - 3 times the upper reference limit. Similar patterns of increase in both plasma and urinary metanephrines and or similarities in increases on repeat or alternative method testing are likely to be true-positive results.³⁰

There is some indication from the literature that a strong positive relationship exists between tumour diameter and the summed plasma concentrations of free metanephrines that might be useful for predicting tumour size.²⁵

Several authors agree that approximately half of adrenal tumours secrete norepinephrine exclusively and the other half a mixture of norepinephrine and epinephrine. With regard to hereditary-type tumours,

the pattern of catecholamine secretion is dependent on the underlying mutation. It has been found that patients with von Hippel-Lindau syndrome secrete predominantly norepinephrine, while patients with multiple endocrine neoplasia type 2 syndrome produce a mixture of norepinephrine and epinephrine. It is thought that there are distinct gene expression patterns that result in different tumorigenesis pathways and therefore the possibility of tumours arising from different populations of chromaffin cells.²⁵

Chromogranin A levels are increased in 80% of patients with pheochromocytomas, but this is less specific and sensitive than catecholamine and or their metabolites for diagnosis. It is therefore recommended for use as an adjuvant test.³

Imaging procedures

The tumour is localised only once there is unequivocal biochemical evidence for the presence of the disease. The initial investigation is a computed tomography