Journal of Endocrinology, Metabolism and Diabetes of South Africa 2021; 26(1):9–15
https://doi.org/10.1080/16089677.2020.1838161

Open Access article distributed under the terms of the
Creative Commons License [CC BY-NC 4.0]
http://creativecommons.org/licenses/by-nc/4.0

JEMDSA
ISSN 1608-9677 EISSN 2220-1009
© 2020 The Author(s)
ARTICLE

Prevalence of succinate dehydrogenase deficiency in paragangliomas and phaeochromocytomas at a tertiary hospital in Cape Town: a retrospective review

Cassandra Bruce-Brand* and **Abraham C van Wyk**

Division of Anatomical Pathology, Tygerberg Hospital, National Health Laboratory Service (NHLS), Faculty of Medicine and Health Sciences, Stellenbosch University, Cape Town, South Africa
**Correspondence: Cassandra.bruce-bran@nhls.ac.za*

Check for updates

Introduction: A substantial proportion of phaeochromocytomas and paragangliomas are associated with underlying germline mutations, of which the majority are due to mutations in one of the genes in the succinate dehydrogenase (SDH) complex. A commercially available immunohistochemical stain for SDHB has excellent correlation with SDH gene mutation status when staining is lost. This abnormal loss of staining can identify potential familial tumours and tumours with a higher risk of malignant behaviour. The prevalence of SDH deficiency in the South African setting has not been published previously.
Methods: A retrospective laboratory-based study at Tygerberg Hospital in Cape Town used immunohistochemistry on archived tumour tissue to assess loss of SDHB staining in phaeochromocytomas and paragangliomas submitted to the histopathology laboratory (National Health Laboratory Service) between 2005 and 2015.
Results: Tumour tissue from 52 patients was tested. In total, 36% showed loss of staining. Loss of staining was significantly correlated with a younger age at presentation ($z = -3.59$, $p < 0.001$). The median age of those who showed loss of staining was 26 years (IQR 21–41), compared with 50.5 years (IQR 36–61) for those who showed retained staining. The inter-observer agreement in the interpretation of the immunohistochemical stain was excellent (Cohen's kappa = 0.917; 95% confidence interval, 0.81–1, $p < 0.001$).
Conclusion: Approximately one-third of phaeochromocytomas and paragangliomas in our setting are likely to be associated with germline mutations in one of the SDH genes. Immunohistochemical testing of tumour tissue can identify this group to allow better prognostication and appropriate genetic testing and counselling.

Keywords: paraganglioma, phaeochromocytoma, South Africa, succinate dehydrogenase

Introduction

Phaeochromocytomas (PCs) and paragangliomas (PGLs) are rare neural crest-derived tumours that arise in the adrenal medulla and sympathetic or parasympathetic ganglia.[1] The World Health Organization defines PCs as tumours of chromaffin cells that arise in the adrenal medulla while extra-adrenal PGLs are defined as tumours originating from neural crest-derived paraganglion cells in the region of the autonomic nervous system ganglia and autonomic nerves.[1] Sympathetic PGLs are catecholamine secreting tumours and include those in the adrenal gland (PC) as well as extra-adrenal sites, predominantly the thorax and abdomen (thoraco-abdominal PGLs – TAPGLs).[1] Parasympathetic PGLs are extra-adrenal, do not secrete catecholamines and occur predominantly in the head and neck region (head and neck PGLs – HNPGLs).[1]

PGLs and PCs can occur sporadically or as hereditary tumours with up to 40% occurring as a result of germline mutations in susceptibility genes.[2,3] Research conducted in the nineteenth and twentieth centuries led to the recognition of three PC/PGL-associated syndromes: von Hippel-Lindau (VHL) disease, multiple endocrine neoplasia type 2 (RET) and neurofibromatosis type 1 (NF1).[4–9] Between 2000 and 2010, the molecular basis for hereditary PC/PGL syndrome was discovered to be due to mutations in succinate dehydrogenase (SDH) subunits and related genes.[10–16] New susceptibility genes causing hereditary PC/PGL syndrome discovered over the past ten years included MAX, TMEM127, EGLN, HIF2α, MET and KIF1B.[2] Currently these susceptibility genes are grouped into two categories: major susceptibility genes including NF1, VHL, RET and SHDB/D and minor susceptibility genes including SDHA/C, SDHAF2, MAX and TMEM127.[3,17] The major susceptibility genes account for up to 90% of the hereditary tumours, the minor group accounts for the other 10%.[3,17]

The SDH enzyme complex (mitochondrial complex II) catalyses the conversion of succinate to fumarate in the Krebs cycle.[16] Loss of heterozygosity with inactivating germline mutations results in destabilisation of the SDH protein complex and abolishes its enzymatic activity leading to an accumulation of succinate.[16,18–20] This results in reactive oxygen species causing free radical damage and activation of a pseudohypoxia pathway by increasing hypoxia-inducible factors.[16,18–21] A third mechanism that has been proposed to explain how Krebs cycle dysfunction can lead to neoplasia is through a decrease in apoptosis.[21] The SDH complex consists of four subunits, SDHA, SDHB, SDHC and SDHD. Hereditary PC/PGL syndrome can be caused by germline mutations in any of the SDH subunits as well as in SDHAF2, a mitochondrial protein that flavinates SDHA and promotes maturation of SDHB.[16,21–24]

The reported rate of SDH mutations in PGLs varies significantly between series, ranging from 15% to 54%.[15,25] Mutations in SDHB and SDHD are the most common of the four subunits and correspond to syndromes PGL4 and PGL1 respectively.[26] SDHB mutated tumours (PGL4) are usually abdominal and

have the highest risk of metastases. Up to 71% of paragangliomas with SDHB mutations have been shown to metastasise compared with only 3% of non-SDHB mutated cases.[14,15] Furthermore, SDHB mutations, which show incomplete penetrance, result in tumours at younger ages.[27] In contrast, tumours with SDHD mutations are typically found in the head and neck region, and are multiple and recurrent with a very low rate of metastases.[28]

Immunohistochemistry (IHC) for SDHB can be used to identify tumours with underlying SDH germline mutations.[29] Destabilisation of any of the four subunits of SDH results in loss of SDH complex enzymatic activity, which can be detected by loss of immunohistochemical staining for SDHB.[29] SDHB IHC has therefore emerged as a more cost-effective method to 'triage' genetic testing of SDH genes as it selects out patients who can then undergo further confirmation of the presence of SDH gene mutation.[29,30] Several studies have demonstrated that SDH IHC has a high diagnostic accuracy (sensitivity and specificity of up to 100% reported in some studies) with low inter-observer variability and a good negative predictive value.[29,30] A large study using web-based virtual microscopy showed substantial inter-observer agreement in interpretation of SDHB IHC with a kappa value of 0.73.[31]

Mutations of one of the SDH subunits are almost always due to germline mutations and are very rarely somatic.[31–34] Loss of SDHB immunohistochemical staining in these cases therefore signifies likely syndromic disease due to germline SDH mutations or, rarely, hypermethylation of SDHC.[35] Apart from the identification of tumours with underlying germline mutations with implications for patients and family members, loss of SDHB staining can also identify abdominal PGLs with a high risk for malignant behaviour. This is helpful because metastatic potential in PC and PGLs is difficult to predict and there is conflicting data on the use of histologic features to do so.[1]

Currently the percentage of PC/PGLs with mutations of SDH in the South African setting is unknown. This lack of knowledge of susceptibility genes in the African setting is highlighted in the first case report of an SDHB associated paraganglioma in an African patient in 2018.[36] To the authors' knowledge no published studies have been conducted in South Africa to determine the prevalence of loss of SDHB staining.

Methods

A retrospective descriptive laboratory-based study was conducted at Tygerberg Hospital. Biopsy and resection specimens from patients diagnosed with PGL and/or PC between 2005 and 2015 were identified via the electronic laboratory information system, retrieved from the archive and independently reviewed by the two authors. Cases of PGL and PC where the formalin-fixed and paraffin-embedded tissue blocks could not be retrieved were excluded from this study. Cases in which there was disagreement regarding the diagnosis of PC/PGL upon review were also excluded. Only one case per patient was included as SDH mutations are almost exclusively germline and the presence of an SDH mutation would therefore likely be present in all PC/PGLs from the same patient. Clinical information such as age and sex were retrieved from the laboratory information system. Information regarding ethnicity of patients was not available to the authors.

The slides were stained using an SDHB antibody (HPA002868, rabbit polyclonal IgG; Sigma Aldrich, St Louis, MO, USA) on an automated immunohistochemical stainer (Bond III, Leica Biosystems, Buffalo Grove, IL, USA) according to standard operating procedures (SOP) and the manufacturer's instructions. This stain was validated using two PGLs in which the SDH mutation status of the patients was known (germline testing had been performed). In the PGL in which the patient was known to have an SDHB mutation the IHC showed loss of staining as expected (Figure 1). In the PGL in which the patient had no SDH mutation by germline testing the IHC showed retention of staining (Figure 2).

Normal retained staining was interpreted as granular cytoplasmic staining in the tumour cells. Any amount of positive staining was interpreted as retained staining. Loss of staining was interpreted as complete absence of cytoplasmic staining in the tumour cells with retained staining of the external and internal controls. Internal controls included sustentacular cells and endothelial cells. The IHC stains were interpreted by the two authors independently and the results were then compared. Discordant cases were reviewed at a combined microscopy session to come to a consensus interpretation.

Data were analysed using IBM SPSS Statistics, version 25 (IBM Corp, Armonk, NY, USA). A Mann–Whitney U-test was used to compare the median age of patients who had retention and loss of staining. Chi-square tests were used to determine whether there was an association between retention of staining and (a) sex, and (b) site of tumour. Inter-observer reliability for coding of retained or lost staining was assessed using Cohen's kappa.

This study received ethical approval from the Stellenbosch University Health Research Ethics Committee (HREC) on 14 March

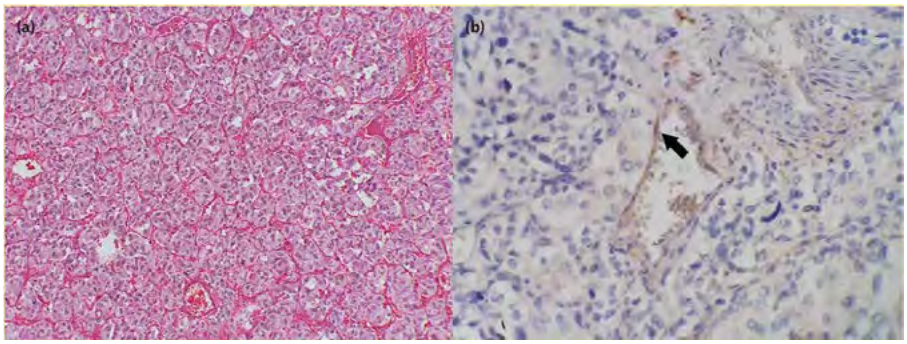

Figure 1: (a) Haematoxylin and eosin stained section, 100x magnification: paraganglioma in a patient with confirmed SDH mutation; (b) SDHB immunohistochemistry showing loss of staining in the tumour cells with retained granular cytoplasmic staining in the endothelial cells (internal control), see arrow.

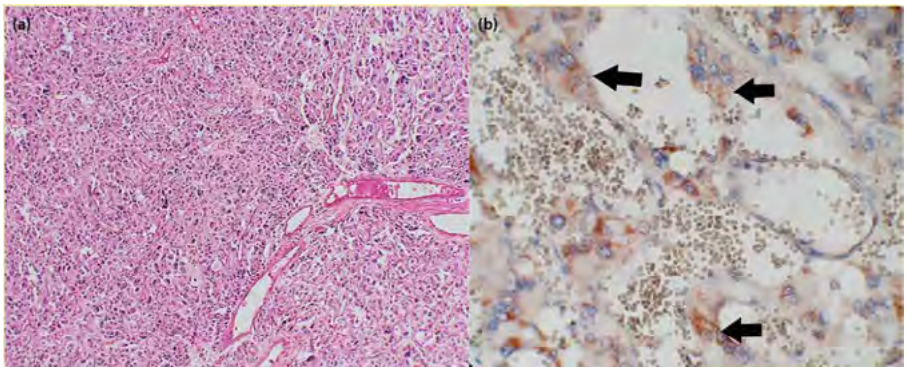

Figure 2: (a) Haematoxylin and eosin stained section, 40x magnification: pheochromocytoma in a patient with no SDH mutation on germline testing; (b) SDH immunohistochemistry showing retained granular cytoplasmic staining in the tumour cells (arrows).

2017 (reference number: S17/02/041). An annual renewal of ethics approval was obtained from the HREC following submission of annual progress reports.

Results

Sixty-five PCs/PGLs were identified between 2005 and 2015. Four patients had multiple specimens of PC/PGL, either recurrences or metastases (three patients had three specimens each, one patient had two specimens). A total of 58 patients were therefore identified. A further six cases were excluded – one in which the preferred diagnosis after review was a neuroendocrine tumour and five for which the wax blocks could not be retrieved. Fifty-two cases were therefore included in the final sample (Figure 3).

The median age of the patients was 43.5 years (SD = 16.21 years; range: 7–71 years). Females were more strongly represented (65%). Tumours located in the head and neck region made up 50% of the sample ($n = 26$). The majority of HNPGLs were carotid body tumours (50%) followed by jugulo-tympanic tumours (38%). Other head and neck sites included neck (not further specified), laryngeal and skull (not further specified). Thoraco-abdominal cases made up 46% of the sample ($n = 24$) with the majority occurring in the adrenal gland (58%) and para-aortic sites (25%). Other thoraco-abdominal sites included liver, pelvic and retroperitoneal (not further specified). The remainder of the cases were spinal (4%, $n = 2$). A total of three patients (6%) had metastatic disease.

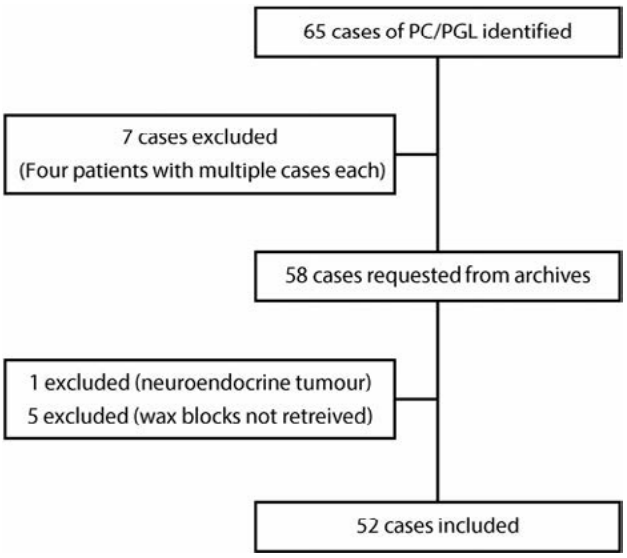

Figure 3: Flow diagram of the case selection process.

Loss of SDHB staining was present in 36% of tumours ($n = 19$). Retained staining was therefore seen in 64% ($n = 33$) with no tumours showing equivocal staining (Figures 4 and 5). Patients who had loss of staining were significantly younger than those who had retained staining ($z = -3.59$, $p < 0.001$). The median age of those who showed loss of staining was 26 years (IQR 21–41), compared with 50.5 years (IQR 36–61) for those who showed retained staining. Sex was not associated with loss of staining ($\chi^2 = 2.15$, $p = 0.142$), with 9 of the 18 males (50%) compared with 10 of the 34 females (29.4%) showing loss of staining. There was a significant association between tumour location (extra-adrenal tumours/PGL vs. adrenal tumours/PC) and loss of staining ($\chi^2 = 7.139$, $p = 0.008$). Only 7.1% of phaeochromocytomas demonstrated loss of staining while 47.4% of paragangliomas showed loss of staining. The specific site of tumour was not significantly associated with loss of staining ($\chi^2 = 0.94$, $p = 0.333$), with 7 of the 24 TAPGLs (29.2%) compared with 11 of the 26 HNPGLs (42.3%) showing loss of staining (a summary of these findings can be seen in Table 1).

The inter-observer agreement between the two interpreters was excellent (Cohen's kappa = 0.917; 95% confidence interval, 0.81–1, $p < 0.001$) with discordant interpretation in only two cases.

Discussion

The incidence of PC/PGL in South Africa is not known as these tumours are not specifically captured in the South African National Cancer Registry. PC/PGL occur at an incidence of 500–1 600 cases per year in the United States, a country with a population size roughly 5.5 times that of South Africa.[37] These tumours can occur at any age with a peak in the fourth and fifth decades of life and a roughly equal sex distribution.[38] HNPGL are more common in women, particularly at high altitudes (8:1 female to male ratio).[39,40] Little information is available regarding differences in incidence rates according to ethnicity. In a series of 59 cases of metastatic head and neck paraganglioma from the United States, a slightly higher than expected proportion of patients were African American and Hispanic.[39]

There is a paucity of information regarding the demographic profile of PC/PGL in South Africa. The largest published series to date includes 60 patients, of whom 33% were male and 67% were female, with a mean age of 47 years (range 14–81).[41] No data on ethnicity were recorded for these cases. A

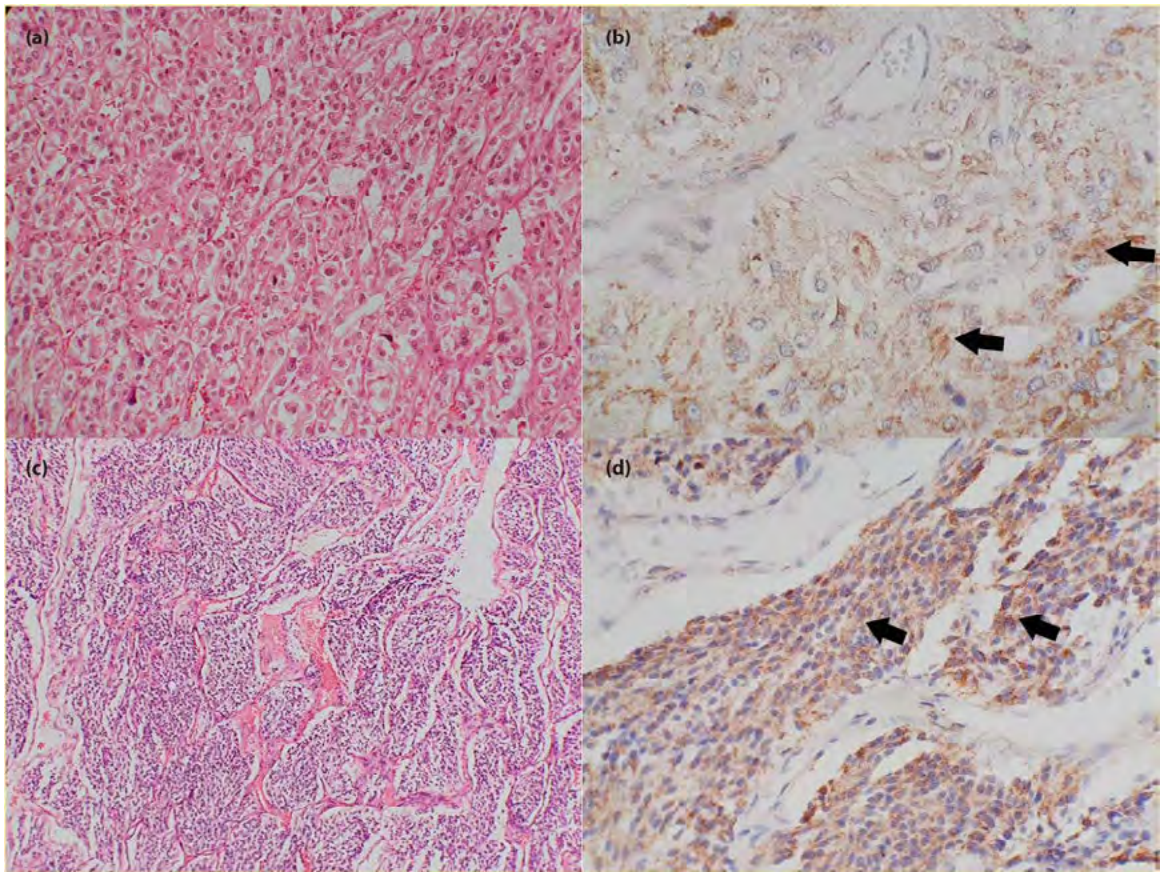

Figure 4: (a) Haematoxylin and eosin stained section, 100x magnification: adrenal pheochromocytoma; (b) SDHB immunohistochemical stain of (a) showing retained staining with granular cytoplasmic staining (arrows); (c) haematoxylin and eosin stained section, 40x magnification: jugulo-tympanic paraganglioma; (d) SDHB immunohistochemical stain of (c) showing retained staining with granular cytoplasmic staining (arrows).

series of 54 black patients with phaeochromocytoma from a hospital in Gauteng showed a female to male ratio of 3.2:1 and an age range from 8 to 57 years.[42] A series of 35 cases of phaeochromocytoma from a Durban hospital comprised 60% African patients, 28.6% Asian Indians, 8.6% white and 2.9% mixed-race patients.[43] This series included 14 males and 21 females with a mean age of 32.2 years, ranging from 11 to 69 years.[43] Similar to these studies, our study also showed a female predominance of patients with PC/PGL. Unfortunately, the ethnicity of the patients in our study was not known to us.

In this study, loss of SDH staining was present in 36% of cases, which falls within the range reported in the literature of 15–54%.[15,25] This again emphasises the fact that PCs/PGLs are likely to be associated with hereditary syndromes at a much higher frequency than traditionally thought. Loss of staining was significantly correlated with a younger age at presentation. This is an expected finding as patients with SDH germline mutations develop disease at a significantly younger age than those without germline mutations.[27]

All three patients known to have metastatic disease showed loss of staining. However, due to the small number, a statistically significant correlation could not be drawn.

The inter-observer agreement was excellent (Cohen's kappa = 0.917, $p < 0.001$) and is similar to the inter-observer agreement that has been reported in the literature among endocrine pathologists.[31] Consensus could easily be reached in the two cases that were initially interpreted differently. We acknowledge that interpretation of this stain can be difficult as it requires identification of loss of a granular cytoplasmic stain. However, our excellent inter-observer variability demonstrates that following strict and clear guidelines should allow accurate interpretation of this stain by other general pathologists in our setting.

The relative frequent finding of SDH loss highlights the need to utilise this stain routinely on all PCs/PGLs in our setting. While multigene panel germline testing will probably become more accessible and cost-effective and may eventually obviate the need for immunohistochemical staining in PC/PGL, many patients in South Africa currently do not have access to genetic testing as this is still costly and not widely available. IHC is widely available in South African anatomical pathology laboratories, is relatively affordable, and can be used to assess the need for further targeted germline testing.

Limitations of this study include the small sample size from a single centre and the lack of confirmatory germline testing on all tumours. Based on the published literature, SDHB IHC is an excellent surrogate marker for germline mutations in any of the SDH subunits.[29,30] In two control tumours in which germline mutation status was known, the stain correctly showed intact staining in the tumour without any SDH gene mutations and loss of staining in a tumour with a germline SDHB mutation. Because loss of SDHB IHC indicates a mutation in any of the subunits of the SDH complex, the frequency of mutations in the respective subunits could not be assessed and therefore

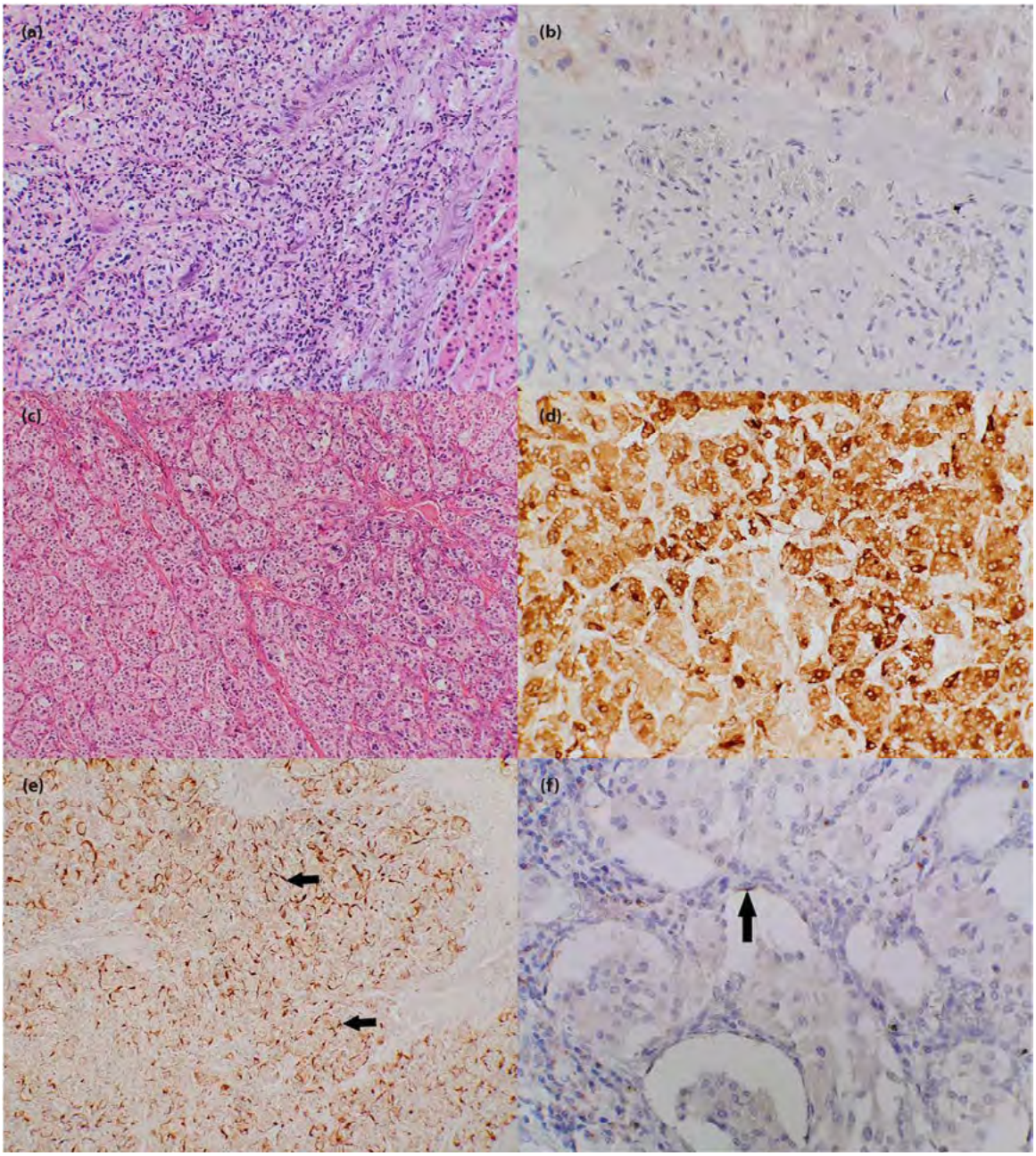

Figure 5: (a) Haematoxylin and eosin stained section, 40x magnification: metastatic paraganglioma in the liver, note the tumour (left) and the background liver parenchyma (bottom right); (b) SDHB immunohistochemical stain showing loss of staining in the tumour in (a) (bottom) with granular cytoplasmic staining in the adjacent hepatic parenchyma (top); (c) haematoxylin and eosin stained section, 40x magnification: carotid body paraganglioma; (d) chromogranin-A, granular cytoplasmic staining in the carotid body paraganglioma seen in (c); (e) S100 immunohistochemistry showing sustentacular cells around nests of tumour cells (arrows) in the paraganglioma seen in (c); (f) SDHB immunohistochemical stain showing loss of staining in the tumour with retained granular cytoplasmic staining in sustentacular and endothelial cells (arrow).

Table 1: Summary of 52 PC/PGL cases

Factor	Adrenal	Other TAPGL	All HNPGL	Spinal	All PGL	All cases
	14	10	26	2	38	52
SDHB lost	1 (7%)	6 (60%)	11 (42%)	1 (50%)	18 (47%)	19 (36%)
Age (mean)	23	7–53 (26)	21–55 (33)	40	7–55 (31)	21–41 (26)
Sex (M/F)	1/0	3/3	4/7	1/0	8/10	9/10
SDHB retained	13 (93%)	4 (40%)	15 (58%)	1 (50%)	20 (53%)	33 (64%)
Age (mean)	19–67 (45)	43–49 (46)	22–71 (50)	57	22–71 (50)	36–61 (51)
Sex (M/F)	5/8	1/3	3/12	0/1	4/16	9/24

PC: phaeochromocytoma, PGL: paraganglioma, SDHB: succinate dehydrogenase B, M: male, F: female, TAPGL: thoraco-abdominal paraganglioma, HNPGL: head and neck paraganglioma.

subclassification of paraganglioma syndrome subgroups could not be done.

Further studies using a larger sample size, ideally with multicentre data from various centres in South Africa, will be of value to determine the prevalence of SDH germline mutations in PC/PGL in the general South African population. Although genetic germline testing is costly, a study that correlates SDH mutation status with SDHB immunohistochemical staining will be of value in validating the use of IHC instead of genetic testing in our setting and also allow identification of the specific SDH subunit involved.

In conclusion, we have shown that loss of SDHB immunohistochemical staining can be interpreted with excellent inter-observer agreement between pathologists and identifies approximately one-third of PCs/PGLs in our setting to likely have germline mutations in one of the SDH genes.

Disclosure statement – No potential conflict of interest was reported by the author(s).

Funding – This work was supported by the NHLS Research Trust Development Grant [Grant number: 00494643].

ORCID

Cassandra Bruce-Brand http://orcid.org/0000-0003-0438-768X
Abraham C van Wyk http://orcid.org/0000-0002-0946-2434

References

1. Lloyd R, Osamura R, Klöppel G, Rosai J. WHO classification of tumours of endocrine organs. Lyon: IARC; 2017.
2. Welander J, Soderkvist P, Gimm O. Genetics and clinical characteristics of hereditary pheochromocytomas and paragangliomas. Endocr Relat Cancer. 2011;18(6):R253–R276.
3. Gimenez-Roqueplo A, Dahia P, Robledo M. An update on the genetics of Paraganglioma, Pheochromocytoma and associated hereditary syndromes. Horm Metab Res. 2012;44(5):328–333.
4. Cawthon R, Weiss R, Xu G, et al. A major segment of the neurofibromatosis type 1 gene: cDNA sequence, genomic structure, and point mutations. Cell. 1990;62:193–201.
5. Xu G, O'Connell P, Viskochil D, et al. The neurofibromatosis type 1 gene encodes a protein related to GAP. Cell. 1990;62(3):599–608.
6. Latif F, Tory K, Gnarra J, et al. Identification of the von Hippel-Lindau disease tumor suppressor gene. Science. 1993;260:1317–1320.
7. Mulligan L, Kwok J, Healey C, et al. Germ-line mutations of the RET proto-oncogene in multiple endocrine neoplasia type 2A. Nature. 1993;363:458–460.
8. Crossey P, Richards F, Foster K, et al. Identification of intragenic mutations in the Von Hippel—Lindau disease tumour suppressor gene andcorrelation with disease phenotype. Hum Mol Genet. 1994;3:1303–1308.
9. Else T. 15 years of Paraganglioma: Phaeochromocytoma, Paraganglioma and genetic syndromes: a historical perspective. Endocr Relat Cancer. 2015;22:T147–T159.
10. Baysal B, Ferrell R, Willett-Brozick J. Mutations in SDHD, a mitochondrial complex II gene, in hereditary paraganglioma. Science. 2000;287:848–851.
11. Burnichon N, Briere J, Libe R. SDHA is a tumor suppressor gene causing paraganglioma. Hum Mol Genet. 2010;19:3011–3020.
12. Astuti D, Douglas F, Lennard T. Germline SDHD mutation in familial phaeochromocytoma. Lancet. 2001;357:1181–1182.
13. Niemann S, Muller U. Mutations in SDHC cause autosomal dominant paraganglioma, type 3. Nat Genet. 2000;26:268–270.
14. Barletta JA, Hornick JL. Succinate dehydrogenase-deficient Tumors : diagnostic advances and clinical implications. Adv Anat Pathol. 2012;19(4):193–203.
15. Gill A. Succinate dehydrogenase (SDH) and mitochondrial driven neoplasia. Pathology. 2012;44(4):285–292.
16. Hao H, Khalimonchuk O, Schraders M, et al. SDH5, a gene required for flavination of succinate dehydrogenase, is mutated in paraganglioma. Science. 2009;325:1139–1142.
17. Burnichon N, Vescovo L, Amar L, et al. Integrative genomic analysis reveals somatic mutations in pheochromocytoma and paraganglioma. Hum Mol Genet. 2011;20:3974–3985.
18. Favier J, Gimenez-Roqueplo A. Pheochromocytomas: The (pseudo)-hypoxia hypothesis. Best Pr Res Clin Endocrinol Metab. 2010;24:957–968.
19. Dahia P. Transcription association of VHL and SDH mutations link hypoxia and oxidoreductase signals in pheochromocytomas. Ann N Y Acad Sci. 2006;1073:208–220.
20. Kaelin WJ. Cancer and altered metabolism: potential importance of hypoxia-inducible factor and 2-oxoglutarate-dependent dioxygenases. Cold Spring Harb Symp Quant Biol. 2011;76:335–345.
21. Rasheed M, Tarjan G. Succinate dehydrogenase complex: An Updated review. Arch Pathol Lab Med. 2018;142(December):1564–1570. doi:10.5858/arpa.2017-0285-RS
22. Poplawski NK, Rawlings L, Seymour J, et al. Genetic testing and immunohistochemistry for SDHB in phaeochromocytoma-paraganglioma syndromes: the South Australian experience. Hered Cancer Clin Pr. 2012;10(Suppl 2):1–2. doi:10.1186/1897-4287-10-S2-A60
23. Aldera A, Govender D. Gene of the month: SDH. J Clin Pathol. 2018;71:95–97.
24. Favier J, Amar L, Gimenez-Roqueplo A. Paraganglioma and phaeochromocytoma: from genetics to personalized medicine. Nat Rev Endocrinol. 2015;11:101–111.
25. Burnichon N, Rohmer V, Amar L. The succinate dehydrogenase genetic testing in a large prospective series of patients with paragangliomas. J Clin Endocrinol Metab. 2009;94:2817–2827.
26. Baysal B, Willett-Brozick J, Lawrence E. Prevalence of SDHB, SDHC, and SDHD germline mutations in clinic patients with head and neck paragangliomas. J Med Genet. 2002;39(3):178–183.
27. Srirangalingam U, Walker L, Khoo B, et al. Clinical manifestations of familial paraganglioma and phaeochromocytomas in succinate dehydrogenase B (SDH-B) gene mutation carriers. Clin Endocrinol (Oxf). 2008;69:587–596.
28. Neumann H, Pawlu C, Peczkowska M, et al. Distinct clinical features of paraganglioma syndromes associated with SDHB and SDHD gene mutations. JAMA. 2004;292:943–951.
29. van Nederveen F, Gaal J, Favier J, Kopershoek E. An immunohistochemical procedure to detect patients with paraganglioma and phaeochromocytoma with germline SDHB, SDHC, or SDHD gene mutations: a retrospective and prospective analysis. Lancet Oncol. 2009;10:764–771.
30. Pai R, Manipadam MT, Singh P, Ebenazer A, Samuel P, Rajaratnam S. Usefulness of succinate dehydrogenase B (SDHB) immunohistochemistry in guiding mutational screening among patients with pheochromocytoma- paraganglioma syndromes. APMIS. 2014;122:1130–1135.
31. Papathomas T, Oudijk L, Persu A, et al. SDHB/SDHA immunohistochemistry in pheochromocytomas and paragangliomas : a multicenter interobserver variation analysis using virtual microscopy: a multinational study of the European Network for the Study of Adrenal Tumors (ENS@T). Mod Pathol. 2015;28:807–821.
32. Imamura H, Muroya K, Tanaka E. Sporadic paraganglioma caused by de novo SDHB mutations in a 6-year-old girl. Eur J Pediatr. 2016;175:137–141.
33. van Nederveen F, Korpershoek E, Lenders J, de Krijger R, Dinjens W. Somatic SDHB mutation in an extra adrenal pheochromocytoma. N Engl J Med. 2007;357:306–308.
34. Gimm O, Armanios M, Dziema H, Neumann H, Eng C. Somatic and occult germ-line mutations in SDHD, a mitochondrial complex II gene, in non-familial pheochromocytoma. Cancer Res. 2000;60:6822–6825.
35. Killian J, Miettinen M, Walker R. Recurrent epimutation of SDHC in gastrointestinal stromal tumors. Sci Transl Med. 2014;6(268):268ra177.
36. Shone D, Goedhals J, Pearce NE. Malignant paraganglioma in an African patient associated with a succinate dehydrogenase subunit B (SDHB) mutation. SAJS. 2018;56(2):64–66.
37. Chen H, Sippel R, O'Dorisio M. The North American Neuroendocrine Tumor Society consensus guideline for the diagnosis and

management of neuroendocrine tumors: pheochromocytoma, paraganglioma, and medullary thyroid cancer. Pancreas. 2010;39(6):775–783.
38. Mannelli M, Castellano M, Schiavi F. Clinically guided genetic screening in a large cohort of Italian patients with pheochromocytomas and/or functional or nonfunctional paragangliomas. J Clin Endocrinol Metab. 2009;94(5):1541–1547.
39. Lee J, Barich F, Karnell L, et al. National cancer data Base report on malignant paragangliomas of the head and neck. Cancer. 2002;94(3):730–737.
40. Rodríguez-Cuevas S, López-Garza J, Labastida-Almendaro S. Carotid body tumors in inhabitants of altitudes higher than 2000 meters above sea level. Head Neck. 1998;20(5):374–378.
41. Nel D, Panieri E, Malherbe F, Steyn R, Cairncross L. Surgery for pheochromocytoma: A single-center review of 60 cases from South Africa. World J Surg. 2020;44:1918–1924.
42. Huddle K. Phaeochromocytoma in black South Africans – a 30-year audit. SAMJ. 2011;101(3):184–188.
43. Zorgani A, Pirie F, Motala A. Characteristics and outcome of patients with pheochromocytoma at a tertiary endocrinology clinic in Durban, South Africa over 14 years. J Endocrinol Metab Diabetes South Africa. 2018;23(2):52–58.

Received: 20-07-2020 Accepted: 14-10-2020