

Latest diagnostic approaches to determine the cause of ACTH-dependent Cushing's syndrome, in the South African setting

Elmo Pretorius^{a*}, Razaan Davis^b, Alexander Doruyter^c and Brynne Ascott-Evans^a

^aFaculty of Medicine and Health Sciences, Division of Endocrinology, Department of Medicine, Stellenbosch University and Tygerberg Academic Hospital, Cape Town, South Africa

^bFaculty of Medicine and Health Sciences, Division of Radiodiagnosis, Department of Medical Imaging and Clinical Oncology, Stellenbosch University and Tygerberg Academic Hospital, Cape Town, South Africa

^cFaculty of Medicine and Health Science, Division of Nuclear Medicine, Department of Medical Imaging and Clinical Oncology, Stellenbosch University and Tygerberg Academic Hospital, Cape Town, South Africa

*Corresponding author, email: elmo@sun.ac.za

A case of a 50-year-old woman who was referred for the evaluation of possible ACTH-dependent Cushing's syndrome (CS) is described. The localisation of ACTH-dependent CS remains difficult despite many advances in diagnostic approaches. No single test can accurately determine the location of ACTH excess and therefore a combination of non-invasive imaging, stimulation and suppression tests are advised. The recent advances, current utility and pitfalls of each of these tests are reviewed. If non-invasive tests fail to confidently localise the source of ACTH excess, inferior petrosal sinus sampling (IPSS) should follow. Recent advances improving the diagnostic accuracy of IPSS, such as DDAVP stimulation and simultaneous sampling for prolactin is discussed. Where ectopic ACTH production is suspected, newer nuclear medicine techniques, such as somatostatin receptor imaging that recently became available in South Africa, can be utilised. The role of nuclear medicine imaging in identifying ectopic ACTH production is discussed briefly.

Keywords: ACTH, cushing's disease, pituitary

Case presentation

A 50-year-old obese woman was referred to the division of Endocrinology at Tygerberg Hospital for the evaluation of possible Cushing's syndrome (CS). She had been diagnosed with diabetes mellitus and hypertension in the preceding year and noted unexplained marked weight gain, in excess of 12 kilograms in three months. She had no history of alcohol abuse or depression and took no medication apart from anti-hypertensives and oral anti-diabetes drugs. On examination she was morbidly obese with a BMI of 43 kg/m². She had thin skin, violaceous striae and facial plethora. On bone mineral density assessment she had osteoporosis most markedly in her lumbar spine. Her serum cortisol failed to suppress on an overnight 1 mg betamethasone test (444 nmol/L). Twenty-four hour urine free cortisol was also elevated (1356 nmols/24 hours) and her serum cortisol failed to suppress on prolonged low-dose betamethasone testing (0.5 mg 12 hourly for 48 hours). Adrenocorticotrophic hormone (ACTH) was 9.3 pmol/L (normal 1.1–10.2 pmol/L).

Background

The diagnosis of CS remains difficult despite many advances in diagnostic approaches. The difficulties lie in both the functional demonstration and the localisation of hormonal overproduction. Apart from the problem of differentiating true CS from pseudo-Cushing's, ACTH-dependent CS also poses a particular diagnostic challenge.

In approximately 40% of cases, ACTH-producing pituitary adenomas in pituitary Cushing's disease (PC) are not visualised on magnetic resonance imaging (MRI) of the pituitary.¹ Moreover, non-functioning pituitary microadenomas may occur in up to 10% of the general population.² Thus, in patients with ectopic ACTH producing tumours (EC), an incidental finding of a pituitary

microadenoma (which may falsely attribute the source of ACTH production to the pituitary) is not uncommon.³ Therefore, isolated MRI findings of either the absence or presence of a pituitary microadenoma is of little value without biochemical evidence in support of the MRI findings.

Testing in ACTH-dependent CS is problematic, considering that PC is by far the most common aetiology of CS. The pre-test probability for PC is about 80–90%.⁴ Therefore any test that differentiates PC from EC needs to be very accurate to improve on the pre-test probability of PC. Inferior petrosal sinus sampling (IPSS) remains the most accurate method to localise the source of ACTH excess.^{5,6} However, IPSS is invasive with a risk of adverse events and requires expertise that is not readily available, especially in South Africa. Unfortunately no non-invasive test, when used in isolation, can improve on the aforementioned pre-test probability for PC. As a result, a three-pronged testing approach has been proposed in subjects with ACTH-dependent Cushing's syndrome, prior to proceeding to IPSS.^{4,6}

First, MRI of the pituitary should be performed. This should be followed by a high dose dexamethasone suppression test (HDDST). Third, a stimulation test using either corticotropin releasing hormone (CRH) or desmopressin (DDAVP) should be performed. If an adenoma of more than 6 mm (based on consensus recommendation)¹ is demonstrated and the results of the suppression and stimulation tests are concordant and in keeping with a pituitary source of ACTH overproduction, the diagnosis of PC is made and surgery can be recommended without IPSS. However, if any of the three criteria (positive imaging, suppression test and stimulation test) are not met, invasive testing by means of IPSS should follow. Should IPSS not suggest PC, further imaging to localise EC should ensue.

However, where clinical and/or biochemical features strongly point to EC as the potential cause, imaging to localise the EC source may be appropriate, before deciding if IPSS is still indicated.

Magnetic resonance imaging

Dynamic contrast-enhanced (DCE) thin section (3 mm) T1-weighted (T1 W) MRI is the imaging technique of choice for diagnosing pituitary microadenomas. The evaluation of areas of differential enhancement within the pituitary gland, following the administration of a gadolinium-based contrast agent, allows for improved diagnostic accuracy of small lesions. Section-selective T1 W turbo spin echo (TSE) sequences are compared before and at multiple time points after the administration of contrast.⁷ Imaging is usually performed in a coronal plane, but sensitivity is increased by employing a combination of sagittal and coronal planes.^{8,9} Conventional T1 W and T2 W SE sequences in combination with DCE T1 W detect the microadenoma in approximately 70% of cases and improve on sensitivity in comparison with conventional MRI alone.^{10,11} Limitations of DCE scanning include difficulty in distinguishing between a simple cyst and a microadenoma as well as the non-standardised dynamic image acquisition time frame.⁷ In our patient, utilising DCE, a vague 5 mm hypodensity in the right pituitary could be demonstrated.

High dose dexamethasone suppression test

HDDST is a simple and non-invasive test that can be performed without sophisticated equipment or expertise. When compared directly, at similar specificities of nearly 100% each, the 8 mg overnight dexamethasone suppression test has a sensitivity of 71% compared with 65% for the prolonged high-dose dexamethasone suppression test.^{12,13} Due to the better sensitivity, simplicity and shorter duration, the overnight test should be the preferred test. Unfortunately, oral dexamethasone is no longer registered for in use in South Africa and is only obtainable on a patient-named basis through the Medicines Control Council. To our knowledge there are no studies comparing dexamethasone and betamethasone in this context. However, betamethasone has been previously shown to have a similar traditional pharmacokinetic and potency profile to dexamethasone and, as such, is deemed to be a suitable alternative to dexamethasone.¹⁴

It is accepted that a small proportion of pituitary adenomas do not suppress whilst a proportion of ectopic ACTH-producing tumours can exhibit a degree of suppression with HDDST. Various cut-off values to predict PC have been proposed, ranging from 50–80% suppression of serum cortisol from baseline.¹ It is evident that specificity is enhanced (at the expense of sensitivity) by increasing the cut-off percentage value for suppression. There is uncertainty as to the optimal cut-off value and opinions vary regarding the usefulness of this test.¹⁵ However, the role of HDDST in the proposed approach is not to act as a single diagnostic test, but rather to rule in PC in concordance with MRI findings (and ACTH stimulation) and therefore avoid invasive IPSS prior to pituitary surgery. At our centre we use a cut-off value of greater than 68% suppression of serum cortisol, which has been shown to translate into a specificity of nearly 100%.¹³ In our patient, serum cortisol was suppressed by 89% on HDDST, which strongly suggests PC.

CRH and DDAVP stimulation tests

The CRH stimulation test has been extensively studied using various cut-off criteria of either increments of ACTH or cortisol, various doses of CRH, varying time intervals of sampling, as well

as using either human or ovine CRH. With sensitivities and specificities reported in the range of 90%, this test is the most accurate non-invasive test. There is, however, no consensus with regard to optimal methodology and diagnostic criteria for this test.^{6,16} Furthermore, CRH is not freely available in South Africa and is only obtainable at great cost and effort. As such, the CRH stimulation test, although useful, has limited application in our setting.

Receptors for vasopressin (AVP) are found on corticotrophs. Although initial studies indicated DDAVP stimulation to be useful in differentiating pituitary from ectopic ACTH overproduction, it has been shown that many ectopic sources also express vasopressin receptors, and may respond to DDAVP stimulation. Thus, when used in isolation, the DDAVP stimulation test performs poorly in differentiating ectopic from pituitary ACTH production.¹⁷ However, DDAVP is freely available in South Africa and a concordant DDAVP test adds to diagnostic accuracy for PC when used in combination with other positive tests.¹⁸ As our patient did not demonstrate a more than 6 mm pituitary lesion on MRI, which was discordant with the pronounced pituitary localisation on HDDST, we proceeded to perform IPSS without a DDAVP stimulation test. If MRI and HDDST are discordant (as was the case in our patient), IPSS is inevitable and a DDAVP stimulation test before proceeding to IPSS will add no further diagnostic value.

Inferior petrosal sinus sampling

Data from multiple studies estimates specificity for PC at 90–95%, when a central inferior petrosal sinus (IPS) to peripheral ACTH ratio of greater than 2:1 is used to localise the source.⁵ Sensitivity of IPSS for PC has been reported with much greater variability (54–96%), but most studies report sensitivities well above 80%.⁵ Our patient had a ratio of 12:1 from the right IPS, which far exceeds this diagnostic threshold and confirms PC. Of note, samples taken from the left IPS showed ACTH concentrations equal to peripheral blood, at a ratio of 1:1 (see below).

CRH stimulation has been shown to exaggerate the central to peripheral ACTH ratio. By using a ratio of greater than 3:1 with CRH stimulation during IPSS, most studies report an increased accuracy, especially with regard to an improvement in the sensitivity to 81–100%.⁵ However, as discussed earlier, CRH is largely unobtainable in South Africa.

More recently DDAVP stimulation during IPSS has been utilised with comparable enhancement of diagnostic accuracy, as seen with CRH stimulation using the same central to peripheral ratio of 3:1. A sensitivity of 92–95% and specificity of 100% have been reported in two case series.^{19,20} Although side effects are rare, DDAVP administration does have the potential for vasoconstriction, hyponatraemia and haemostatic effects for which patients should be observed after the procedure.⁵ Due to the invasive nature of IPSS, diagnostic accuracy should be enhanced in every feasible way and, as such, DDAVP is a suitable alternative to CRH in the South African setting during IPSS. In our patient the central to peripheral ACTH ratio in the right catheter doubled to 24:1 after 10 mcg DDAVP IV administration.

IPSS is a technically demanding procedure fraught with possible error. Despite confirming correct anatomical placement radiologically before the procedure, sampling from the inferior petrosal sinuses may not be accurate. Various factors may contribute such as displacement of catheters during sampling, uneven rate of sampling between left and right (blood may be shunted away from one side to the other if aspiration is done too

vigorously) or anomalous venous drainage of non-pituitary blood to the IPS.^{21,22} If any of these factors is present, it is unlikely to be noted during the sampling procedure.

Prolactin measurements during IPSS have recently been introduced to overcome the uncertainty as to whether IPS blood was accurately sampled, in cases where IPSS does not confirm a pituitary source of ACTH overproduction. Although prolactin measurements cannot confirm correct sampling timeously during the procedure, analysis post-hoc avoids unnecessary investigation for an ectopic source of ACTH production in such cases. If blood sampled from one or both IPS does not show an elevated prolactin level compared with peripheral blood, it may be assumed that the IPS was not accurately sampled and IPSS may need to be repeated. A central to peripheral prolactin ratio of greater than 1.8:1 is considered to indicate appropriate IPSS.²³⁻²⁷ In our case the central to peripheral IPS prolactin ratio at baseline was 1:1 in the left compared with 3:1 for the right IPS. This signifies that the left IPS essentially sampled peripheral blood. This explains the low peripheral to left ACTH ratio, and invalidates all results from the left IPS.

Another use of prolactin measurement during IPSS (with or without CRH or DDAVP stimulation) is correcting ACTH levels for prolactin where ACTH levels alone were not convincingly diagnostic. Blood sampled from the IPS may be diluted by blood draining from sites other than the pituitary and therefore disturb the central to peripheral ACTH ratio. However, it can be assumed that a proportionate dilution will also occur with prolactin measurement. Prolactin can therefore be used to 'correct' ACTH for this dilutional effect. Prolactin-corrected ACTH peripheral to IPS ratios are determined by the highest ACTH central to peripheral ratio divided by the concurrent and ipsilateral prolactin central to peripheral ratio. A prolactin-corrected ACTH central to peripheral ratio of greater than 1.2:1 is diagnostic of PC.²⁸ Using the prolactin correction additional cases of PC could be correctly detected, without decreasing the specificity.²³⁻²⁷ This may avoid an unnecessary repeat of IPSS.

In PC, IPSS lateralisation of a microadenoma to either the left or right pituitary remains almost equal to chance, despite stimulation with either DDAVP or CRH.^{5,19} It has, however, been shown that correction of ACTH ratios for prolactin improves the accuracy of localisation.^{27,28} Right and left ACTH levels are corrected for prolactin levels by dividing the ACTH level by the ipsilateral and concurrent prolactin value. If the ratio of these prolactin-corrected ACTH values between right and left IPSS is greater than 1.4:1, the source may be lateralised accurately in 75-77% of cases, and 82-100% when lateralisation on MRI is concordant.^{27,28} Although preoperative lateralisation does not substitute for intraoperative visualisation of the tumour by the surgeon, it does assist in minimising exploration and pituitary damage if a probable site of the tumour is determined beforehand.

Localisation of an ectopic source of ACTH production

Multiple imaging modalities are available to evaluate the source of EC, if appropriately performed IPSS and its interpretation suggests a non-pituitary source of ACTH production. Recently a large systematic review was published on this topic.²⁹ Key findings were that in more than half of the cases of EC the disease was overt and detectable by conventional radiology alone (whole-body computerised tomography [CT] and MRI). However, both false positives and negatives occurred, using conventional radiology. It is therefore recommended that should a tissue

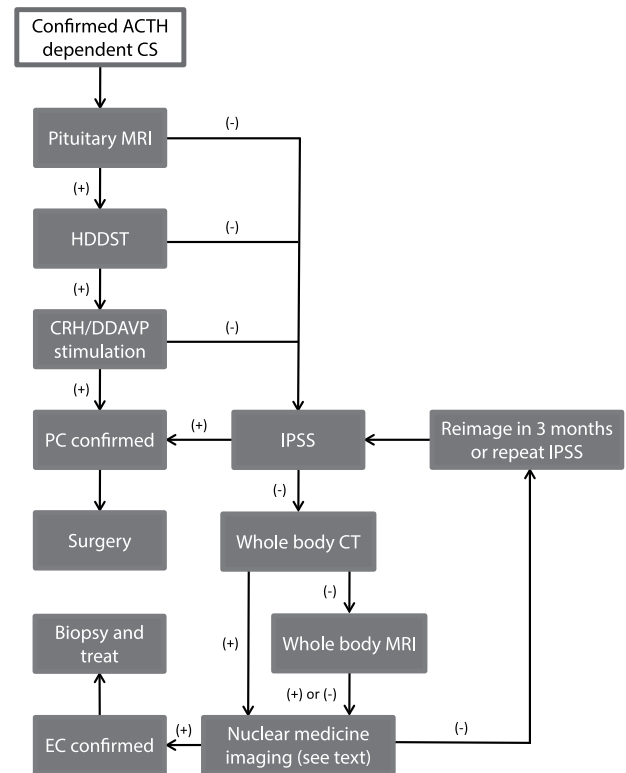


Figure 1: Suggested approach to the diagnostic workup of ACTH-dependent Cushing's syndrome.

diagnosis not be confirmatory after localisation with conventional radiology, nuclear medicine imaging should ensue: either somatostatin receptor imaging (e.g.^{99m}Tc-HYNIC octreotide SPECT/CT; ⁶⁸Ga-DOTANOC PET/CT); or using a glucose analogue — ¹⁸F-fluorodeoxyglucose (FDG) PET/CT. Imaging of amino acid metabolism with ¹⁸F-DOPA PET/CT may also be considered where available.

For covert disease where both MRI and CT scan failed to detect the source of EC, PET/CT using ⁶⁸Ga-DOTA-labelled octreotide analogues had the best sensitivity of close to 100%. This modality has recently become available in the public sector in South Africa and is a valuable tool in this context. It is also cheaper than comparable SPECT agents. It must, however, be highlighted that when used as a first-line test for locating the source of any EC (including overt disease), Gallium PET/CT performed inferiorly compared with conventional radiology. Therefore Gallium PET/CT should ideally only be utilised after CT or MRI, either to confirm a lesion detected on either of these modalities, or as a second- (or third-) tier investigation to confirm an abnormal finding, when doubt remains after anatomical imaging. It should also be noted that in more than 18% of cases of EC, the source will remain occult, despite utilising multiple imaging modalities. In such cases periodic reimaging should follow or the diagnosis of PC should be reconsidered.

An algorithm for the work-up of ACTH-dependent CS is suggested in Figure 1. However, many factors may influence the decision on the most appropriate modalities to be used including the patient's clinical condition and presentation, local availability of nuclear medicine imaging techniques and cost. Decisions should be preferably be made by a multidisciplinary team consisting of endocrinologists, radiologists, nuclear medicine physicians and neurosurgeons.

Conclusion

This case illustrates some of the difficulties in the diagnosis of ACTH-dependent CS. Despite the low availability of CRH in South Africa, we are still able to utilise many of the most modern diagnostic approaches, including DCE-MRI, IPSS with ACTH and prolactin sampling and DDAVP stimulation. More recently, locally available nuclear medicine techniques (such as PET/CT with ⁶⁸Ga-DOTANOC or equivalent) now allow covert, complicated cases of ACTH-dependent CS to be confidently and competently managed in South Africa.

Returning to our patient: at surgery a microadenoma was removed from the right side of the pituitary, which stained strongly for ACTH. However, following the surgery there was no clinical or biochemical evidence of cure. A second, more aggressive, transsphenoidal resection was performed. On follow-up she lost 20 kg in mass was normotensive and euglycaemic off all medication, and suppressed to 58 nmol/L on a betamethasone suppression test.

Acknowledgment – Dr Elmo Pretorius is a fellow in endocrinology and metabolism made possible by the Society for Endocrinology, Metabolism and Diabetes of South Africa (SEMDSA).

References

1. Arnaldi G, Angeli A, Atkinson A, et al. Diagnosis and complications of Cushing's syndrome: a consensus statement. *J Clin Endocrinol Metab.* 2003;88(12):5593–602. <http://dx.doi.org/10.1210/jc.2003-030871>
2. Molitch ME. Nonfunctioning pituitary tumors and pituitary incidentalomas. *Endocrinol Metab Clin North Am.* 2008;37(1):151–71. <http://dx.doi.org/10.1016/j.ecl.2007.10.011>
3. Ilias I, Torpy DJ, Pacak K, et al. Cushing's syndrome due to ectopic corticotropin secretion: twenty years' experience at the national institutes of health. *J Clin Endocrinol Metab.* 2005;90(8):4955–62. <http://dx.doi.org/10.1210/jc.2004-2527>
4. Lacroix A, Feelders RA, Stratakis CA, et al. Cushing's syndrome. *Lancet.* 2015;386(9996):913–27. doi: 10.1016/S0140-6736(14)61375-1.
5. Giraldi FP, Cavallo LM, Tortora F, et al. The role of inferior petrosal sinus sampling in ACTH-dependent Cushing's syndrome: review and joint opinion statement by members of the Italian Society for Endocrinology, Italian Society for Neurosurgery, and Italian Society for Neuroradiology. *Neurosurg Focus.* 2015;38(2):E5. <http://dx.doi.org/10.3171/2014.11.FOCUS14766>
6. Boscaro M, Arnaldi G. Approach to the patient with possible Cushing's syndrome. *J Clin Endocrinol Metab.* 2009;94(9):3121–31. <http://dx.doi.org/10.1210/jc.2009-0612>
7. Rossi Espagnet MC, Bangiyev L, Haber M, et al. High-resolution DCE-MRI of the pituitary gland using radial k-space acquisition with compressed sensing reconstruction. *AJNR Am J Neuroradiol.* 2015;36(8):1444–9. <http://dx.doi.org/10.3174/ajnr.A4324>
8. Gao R, Isoda H, Tanaka T, et al. Dynamic gadolinium-enhanced MR imaging of pituitary adenomas: usefulness of sequential sagittal and coronal plane images. *Eur J Radiol.* 2001;39(3):139–46. [http://dx.doi.org/10.1016/S0720-048X\(01\)00354-0](http://dx.doi.org/10.1016/S0720-048X(01)00354-0)
9. Lee HB, Kim ST, Kim H, et al. Usefulness of the dynamic gadolinium-enhanced magnetic resonance imaging with simultaneous acquisition of coronal and sagittal planes for detection of pituitary microadenomas. *Eur Radiol.* 2012;22(3):514–8. <http://dx.doi.org/10.1007/s00330-011-2291-3>
10. Tabarin A, Laurent F, Catargi B, et al. Comparative evaluation of conventional and dynamic magnetic resonance imaging of the pituitary gland for the diagnosis of Cushing's disease. *Clin Endocrinol.* 1998;49(3):293–300. <http://dx.doi.org/10.1046/j.1365-2265.1998.00541.x>
11. Farabola M, Bettinelli A, Resta F, et al. Clinical value of dynamic MRI in the diagnosis of pituitary microadenoma. *Rivista di Neuroradiologia.* 1997;10(1):17–28.
12. Orth DN. Cushing's syndrome. *N Engl J Med.* 1995;332(12):791–803. <http://dx.doi.org/10.1056/NEJM199503233321207>
13. Dichek HL, Nieman LK, Oldfield EH, et al. A comparison of the standard high dose dexamethasone suppression test and the overnight 8-mg dexamethasone suppression test for the differential diagnosis of adrenocorticotropin-dependent Cushing's syndrome. *J Clin Endocrinol Metab.* 1994;78(2):418–22.
14. Buttgerit F, Brand MD, Burmester G. Equivalent doses and relative drug potencies for non-genomic glucocorticoid effects: a novel glucocorticoid hierarchy. *Biochem Pharmacol.* 1999;58(2):363–8. [http://dx.doi.org/10.1016/S0006-2952\(99\)00090-8](http://dx.doi.org/10.1016/S0006-2952(99)00090-8)
15. Aron DC, Raff H, Findling JW. Effectiveness versus efficacy: The limited value in clinical practice of high dose dexamethasone suppression testing in the differential diagnosis of adrenocorticotropin-dependent Cushing's syndrome. *J Clin Endocrinol Metab.* 1997;82(6):1780–5.
16. Reimondo G, Paccotti P, Minetto M, et al. The corticotrophin-releasing hormone test is the most reliable noninvasive method to differentiate pituitary from ectopic ACTH secretion in Cushing's syndrome. *Clin Endocrinol.* 2003;58(6):718–24. <http://dx.doi.org/10.1046/j.1365-2265.2003.01776.x>
17. Tsigarakis S, Tsigos C, Vasilioi V, et al. The desmopressin and combined CRH-desmopressin tests in the differential diagnosis of ACTH-dependent Cushing's syndrome: constraints imposed by the expression of V2 vasopressin receptors in tumors with ectopic ACTH secretion. *J Clin Endocrinol Metab.* 2002;87(4):1646–53.
18. Testa RM, Albiger N, Occhi G, et al. The usefulness of combined biochemical tests in the diagnosis of Cushing's disease with negative pituitary magnetic resonance imaging. *Eur J Endocrinol.* 2007;156(2):241–8. <http://dx.doi.org/10.1530/eje.1.02332>
19. Castinetti F, Morangel H, Dufour H, et al. Desmopressin test during petrosal sinus sampling: a valuable tool to discriminate pituitary or ectopic ACTH-dependent Cushing's syndrome. *Eur J Endocrinol.* 2007;157(3):271–7. <http://dx.doi.org/10.1530/EJE-07-0215>
20. Machado MC, De Sa SV, Domesice S, et al. The role of desmopressin in bilateral and simultaneous inferior petrosal sinus sampling for differential diagnosis of ACTH-dependent Cushing's syndrome. *Clin Endocrinol.* 2007;66(1):136–42.
21. Lefournier V, Martinie M, Vasdev A, et al. Accuracy of bilateral inferior petrosal or cavernous sinus sampling in predicting the lateralization of Cushing's disease pituitary microadenoma: influence of catheter position and anatomy of venous drainage. *J Clin Endocrinol Metab.* 2003;88(1):196–203. <http://dx.doi.org/10.1210/jc.2002-020374>
22. Swearingen B, Katznelson L, Miller K, et al. Diagnostic errors after inferior petrosal sinus sampling. *J Clin Endocrinol Metab.* 2004;89(8):3752–63. <http://dx.doi.org/10.1210/jc.2003-032249>
23. Sharma S, Raff H, Nieman L. Prolactin as a marker of successful catheterization during IPSS in patients with ACTH-dependent Cushing's syndrome. *J Clin Endocrinol Metab.* 2011;96(12):3687–94. <http://dx.doi.org/10.1210/jc.2011-2149>
24. Daousi C, Nixon T, Javadpour M, et al. Inferior petrosal sinus ACTH and prolactin responses to CRH in ACTH-dependent Cushing's syndrome: a single centre experience from the United Kingdom. *Pituitary.* 2010;13(2):95–104. <http://dx.doi.org/10.1007/s11102-009-0200-4>
25. Findling JW, Kehoe ME, Raff H. Identification of patients with Cushing's disease with negative pituitary adrenocorticotropin gradients during inferior petrosal sinus sampling: prolactin as an index of pituitary venous effluent. *J Clin Endocrinol Metab.* 2004;89(12):6005–9. <http://dx.doi.org/10.1210/jc.2004-1378>
26. Mulligan G, Eray E, Fairman C. Inferior petrosal sinus sampling: Simultaneous prolactin and ACTH measurement can reduce false-negative results. *Endocr Pract.* 2010;17:33–40.
27. Qiao X, Ye H, Zhang X, et al. The value of prolactin in inferior petrosal sinus sampling with desmopressin stimulation in Cushing's disease. *Endocrine.* 2015;48(2):644–52. <http://dx.doi.org/10.1007/s12020-014-0338-3>
28. Mulligan GB, Fairman C, Gupta M, et al. Prolactin measurement during inferior petrosal sinus sampling improves the localization of pituitary adenomas in Cushing's disease. *Clin Endocrinol.* 2012;77(2):268–74. <http://dx.doi.org/10.1111/cen.12177.issue-2>
29. Isidori AM, Sbardella E, Zatelli MC, et al. Conventional and nuclear medicine imaging in ectopic Cushing's syndrome: a systematic review. *J Clin Endocrinol Metab.* 2015;100(9):3231–44. <http://dx.doi.org/10.1210/JC.2015-1589>

Received: 29-02-2016 Accepted: 12-07-2016