



Effects of Aqueous Rhizome Extract of *Zingiber officinale* on Arsenic Trioxide-Induced Spleen Damage in Adult Wistar Rats

¹Imafidon, E.O. and ¹Ezekiel, B.A.

Abstract

BACKGROUND AND AIM: Arsenic trioxide induces significant spleen toxicity, causing splenomegaly, oxidative stress, inflammation, and compromised immune responses, which can lead to infections, impaired blood filtration, and systemic health decline. *Zingiber officinale*, known for its anti-inflammatory, antioxidant, and anti-carcinogenic properties, shows potential in mitigating toxicity and oxidative stress. This study aimed to assess the effects of aqueous rhizome extract of *Zingiber officinale* on arsenic trioxide-induced spleen damage in adult Wistar rats.

METHODOLOGY: Thirty (30) adult Wistar rats (n=5) were randomly assigned into six groups (A-F). Group A served as control; Group B - 10 mg/kg As₂O₃ only; Group C - 190 mg/kg body weight of *Zingiber officinale* stem extract and 10 mg/kg As₂O₃; Group D - 380 mg/kg body weight of *Zingiber officinale* stem extract and 10 mg/kg As₂O₃; Group E - 50 mg/kg body weight of standard drug (silymarin) and 10 mg/kg As₂O₃. Group F - 380 mg/kg body weight of *Zingiber officinale* stem extract.

RESULTS: Results of haematological parameters showed no significant difference (p>0.05) across groups. The arsenic trioxide-only group had significantly decreased glutathione, catalase, and superoxide dismutase, and increased malondialdehyde levels (p<0.05) compared to control. Pre-treatment with *Zingiber officinale* and silymarin significantly improved these markers (p<0.05). Histologically, arsenic trioxide caused severe spleen damage, while pre-treatment with *Zingiber officinale* and silymarin showed marked improvement. In conclusion,

CONCLUSION: Taken together, these findings provide evidence that *Zingiber officinale* protects against arsenic trioxide-induced spleen damage in Wistar rats.

Keywords:

Arsenic trioxide, Spleen damage, *Zingiber officinale*, Wistar rat.

Submitted: 11th April, 2024

Revised: 12th June, 2024

Accepted: 21st June, 2024

Published: 30th June, 2024

¹Department of Anatomy, School of Basic Medical Sciences, University of Benin, Edo State, Nigeria.

Address for Correspondence:

Imafidon, E.O.

Department of Anatomy, School of Basic Medical Sciences, University of Benin, Edo State, Nigeria.

endurance.imafidon@uniben.edu

INTRODUCTION

Arsenic, a naturally occurring metalloid, is ubiquitously present in the environment, primarily due to both natural geological processes and anthropogenic activities (Polya and Lawson, 2015; Khan and Flora, 2023). Despite its industrial and agricultural utility, arsenic exposure poses significant public health risks. In many regions, arsenic contamination of groundwater is a critical issue, affecting millions of people (Shaji *et al.*, 2021). Arsenic exposure, whether through contaminated drinking water, food, or air, leads to an array of adverse health effects. Chronic arsenic exposure is particularly insidious, with long-term ingestion associated with various cancers, cardiovascular

diseases, diabetes, and neurotoxicity (Garcia-Vargas and Cebrian, 2023; Hashim, 2023). One of the least-discussed, yet critical impacts of arsenic toxicity, is its effect on the spleen. The spleen, an essential organ in the lymphatic system, plays a vital role in filtering blood, recycling old red blood cells, and supporting immune function (Lewis *et al.*, 2019; Al-Salem, 2023). Arsenic trioxide, a specific form of arsenic, has been documented to induce significant spleen toxicity (Duan *et al.*, 2017). This manifests as splenomegaly (enlarged spleen), oxidative stress, inflammation, and compromised immune responses (Colamartino *et al.*, 2015; Dugo *et al.*, 2017; Paithankar *et al.*, 2021; Akbari

This is an open access journal, and articles are distributed under the terms of the Creative Commons Attribution-Non Commercial-Share Alike 4.0 License, which allows others to remix, tweak, and build upon the work non-commercially, as long as appropriate credit is given and the new creations are licensed under the identical terms.

How to cite this article: Imafidon, E.O. and Ezekiel, B.A. Effects of Aqueous Rhizome Extract of *Zingiber officinale* on Arsenic Trioxide-Induced Spleen Damage in Adult Wistar Rats. *J Exp Clin Anat* 2024; 21(1):110-116. <https://dx.doi.org/10.4314/jeca.v21i1.17>

For reprints contact: jecajournal@gmail.com

et al., 2022). Given the spleen's crucial functions, its impairment due to arsenic toxicity can lead to heightened susceptibility to infections, impaired blood filtration, and overall systemic health decline (Kile *et al.*, 2016; Dugo *et al.*, 2017; Alvaro *et al.*, 2021).

In the search for remedies to counteract arsenic toxicity, medicinal plants have garnered substantial attention. Historically, plants have been a cornerstone in the management and treatment of various ailments due to their bioactive compounds, which exhibit antioxidant, anti-inflammatory, and detoxifying properties. Utilising medicinal plants presents a promising, natural alternative to synthetic drugs, which may have their own set of adverse effects. Among the myriad of medicinal plants, *Zingiber officinale* stands out for its potent therapeutic properties. *Zingiber officinale* has been used for centuries in traditional medicine systems such as Ayurveda, Traditional Chinese Medicine, and Unani (Shahrajabian *et al.*, 2019; Li *et al.*, 2022). It is renowned for its bioactive compounds, including gingerols, shogaols, and paradols (Dhanik *et al.*, 2017), which confer its strong anti-inflammatory (Ezzat *et al.*, 2018), antioxidant, and anti-carcinogenic properties (Dissanayake *et al.*, 2020). Studies have demonstrated *Zingiber officinale's* efficacy in mitigating various forms of toxicity and oxidative stress in biological systems. Its potential to counteract arsenic-induced spleen toxicity lies in its ability to enhance antioxidant defenses, reduce inflammation, and modulate immune responses. Thus, this study is aimed at assessing the effects of aqueous rhizome extract of *Zingiber officinale* against arsenic trioxide-induced spleen damage in Wistar rats.

MATERIALS AND METHODS

Plant Extract: Ginger stems were obtained from a nearby farm. It was identified, and authenticated at the herbarium (UBH-Z384) of the Department of Plant Biology and Biotechnology, University of Benin, Nigeria. The stems were carefully sorted to remove damaged ones, they were washed, cleaned, and air-dried. Thereafter, it was put into one litre of beaker after being pulverized into a fine powder (500g) with a mechanical grinder and weighed with an electrical weighing balance. The ground plant materials were prepared for aqueous extraction according to the method described by Ikegwu *et al.* (2010).

Experimental Animals: Wistar rats were procured and bred in the Animal House, Department of Anatomy, University of Benin, Benin City, Edo State, Nigeria. The rats were acclimatized for 2 weeks before the commencement of administration and the animals were fed with standard chow and clean water *ad libitum*. The study was approved by the Research Ethical Committee of the College of Medical Sciences, University of Benin with the approval number CMS/REC/2023/339.

Experimental Design: Thirty (30) adult Wistar rats weighing between 110 g and 200 g were randomly assigned into six (6) groups of five (5) rats each. Group A – Control; Group B - 10 mg/kg As₂O₃ only; Group C - 190 mg/kg body weight of *Zingiber officinale* rhizome extract and 10 mg/kg As₂O₃; Group D - 380 mg/kg body weight of *Zingiber officinale* stem extract and 10 mg/kg As₂O₃; Group E - 50 mg/kg body weight of standard drug (silymarin) and 10 mg/kg As₂O₃. Group F - 380 mg/kg body weight of *Zingiber officinale* stem extract. The administration lasted for 28 days and was done orally using an orogastric tube.

Sample collection and Assessments: At the end of the treatment period (28 days), the rats were weighed and then sacrificed under chloroform anaesthesia. Blood samples were collected into EDTA anticoagulant sample bottles for haematological assessment and the spleen was harvested and immediately fixed on 10% formalin to avoid autolysis and used for histological assessments. Evaluation of antioxidant enzyme activity was carried out as previously described; catalase (CAT) [Cohen *et al.*, 1970]; glutathione (GSH) [Nyman 1959]; Superoxide dismutase (SOD) [Misra and Fridovich 1972]. Also, lipid peroxidation assessment was carried out as previously described; Malondialdehyde (MDA) [Buege and Aust, 1978]. The harvested spleen tissues were processed and routinely stained using hematoxylin and eosin, according to the method previously reported by Drury and Wallington (1980).

RESULTS

Effect of Treatment on Hematological Indices: Table 1 shows the effect of treatment on haematological indices. Results showed that there was no significant difference ($p>0.05$) in platelets, haematocrit, WBC, lymphocytes and granulocytes across the experimental groups.

Effect of Treatment on Oxidative Stress: Table 2 shows the effect of treatment on oxidative stress markers. Results showed that there was a significant decrease ($p<0.05$) in glutathione (GSH), catalase (CAT) and superoxide dismutase (SOD) levels and a significant increase ($p<0.05$) in malondialdehyde (MDA) concentration in Arsenic trioxide-only treated rats when compared to control. However, there was a significant increase ($p<0.05$) in GSH, CAT and SOD and a significant decrease ($p<0.05$) in MDA concentration in Arsenic trioxide exposed rats pretreated with *Zingiber officinale*, and Silymarin.

Effect of Treatment on the Histology of the Spleen: Histological plates (Plate 1-6) below show the histology of the spleen throughout the experimental groups. Normal spleen tissue architecture was observed in the control and *Zingiber officinale*-only groups (Plate 1 and 6 respectively). In contrast, arsenic trioxide-only treated rats (Plate 2) showed severe damage to the spleen. Arsenic trioxide-treated rats pretreatment with *Zingiber officinale* and Silymarin (Plates 3, 4, and 5) showed relatively normal spleen histology.

Table 1: showing hematological indices of the experimental animals.

	Control	10g/kg As ₂ O ₃ only	190mg/kg <i>Zingiber officinale</i> + 10mg/kg As ₂ O ₃	380 mg/kg <i>Zingiber officinale</i> + 10 mg/kg As ₂ O ₃	50 mg/kg Silymarin + 10mg/kg As ₂ O ₃	380mg/kg <i>Zingiber officinale</i>	P-value
Platelets (10³/μL)	582.500±57.710	535.250±135.789	653.000±85.772	959.500±109.500	597.800±122.610	715.000±49.825	0.256
Haematocrit (%)	40.125 ±1.674	28.325 ±6.825	36.300 ±0.183	31.600 ±1.200	32.940 ±3.358	36.180 ±0.667	0.254
WBC (10³/μL)	9.775 ±1.423	7.625 ±2.429	10.375 ±1.162	9.700 ±0.200	10.040 ±0.676	9.120 ±1.041	0.776
Lymphocytes (%)	93.850 ±1.012	88.425 ±5.823	94.800 ±0.576	92.400 ±0.800	92.74 ±1.425	93.840 ±0.308	0.570
Granulocytes (%)	1.875 ±0.810	4.825 ±3.273	1.850 ±0.603	1.600 ±0.100	2.120 ±0.897	1.460 ±0.117	0.613

Values are given as mean ±SEM.

Table 2: showing antioxidant enzyme activity (GSH, SOD, CAT) and lipid peroxidation (MDA) in the spleen of the experimental animals.

	Control	10g/kg As ₂ O ₃ only	190mg/kg <i>Zingiber officinale</i> + 10mg/kg As ₂ O ₃	380 mg/kg <i>Zingiber officinale</i> + 10 mg/kg As ₂ O ₃	50 mg/kg Silymarin + 10mg/kg As ₂ O ₃	380mg/kg <i>Zingiber officinale</i>	P-value
GSH (μM)	55.8775±0.356	28.371±1.241*	37.698±2.704#	46.637±3.628#	43.942±2.567#	37.516±0.744	0.012
SOD (U/L)	96.659±0.022	93.383±0.309*	95.015±0.332#	95.973±0.314#	95.973±0.314#	95.666±0.271	0.020
CAT (U/L)	0.049±0.001	0.031±0.002*	0.042±0.003#	0.041±0.004#	0.046±0.004#	0.048±0.001	0.010
MDA (μM)	0.799±0.40	2.632±0.109*	1.336±0.153#	0.867±0.106#	0.964±0.031#	1.040±0.055	0.003

Values are given as mean ±SEM. * p<0.05 (significantly different) compared with the control group; # p<0.05 (significantly different) compared to the Arsenic trioxide-only group.

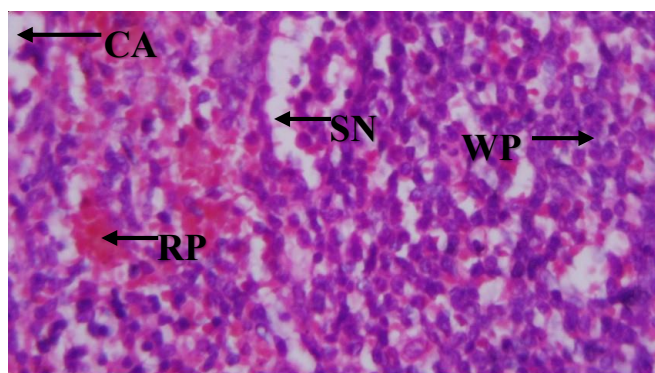


Plate 1: Rat Spleen. Control. Composed of normal tissue architecture: capsule (CA), red pulp (RP), white pulp (WP), sinuses (SN), arteriole (AR): [H&E x 400].

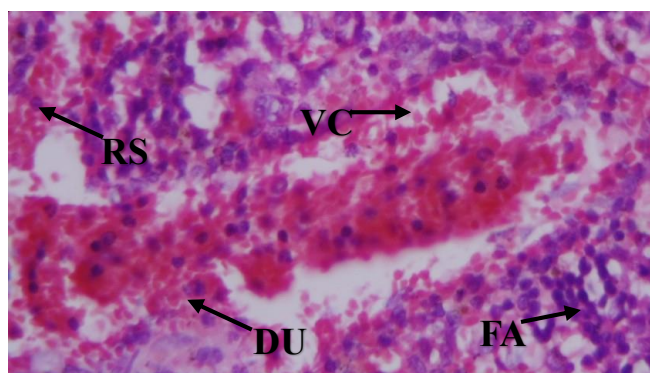


Plate 2: Rat spleen given arsenic trioxide (10mg/kg) only showing: severe vascular congestion (VC), severe vascular dilatation and ulceration (DU), marked red cell sequestration (RS), follicular atrophy (FA): [H&E x 400].

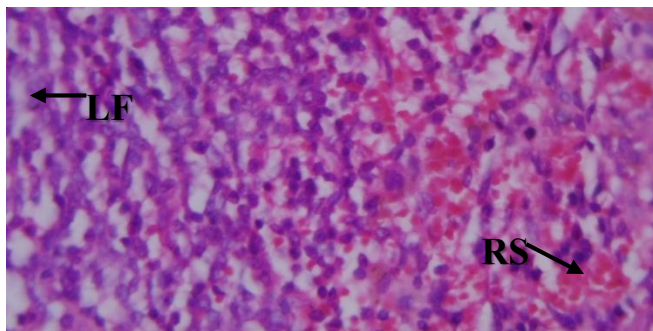


Plate 3. Rat spleen given *Zingiber officinale* (190mg/kg) + 10mg/kg arsenic showing: normal lymphoid follicles (LF), marked red cell sequestration (RS): [H&E x 400].

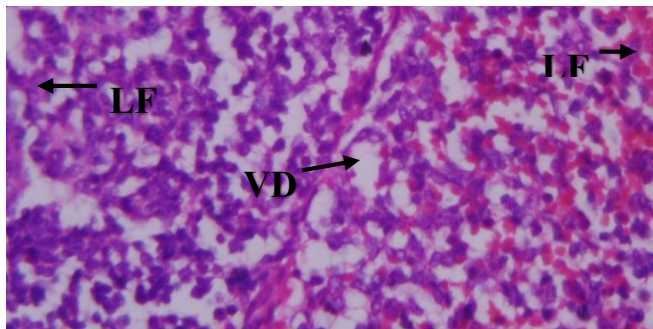


Plate 4: Rat spleen given *Zingiber officinale* (380mg/kg) + arsenic trioxide (10mg/Kg) showing: normal lymphoid follicles (LF), sinus dilatation (VD), increased red cell sequestration (RS): [H&E x 400].

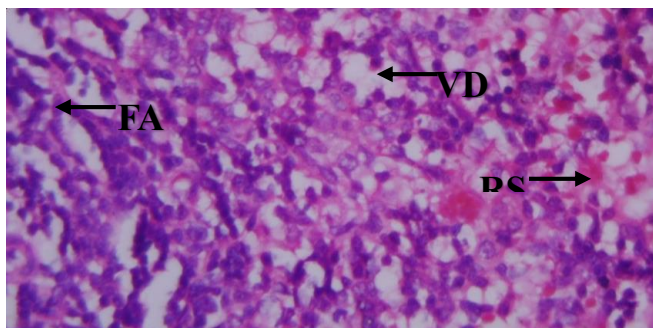


Plate 5. Rat spleen given arsenic trioxide (10mg/kg) + Silymarin (50mg/kg) showing: increased red cell sequestration (RS), sinus dilatation (VD), follicular atrophy (FA): [H&E x 400]

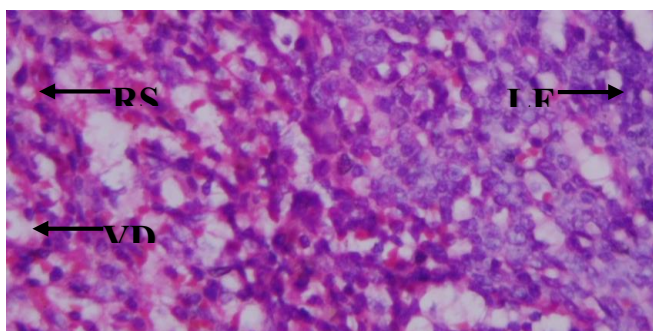


Plate 6: Rat spleen given *Zingiber officinale* (380 mg/Kg) only showing: normal Lymphoid follicle (LF), moderate red cell sequestration (RS), vasodilatation (VD): [H&E x 400]

DISCUSSION

A plethora of studies corroborate the induction of oxidative stress (Shahid *et al.*, 2020; Byeon *et al.*, 2021; Zulfiqar and Ashraf, 2022) and haematological toxicity (Shah *et al.*, 2020; Raeeszadeh *et al.*, 2022) as a consequence of arsenic exposure, shedding light on its deleterious effects on blood parameters. Although the findings of this study showed no statistical significance ($P > 0.05$), a notable upward trend in platelet counts was observed following the administration of *Zingiber officinale*, especially at the higher dose of 380 mg/kg. Platelets are essential for blood clotting and wound healing (Shariati *et al.*, 2020); a reduction in platelets (thrombocytopenia) can increase bleeding risk (Alvaro *et al.*, 2021), while an increase suggests a protective effect against arsenic trioxide-induced thrombocytopenia. This rise in platelet levels indicates a potential prophylactic capacity of *Zingiber officinale* to counteract the thrombocytopenic effects induced by arsenic trioxide. This aligns with previous studies that highlight the therapeutic attributes of *Zingiber officinale* in ameliorating platelet dysregulation (Zarei *et al.*, 2021; Angelopoulou *et al.*, 2022). The observation is also consistent with studies demonstrating that antioxidant-rich compounds can mitigate platelet depletion caused by toxic substances (Gu and Dayal, 2022; Jomova *et al.*, 2024). Hematocrit values, which measure the proportion of red blood cells (RBCs) in the blood (Kishimoto *et al.*, 2020), significantly decreased with arsenic trioxide exposure, indicating anaemia. Anaemia is commonly associated with oxidative stress and toxicity, leading to reduced oxygen transport capacity in the blood and resulting in fatigue and weakness. This aligns with findings from previous studies, which also noted anaemia as a common consequence of arsenic toxicity (Kile *et al.*, 2016). However, treatments with *Zingiber officinale* exhibited improvements in hematocrit levels. Although these results were not statistically significant, they suggest that *Zingiber officinale* may mitigate arsenic trioxide-induced anaemia. White blood cell (WBC) counts, an indicator of immune function (Chabot-Richards and George, 2015), were slightly reduced with arsenic trioxide exposure, indicating immune suppression. WBCs play a vital role in defending the body against infections. A reduction in WBC count can compromise the immune system, making the individual more susceptible to infections. Treatment with *Zingiber officinale* and Silymarin showed a recovery towards control levels, especially with 190 mg/kg of *Zingiber officinale*. This indicates a possible protective effect against immune suppression induced by arsenic, consistent with previous studies where antioxidant therapies improved immune parameters after exposure to heavy metals (El-Boshy *et al.*, 2015; El-Boshy *et al.*, 2017; Mahmoud *et al.*, 2022). Lymphocyte percentages, which are critical for immune response and include T cells and B cells, were reduced in the arsenic trioxide-only group, indicative of lymphotoxicity. Both doses of *Zingiber officinale* showed normalization towards control levels. This suggests *Zingiber officinale's* role in

protecting lymphocyte populations, paralleling findings in other studies that demonstrated herbal remedies' efficacy in safeguarding lymphocytes under oxidative stress conditions (Colamartino *et al.*, 2015; Akbari *et al.*, 2022). Granulocyte percentages, which include neutrophils, eosinophils, and basophils, increased with arsenic trioxide exposure, indicative of an inflammatory response. Granulocytes are part of the innate immune system and their increase often signifies an acute inflammatory or infectious process (Selders *et al.*, 2017; Rosales, 2020). Treatment with *Zingiber officinale*, particularly at higher doses, reduced granulocyte levels back to near control values, demonstrating anti-inflammatory properties. This observation is supported by previous research showing that *Zingiber officinale* possesses strong anti-inflammatory effects, reducing granulocyte activation in response to toxins (Ezzat *et al.*, 2018; Karunakaran and Sadanandan, 2019; Azeez and Lunghar, 2021).

Arsenic exposure often leads to oxidative stress through the generation of free radicals. This form of stress results from an imbalance between the production of reactive oxygen species (ROS) and the cell's capacity to repair damage and detoxify these reactive molecules. Such an imbalance can stem from increased ROS production, reduced antioxidant defenses, or a combination of both. Antioxidants, including enzymes like Superoxide Dismutase (SOD), Catalase (CAT), and Glutathione (GSH), are essential for neutralising free radicals and safeguarding cells. Malondialdehyde (MDA), a stable marker of lipid peroxidation, indicates oxidative stress levels. Results from this study showed that rats exposed to Arsenic trioxide exhibited significantly reduced levels of SOD, CAT, and GSH, alongside increased MDA concentrations compared to the control group. These findings support previous research indicating that the toxic effects of Arsenic trioxide are mediated through oxidative stress (Varghese *et al.*, 2014; Dugo *et al.*, 2017; Paithankar *et al.*, 2021). Prior studies have shown that Arsenic trioxide-induced oxidative stress occurs due to decreased activity of antioxidant enzymes (Shahid *et al.*, 2020; Zulfiqar and Ashraf, 2022) and increased lipid peroxidation (Byeon *et al.*, 2021) in experimental animals. Notably, rats pre-treated with Ginger before Arsenic trioxide exposure showed a significant increase in SOD and GSH levels and a significant reduction in MDA levels. This enhancement in the antioxidant defense system is likely attributable to the antioxidant properties of *Zingiber officinale*, which is known to contain bioactive compounds such as gingerol, shogaol, and paradol, which possess strong antioxidant properties (Zhukovets and Özcan, 2020; Dissanayake *et al.*, 2020). These compounds have been shown to scavenge free radicals and reduce oxidative stress, thereby protecting cells from damage.

Histological results from this study showed that the spleen histology of rats treated with arsenic trioxide only showed a range of toxic pathological changes. This was evident in severe vascular congestion, severe vascular dilatation and ulceration, marked red cell sequestration, and follicular

atrophy. Severe vascular congestion observed in the spleens of rats given arsenic trioxide is indicative of impaired blood flow, which can lead to tissue hypoxia and subsequent damage. This is a critical finding as the spleen is an organ that filters blood, manages blood cells and plays a role in immune responses. Vascular congestion may impede these functions significantly. Severe vascular dilatation and ulceration suggest further damage to the spleen's vasculature, potentially compromising the integrity and function of the blood vessels within the spleen. These dilated vessels and resulting ulcerations could lead to increased permeability, haemorrhage, or even thrombosis, further exacerbating tissue damage. Previous studies on arsenic toxicity have similarly reported cytotoxic and immunotoxic effects on various organ systems (Islam, 2015; Bellamri *et al.*, 2018; Giles and Mann, 2022). For instance, arsenic exposure has been associated with a broad range of pathological changes including vascular damage, inflammation, and oxidative stress in various tissues (Varghese *et al.*, 2014; Dugo *et al.*, 2017; Paithankar *et al.*, 2021). Arsenic has been reported to induce endothelial dysfunction leading to cardiovascular diseases, alterations in hematopoiesis, and a weakened immune response (Poller *et al.*, 2020; Theofilis *et al.*, 2021). Interestingly, there were remarkable improvements in the spleen histology of arsenic trioxide-exposed rats pre-treated with *Zingiber officinale*. Notably, normal lymphoid follicles were preserved with both doses of *Zingiber officinale*, which suggests a protective effect against arsenic's immunosuppressive action.

CONCLUSION

This study shows that *Zingiber officinale* protects against arsenic trioxide-induced splenic damage in Wistar rats. In light of these findings, the potential use of *Zingiber officinale* in conjunction with current chelation therapies, could significantly advance the therapeutic strategies available for arsenic-related pathologies.

REFERENCES

- Akbari, B; Baghaei-Yazdi, N; Bahmaie, M; Mahdavi-Abhari, F (2022). The role of plant-derived natural antioxidants in reduction of oxidative stress. *BioFactors*, 48(3), 611-633.
- Al-Salem, AH (2023). Pathophysiology and Functions of the Spleen. In *The Spleen: Anatomy, Physiology and diseases* (pp. 33-49). Singapore: Springer Nature Singapore.
- Alvaro, D; Caporaso, N; Giannini, EG; Iacobellis, A; Morelli, M; Toniutto, P; Violi, F; PReBRiC (Procedure-Related Bleeding Risk in Cirrhosis) group. (2021). Procedure-related bleeding risk in patients with cirrhosis and severe thrombocytopenia. *Eur. J. Clin. Invest.* 51(6): e13508.
- Angelopoulou, E; Paudel, YN; Papageorgiou, SG; Piperi, C (2022). Elucidating the beneficial effects of ginger (*Zingiber officinale* Roscoe) in Parkinson's disease. *ACS Pharm.. Transl. Sci.*, 5(10): 838-848.

- Azeez, TB; Lungihar, J (2021). Antiinflammatory effects of turmeric (*Curcuma longa*) and ginger (*Zingiber officinale*). *Inflamm. Nat. Prod.* 83-102.
- Bellamri, N; Morzadec, C; Fardel, O; Vernhet, L (2018). Arsenic and the immune system. *Curr. Opin. Toxicol.* 10: 60-68.
- Buege JA; Aust SD (1978). Microsomal lipid peroxidation. *Method in Enzymology*, 52: 302-310.
- Byeon, E; Kang, HM; Yoon, C; Lee, JS (2021). Toxicity mechanisms of arsenic compounds in aquatic organisms. *Aquat. Toxicol.* 237:105901.
- Chabot-Richards, DS; George, TI (2015). White blood cell counts. *Clin. Lab. Med.* 35(1): 11-24.
- Cohen, G; Dembiec, D; Marcus, J (1970). Measurement of catalase activity in tissue extracts. *Anal. Biochem.* 34: 30-38.
- Colamartino, M; Santoro, M; Duranti, G; Sabatini, S; Ceci, R; Testa, A; Padua, L; Cozzi, R (2015). Evaluation of levodopa and carbidopa antioxidant activity in normal human lymphocytes in vitro: implication for oxidative stress in Parkinson's disease. *Neur. Res.* 27: 106-117.
- Dhanik, J; Arya, N; Nand, V (2017). A review on *Zingiber officinale*. *J. Pharm. Phy.* 6(3): 174-184.
- Dissanayake, KGC; Waliwita, WALC; Liyanage, RP (2020). A review on medicinal uses of *Zingiber officinale* (ginger). *Int. J. Health Sci. Res.* 10(6): 142-148.
- Drury, RA; Wallington, EA (1980). Carleton's Histological Techniques. 5th Edition, *Oxford University Press*, New York. 195.
- Duan, X; Gao, S; Li, J; Wu, L; Zhang, Y; Li, W; Zhao, L; Chen, J; Yang, S; Sun, G; Li, B (2017). Acute arsenic exposure induces inflammatory responses and CD4+ T cell subpopulations differentiation in spleen and thymus with the involvement of MAPK, NF- κ B, and Nrf2. *Mol. Imm.* 81: 160-172.
- Dugo, EB; Yedjou, CG; Stevens, JJ; Tchounwou, PB (2017). Therapeutic potential of arsenic trioxide (ATO) in treatment of hepatocellular carcinoma: Role of oxidative stress in ATO-induced apoptosis. *Ann. Clin. Path.* 5(1).
- El-Boshy, ME; Risha, EF; Abdelhamid, FM; Mubarak, MS; Hadda, TB (2015). Protective effects of selenium against cadmium induced hematological disturbances, immunosuppressive, oxidative stress and hepatorenal damage in rats. *J. Tr. El. Med. Bio.* 29: 104-110.
- El-Boshy, M; Ashshi, A; Gaith, M; Qusty, N; Bokhary, T; AlTaweel, N; Abdelhady, M (2017). Studies on the protective effect of the artichoke (*Cynara scolymus*) leaf extract against cadmium toxicity-induced oxidative stress, hepatorenal damage, and immunosuppressive and hematological disorders in rats. *Environ. Sci. Pol. Res.* 24: 12372-12383.
- Ezzat, SM; Ezzat, MI; Okba, MM; Menze, ET; Abdel-Naim, AB (2018). The hidden mechanism beyond ginger (*Zingiber officinale* Rosc.) potent in vivo and in vitro anti-inflammatory activity. *J. Ethnopharm.* 214: 113-123.
- Garcia-Vargas, GG; Cebrian, ME (2023). Health effects of arsenic. In *Toxicology of Metals, Volume I* (pp. 423-438). CRC Press.
- Giles, BH; Mann, KK (2022). Arsenic as an immunotoxicant. *Tox. App. Pharm.* 454: 116248.
- Gu, SX; Dayal, S (2022). Redox mechanisms of platelet activation in aging. *Antioxidants*, 11(5): 995.
- Hashim, A (2023). Human Health Effects of Chronic Arsenic Exposure. In *Arsenic Toxicity Remediation: Biotechnological Approaches* (pp. 45-60). Cham: Springer Nature Switzerland.
- Islam, LN (2015). Immunotoxic effects of arsenic exposure. In *Handbook of Arsenic Toxicology* (pp. 493-519). Academic Press.
- Jomova, K; Alomar, SY; Alwasel, SH; Nepovimova, E; Kuca, K; Valko, M. (2024). Several lines of antioxidant defense against oxidative stress: antioxidant enzymes, nanomaterials with multiple enzyme-mimicking activities, and low-molecular-weight antioxidants. *Arch. Tox.* 98(5): 1323-1367.
- Karunakaran, R; Sadanandan, SP (2019). *Zingiber officinale*: Antiinflammatory actions and potential usage for arthritic conditions. In *Bioactive food as dietary interventions for arthritis and related inflammatory diseases* (pp. 233-244). Academic Press.
- Khan, SS; Flora, SJS (2023). Arsenic: Chemistry, occurrence, and exposure. In *Handbook of Arsenic Toxicology* (pp. 1-49). Academic Press.
- Kile, ML; Faraj, JM; Ronnenberg, AG; Quamruzzaman, Q; Rahman, M; Mostofa, G; Afroz, S; Christiani, DC (2016). A cross-sectional study of anaemia and iron deficiency as risk factors for arsenic-induced skin lesions in Bangladeshi women. *BMC Pub. Health*, 16: 1-10.
- Kishimoto, S; Maruhashi, T; Kajikawa, M; Matsui, S; Hashimoto, H; Takaeko, Y; Harada, T; Yamaji, T; Han, Y; Kihara, Y; Chayama, K; Goto, C; Yusoff, FM; Nakashima, A; Higashi, Y (2020). Hematocrit, hemoglobin and red blood cells are associated with vascular function and vascular structure in men. *Scientific reports*, 10(1): 11467.
- Lewis, SM; Williams, A; Eisenbarth, SC (2019). Structure and function of the immune system in the spleen. *Sci. Imm.* 4(33): 6085.
- Li, X; Wu, L; Wu, R; Sun, M; Fu, K; Kuang, T; Wang, Z. (2022). Comparison of medicinal preparations of Ayurveda in India and five traditional medicines in China. *J. Ethnopharm.* 284: 114775.

- Mahmoud, AH; Abbas, MM; Abdelmonem, HA (2022). The Antioxidant effects of cerium oxide nanoparticles and Echinacea purpurea against lead-induced immunosuppression in male albino rats. *The Egyptian J. Hosp. Med.* 89(2): 6106-6114.
- Misra, HP; Fridovich, I (1972). The role of superoxide anion in the autooxidation of epinephrine and simple assay for superoxide dismutase. *The J. Bio. Chem.* 247: 3170-3175.
- Nyman, M. (1959). Serum hemoglobin; methodological and clinical studies. *Scan. J. Clin. Lab. Inv.*, 11: 1-169.
- Paithankar, JG; Saini, S; Dwivedi, S; Sharma, A; Chowdhuri, DK (2021). Heavy metal associated health hazards: An interplay of oxidative stress and signal transduction. *Chemosphere*, 262: 128350.
- Poller, WC; Nahrendorf, M; Swirski, FK (2020). Hematopoiesis and cardiovascular disease. *Cir. Res.*, 126(8): 1061-1085.
- Polya, DA; Lawson, M. (2015). Geogenic and anthropogenic arsenic hazard in groundwaters and soils: Distribution, nature, origin, and human exposure routes. *Arsenic: Exp. Sour. Health risks, Mech. Tox.* 23-60.
- Raeeszadeh, M; Karimi, P; Khademi, N; Mortazavi, P. (2022). The effect of broccoli extract in arsenic-induced experimental poisoning on the hematological, biochemical, and electrophoretic parameters of the liver and kidney of rats. *Evidence-based Comp. Alt. Med.* 2022.
- Rosales, C. (2020). Neutrophils at the crossroads of innate and adaptive immunity. *J. Leuc. Bio.*, 108(1): 377-396.
- Selders, GS; Fetz, AE; Radic, MZ; Bowlin, GL (2017). An overview of the role of neutrophils in innate immunity, inflammation and host-biomaterial integration. *Reg. Bio.*, 4(1): 55-68.
- Shah, N; Khisroon, M; Shah, SSA (2020). Assessment of copper, chromium, and lead toxicity in fish (*Ctenopharyngodon idella Valenciennes, 1844*) through hematological biomarkers. *Environ. Sci. Poll. Res.* 27(26): 33259-33269.
- Shahid, M; Farooq, ABU; Rabbani, F; Khalid, S; Dumat, C. (2020). Risk assessment and biophysicochemical responses of spinach to foliar application of lead oxide nanoparticles: A multivariate analysis. *Chemosphere*, 245: 125605.
- Shahrajabian, MH; Sun, W; Cheng, Q (2019). Clinical aspects and health benefits of ginger (*Zingiber officinale*) in both traditional Chinese medicine and modern industry. *Acta agriculturae scandinavica, section b—Soil and Plant Science*, 69(6): 546-556.
- Shaji, E; Santosh, M; Sarath, KV; Prakash, P; Deepchand, V; Divya, BV (2021). Arsenic contamination of groundwater: A global synopsis with focus on the Indian Peninsula. *Geosci. Front.*, 12(3): 101079.
- Shariati, A; Moradabadi, A; Azimi, T; Ghaznavi-Rad, E. (2020). Wound healing properties and antimicrobial activity of platelet-derived biomaterials. *Sci. Rep.* 10(1): 1032.
- Theofilis, P; Sagris, M; Oikonomou, E; Antonopoulos, AS; Siasos, G; Tsioufis, C; Tousoulis, D (2021). Inflammatory mechanisms contributing to endothelial dysfunction. *Biomedicines*, 9(7): 781.
- Varghese, MV; Manju, A; Abhilash, M; Paul, MS; Abhilash, S; Nair, RH (2014). Oxidative stress induced by the chemotherapeutic agent arsenic trioxide. *3 Biotech*, 4: 425-430.
- Zarei, M; Acharya, P; Talahalli, RR (2021). Ginger and turmeric lipid-solubles attenuate heated oil-induced cardio-hepatic oxidative stress via the up-regulation of nuclear factor erythroid 2-related factor 2 and decrease blood pressure in rats. *Bri. J. Nutr.*, 126(2): 199-207.
- Zhukovets, T; Özcan, MM (2020). A review: composition, use and bioactive properties of ginger (*Zingiber officinale* L.) rhizoms. *J. Agroaliment. Proc. Technol*, 26:216.
- Zulfiqar, F; Ashraf, M (2022). Antioxidants as modulators of arsenic-induced oxidative stress tolerance in plants: An overview. *J. Hazardous Mat.* 427:127891.