

Access this Article online

Quick Response Code:

Website:
jecajournal.comDoi:
doi.org/10.4314/jeca.v20i2.8

Nephroprotective Effects of *Cajanus cajan* on Lead acetate-Induced Kidney Damage of Male Wistar Rats

¹Ovie, F.O., ²Nwanama, E.K., ³Nwafor, C.C., ⁴Mbang, J.E., ⁵Mayaki, E.O., ¹Nnachi, I.S., ¹Ugwu, V.I.

Abstract

BACKGROUND AND AIM: Lead acetate (Pb), a contaminant found in the environment, is one of the many substances and medications that can cause nephrotoxicity. In male Wistar rats, this study investigated the nephroprotective properties of *Cajanus cajan* ethanol leaf extract.

METHODOLOGY: Twenty (20) adult Wistar rats weighing 150-180g were divided randomly into five groups of four rats each. Group A served as the control and received no treatment. Group B was given only lead acetate dissolved in water at 20 mg/kg body weight via oral gavage. Group C, D and E were given oral intubation of *C. cajan* ethanol leaf extract at 200, 400 and 800 mg/kg respectively for 14 days followed by oral gavage of Lead acetate mixed in water at 20 mg/kg for 7 days. At day 15 animals were anaesthetized using chloroform. 4 ml of blood sample was collected by ocular puncture from each of the animals using capillary tube and allowed to clot. The serum was collected and further assessed. The Kidney was quickly harvested washed in saline and was stored in 10% formalin solution at room temperature for histopathological studies.

RESULTS: When compared to control group A, the lead-exposed group's, B, C, D and E Groups of serum creatinine and urea levels increased remarkably ($p < 0.05$). Serum creatinine and urea levels in the *Cajanus cajan*-treated groups C, D and E were significantly ($p < 0.05$) lower compared to group B which was only lead exposed. In the histology, control group showed normal architecture of the kidney. While in group B, administration of lead acetate was seen to cause non-proliferative glomerular atrophy. While in the treated group C, D and E mataplasia and glomerular atrophy were significantly decreased compared to group B.

CONCLUSION: Findings suggest that *Cajanus cajan* has a significant protection on the kidneys from the harmful effects of lead.

Keywords:

Lead, *Cajanus cajan*, Nephrotoxicity, Urea, Serum creatinine

INTRODUCTION

A major environmental pollutant is lead. This environmental contaminant is significant. It can enter the body by ingesting contaminated food and water, inhaling polluted dust, or inhaling air that is polluted (Mohamed *et al.*, 2020). Lead poisoning has grown to be a significant health danger for people in Nigeria due to the rising industry. Children's kidneys and other organ physiologic functions, as well as their neurodevelopment, can suffer greatly from it (Gargour *et al.*, 2020). The kidney, which is one of the important organs in the body, is most

at risk to sub-acute or acute lead exposure (Salama *et al.*, 2016, Harari *et al.*, 2018). Lead-induced nephrotoxicity also involves oxidative stress, an inflammatory response, and alterations in histopathology (Liu *et al.*, 2012).

Lead-induced oxidative stress develops when the kidney levels of reactive oxygen species (ROS) and antioxidants are out of equilibrium (Gautam & Flora 2010, Jiang *et al.*, 2018). Additionally, because these free radicals are so reactive with DNA and nephron-membrane lipids, excessive lead generation

This is an open access journal, and articles are distributed under the terms of the Creative Commons Attribution-Non Commercial-Share Alike 4.0 License, which allows others to remix, tweak, and build upon the work non-commercially, as long as appropriate credit is given and the new creations are licensed under the identical terms.

For reprints contact: jecajournal@gmail.com

How to cite this article: Ovie, F.O., Nwanama, E.K., Nwafor, C.C., Mbang, J.E., Mayaki, E.O., Nnachi, I.S., Ugwu, V.I. Nephroprotective Effects of *Cajanus cajan* on Lead acetate-Induced Kidney Damage of Male Wistar Rats. *J Exp Clin Anat* 2023; 20(2):50-54.

doi.org/10.4314/jeca.v20i2.8

Submitted: 10th January, 2024
Revised: 21st February, 2024
Accepted: 23rd February, 2024
Published: 15th April, 2024

¹Department of Anatomy,
Faculty of Basic Medical
Sciences, State University of
Medical and Applied Science,
Igbo-Eno, Enugu State, Nigeria;

²Department of Midwifery,
Sancta Maria Catholic College
of Nursing Sciences Uzairue,
Edo State, Nigeria;

³Department of Physiology,
Faculty of Basic Medical
Sciences, Enugu State
University College of Medicine,
Parklane, Enugu State, Nigeria;

⁴Department of Anatomy,
Faculty of Basic Medical
Sciences, University of Calabar,
Cross Rivers State, Nigeria;

⁵Department of Anatomy,
Faculty of Basic Medical
Sciences, Edo State University
Uzairue, Edo State, Nigeria

Address for Correspondence:

Ovie, F.O.

Department of Anatomy,
Faculty of Basic Medical
Sciences, State University of
Medical and Applied Science,
Igbo-Eno, Enugu State, Nigeria
+234 816 659 3080
oviedawnc@gmail.com

might cause stress damage to the glomeruli and nephron tubules (Sudjarwo *et al.*, 2019). For the treatment of lead-induced kidney disease, there are numerous pharmacological antioxidant and anti-inflammatory drugs accessible, but they have unfavorable side effects (Gargour *et al.*, 2020). In recent years, it has been demonstrated that herbal components derived from Nigerian native plants can guard against oxidative stress and inflammation (Charles *et al.*, 2021). Flavonoids, which make up the majority of the bioactive components, have demonstrated promise as prospective therapies for lead-induced nephrotoxicity (Sudjarwo *et al.*, 2019, Rahmi *et al.*, 2020), having a diverse range of pharmacologic actions including antioxidant, anti-inflammatory, hepatoprotective, and anticarcinogenic effects (Choy *et al.*, 2019, Wang *et al.*, 2019).

Pigeon pea (*Cajanus cajan*) is a medicinal plant known to strengthen the immune system and is used to treat infections, bedsores, malaria, and wounds (Zavinson *et al.*, 2019, Hayat *et al.*, 2021). It has several therapeutic qualities including antioxidant, anthelmintic and hepatoprotection (Maha *et al.*, 2016, Evbakhavbokun *et al.*, 2019). This present work aimed to examine the ethanol leaf extract of *Cajanus cajan* on renal parameters of lead-induced nephrotoxicity in Wistar rats.

MATERIAL AND METHODS

Chemicals

Lead acetate was purchased from a well-known chemical store in Gariki Market, Enugu State, Southeast Nigeria. Lead acetate was dissolved in distilled water, and administered to the experimental animals via oral gavage.

Collection and Preparation of Plant Extract

The leaves of *C. cajan* were obtained in June 2022 from a market in Calabar, Cross River State, Nigeria and properly identified and authenticated by a qualified taxonomist with number UC/FEC/2022/0014. They were plucked from their branches, washed and air dried at room temperature (26 °C) for four weeks. The air-dried leaves of *C. cajan* were pulverized using an electric blender which yielded 300.1 g and were soaked in 99% ethanol (900 ml) for 72h. It was then sieved out using a muslin cloth. The extract was concentrated using a Rotary evaporator at 50 °C to obtain a yield of 26g semi-solid crude substance (Ogbu *et al.*, 2022, Nwafor *et al.*, 2021).

Animals and Managements

Twenty (20) healthy male Wistar rats weighing 150–180 g were used for the experiment. They were purchased from the National Institute of Research, Vom, Plateau State. They were separated randomly into five groups consisting of four animals each ($n = 4$) in different aluminum cages, placed in a well-ventilated house with optimum conditions (temperature 30°C photoperiod; 12 hours natural light and 12 hours dark;

humidity is 40-50%). The animals were fed growers' mash manufactured by Top Feed Nigeria Limited and allowed free access to water. Rats were acclimatized for two weeks and throughout the experimental period; the animals were handled according to the guidelines for animal research in the National Institute of Health (NIH) guidelines for the care and use of laboratory animals (NIH, 1985). The study was carried out per the principles of laboratory animal care and standard experimental procedures. Twenty (20) adult Wistar rats were divided randomly into five groups of four: Group A served as the control and received no treatment. Group B was given oral gavage of only Lead acetate mixed in water at 20 mg/kg body weight via oral gavage. Group C, D and E were given oral intubation of *C. cajan* ethanol leaf extract at 200, 400 and 800 mg/kg respectively for 14 days followed by oral gavage of Lead acetate mixed in water at 20 mg/kg for 7 days.

Collection of Blood and Kidney Tissue

Twenty (24) hours after the last administration of the extract, all experimental animals were anaesthetized using chloroform. 4 ml of blood sample was collected by ocular puncture from each of the animals using capillary tube and allowed to clot. The serum was collected for estimation of creatinine, urea and stored at 4^{oC} in a refrigerator. The Kidney was quickly harvested, washed in saline and was stored in 10% formalin solution at room temperature for histopathological studies.

Determination of Urea

Using urease-berthelot method, urea in serum is hydrolyzed to ammonia. Berthelot's reaction is then used to measure ammonia photometrically.

Determination of Creatinine

A direct end-point method was used to determine creatinine. In an alkaline solution, creatinine interacts with picric acid to generate a colored complex. The amount of complex produced is proportional to the concentration of creatinine.

Histological Studies

Histological sections were prepared from paraffin blocks and stained with haematoxylin and eosin (H & E) to examine changes in the morphology of the tissue.

Statistical Analysis

SPSS (Version 24) was used for all statistical analyses. Statistical significance was determined at $p \leq .05$. Data was expressed as mean \pm standard error of mean (SEM).

RESULTS

Effect of *Cajanus cajan* on urea and creatinine

Lead acetate induction significantly ($p \leq 0.05$) increased urea and creatinine when compared to the control group (Table 1).

C. cajan treated groups were seen to significantly ($p \leq 0.05$) reduce urea and creatinine to near normal levels when compared to Group B. This reduction was comparable with

normal control and statistically significant in 800mg/kg body weight and 200 mg/kg body weight.

Table 1: Effect of *Cajanus cajan* on serum urea and creatinine activity

Enzymes Markers	GROUP A (mg/dL) (Mean±SD)	GROUP B (mg/dL) (Mean±SD)	GROUP C (mg/dL) (Mean±SD)	GROUP D (mg/dL) (Mean±SD)	GROUP E (mg/dL) (Mean±SD)	p-value
Urea	6.31±1.69	19.08±4.03 ^a	15.12±1.24	10.46±0.47	6.75±2.01 ^b	0.009
Creatinine	1.18±0.28	7.73±1.90 ^a	6.38±1.08	3.42±1.47	2.40±0.52	0.012

Values are expressed as mean ± SD; ^aValues differ significantly from the control group; ^b Values differ significantly from lead-treated group

Effect of *Cajanus cajan* on Histological Features of the kidney

Figure 1 shows the photomicrographs of the kidneys. The control group showed normal architecture of the nephrocytes (Figure 1 A). Administration of Lead acetate was seen to cause non-proliferative glomerular atrophy (arrow), and tubular metaplasia with progressive parenchyma

pigmentation as shown in (Figure 1 B). Nephrotic damage was protected by the administration of *Cajanus cajan*, and the histological index of tubular metaplasia, non-proliferative glomerular atrophy, and parenchyma pigmentation were significantly decreased to some extent (Figure 1 C-E).

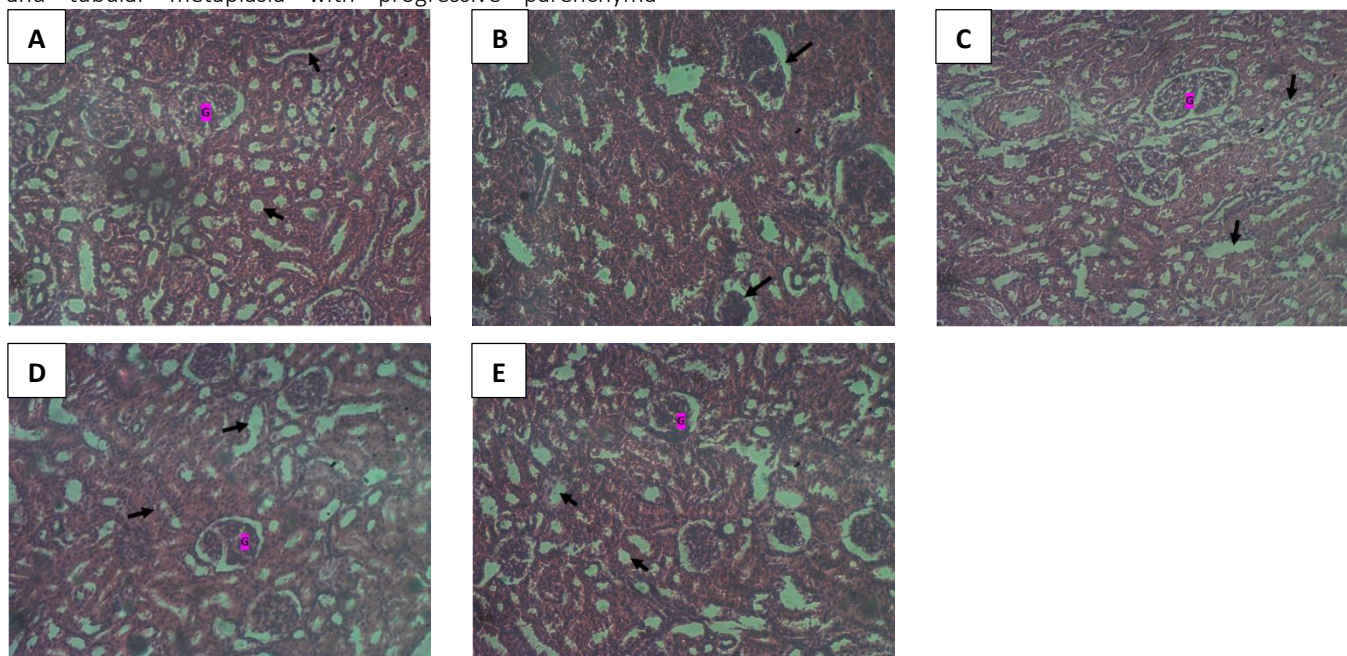


Figure 1: Photomicrograph of hematoxylin and eosin-stained section (X200) of normal Kidney. Histology showing control and experimental groups. A (control), B (20mg/kg body weight of Lead acetate), C (200 mg/kg body weight of *Cajanus cajan*+ 20mg/kg body weight of Lead acetate), D (400 mg/kg body weight of *Cajanus cajan*+ 20mg/kg body weight of Lead acetate), E (800 mg/kg body weight of *Cajanus cajan*+ 20mg/kg body weight of Lead acetate)

DISCUSSION

There are numerous biochemical and physiological dysfunctions in both humans and laboratory animals as a result the prevalent environmental toxin lead. According to recent studies by Wang et al. (2020), Aladaileh et al. (2020), and Charles et al. (2022), medicinal herbs can remove lead ions from blood and organs. *C. cajan* was employed as a medicinal plant to cure toxicity hundreds of years ago. According to the current study's findings, in the blood and

kidneys of Wistar rats with lead-induced nephrotoxicity, lead was significantly antagonistic to *C. cajan ethanol leaf* extract (Table 1).

This finding is in line with Adhikari et al. (2018) that discovered that a combination of soluble Pb-flavonoids (naringin) can minimize lead toxicity *in vivo* and *in vitro* due to its chelation and antioxidant characteristics.

According to Gargouri *et al.* (2019) the kidney mostly removes xenobiotics through urine excretion.

Lead-induced nephrotoxicity attracts increasing attention in developing nations. Urea and serum creatinine are measures of renal function. Urea and serum creatinine levels are typically abnormally elevated as a result of renal dysfunction (Sudjarwo *et al.*, 2019). According to the study's findings, lead-exposed rats had significantly higher serum levels of urea and creatinine than the control group. *C. cajan* reversed the higher serum levels of urea and creatinine caused by lead administration (Table 1). Lead buildup in renal tissue can damage glomerular structures directly and reduce kidney functions (Figure 1). This finding is in line with clinical research, which found that the flavonoids quercetin protected the glomerular structure in patients with iodinated contrast-induced nephropathy, as demonstrated by a drop in serum creatinine (Vicente *et al.*, 2019). By reversing the urea and creatinine levels, *C. cajan* may be able to protect glomerular structures. Furthermore, Wistar rats exposed to Pb alone developed obvious kidney injury. The pathologic alterations to the kidney brought on by Pb could be greatly reduced by *C. cajan* (Figure 1). These results indicated that *C. cajan* may be a valuable renal-protective substance.

In conclusion, this study demonstrated that *Cajanus cajan* protected the kidney against lead-induced nephrotoxicity by reducing Serum Creatinine and Urea levels in Wistar rats. The ethanol leaf extract of *C. cajan* showed a strong protective effect in the restoration of renal tubules and glomeruli in groups that received both low and medium doses but more pronounced in the group with the high dose of the extract. Our findings suggest that *C. cajan* could be a natural antioxidant and anti-inflammatory agent for treating lead-induced nephrotoxicity.

Ethics Statement

The animal study was reviewed and approved by the Animal Ethics Committee of Abia State University.

Author Contributions

All the authors contributed conception and design of the study. M.J.E performed the animal experiments and N.E.K, M.E.O and O.F.O carried data analysis. All the authors wrote the first draft of the manuscript. All authors contributed to the article and approved the submitted version.

Conflict of interest: None declared

Availability of data and material: All data generated or analyzed during this study are included in this published article

References

- Adhikari, A., Darbar, S., Chatterjee, T., Das, M., Polley, N., Bhattacharyya, M., et al. (2018). Spectroscopic studies on dual role of natural flavonoids in detoxification of lead poisoning: Bench-to-bedside preclinical trial. *ACS Omega* 3 (11), 15975–15987. doi: 10.1021/acsomega.8b02046
- Aladaileh, S. H., Khafaga, A. F., Abd, E. M., Al-Gabri, N. A., Abukhalil, M. H., Alfwuaires, M. A., et al. (2020). Spirulinaplatis ameliorates the sub chronic toxicities of lead in rabbits via anti-oxidative, anti-inflammatory, and immune stimulatory properties. *Sci. Total Environ.* 701, 134879. doi: 10.1016/j.scitotenv.2019.134879
- Nwafor C.C., Amah-Tariah F. S and Dapper D. V (2021): Effect of Hydroethanolic Extract of Fleurya Aestuans on Haematological Parameters and Oxidative Indices of Phenylhydrazin Induced Toxicity. *International Journal of Research and Reports in Hematology* 4(3): 17-27.
- Nwafor C.C., Osakwe F. Uchechwukwu, Mfonido G. Umanah, Ekikereabasi P. Inyang a, and Peters K. Dell (2022). EofFleuryaaestuans extract (FAE) on histological and renal function test (RFT) in an alloxan-induced type diabetic Wistar rats. *International Journal of Advances in Nephrology Research.* 5(1): 56-63.
- Nwafor C.C., Uzoma A. Ugonna, Solomon M. UvohAndAsara A. (2021). Restoration Of Nephrological Parameters By Fleurya Aestuans Leaves And Tetrahydroxyflavone Of Lead Acetate Induced Toxicity. *World Journal of Pharmaceutical Research.*10(13),1872-1882.DOI:10.20959/wjpr202113-20570.
- Choy, K. W., Murugan, D., Leong, X. F., Abas, R., Alias, A., Mustafa, M. R. (2019). Flavonoids as natural anti-inflammatory agents targeting nuclear factor-kappa B (NFkappaB) signaling in cardiovascular diseases: A mini review. *Front. Pharmacol.* 10, 1295.
- Evbakhavbokun, W. O. and Iweala E.J. Emeka. Protective Effect of Cajanuscajan in Hepatotoxic Rats. *Earth and Environmental Science* 331 (2019) 012023
- Gargouri, M., Akrouti, A., Magné, C., El Feki, A., Soussi, A. (2020). Protective effects of spirulina against hemato-biochemical alterations, nephrotoxicity, and DNA damage upon lead exposition. *Hum. Exp. Toxicol.* 39 (6), 855–869.
- Gargouri, M., Soussi, A., Akrouti, A., Magne, C., El, F. A. (2019). Potential protective effects of the edible alga *Arthrospiraplatis* against lead-induced oxidative stress, anemia, kidney injury, and histopathological changes in adult rats. *Appl. Physiol. Nutr. Metab.* 44 (3), 271–281. doi: 10.1139/apnm-2018-0428
- Gautam, P., Flora, S. J. S. (2010). Oral supplementation of gossypin during lead exposure protects alteration in heme synthesis pathway and brain oxidative stress in rats. *Nutrition* 26 (5), 563–570.

11. Harari, F., Sallsten, G., Christensson, A., Petkovic, M., Hedblad, B., Forsgard, N., et al. (2018). Blood lead levels and decreased kidney function in a population-based cohort. *Am. J. Kidney Dis.* 72 (3), 381–389.
12. Hayat, K.; Khan, J.; Khan, A.; Ullah, S.; Ali, S.; Salahuddin; Fu, Y. Ameliorative Effects of Exogenous Proline on Photosynthetic Attributes, Nutrients Uptake, and Oxidative Stresses under Cadmium in Pigeon Pea (*Cajanuscajan L.*). *Plants* 2021, 10, 796.
13. Jiang, S., Shang, M., Mu, K., Jiang, N., Wen, H., Wang, R., et al. (2018). In vitro and in vivo toxic effects and inflammatory responses induced by carboxylated black carbon-lead complex exposure. *Ecotoxicol. Environ. Saf.* 165, 484–494.
14. Liu, C. M., Ma, J. Q., Sun, Y. Z. (2012). Puerarin protects rat kidney from lead-induced apoptosis by modulating the PI3K/Akt/eNOS pathway. *Toxicol. Appl. Pharm.* 258 (3), 330–342.
15. Maha Z Rizk, Hanan F Aly, Dina M Abo-Elmatty, MM Desoky, N Ibrahim, Eman A Younis. Hepatoprotective effect of *Caesalpinigiagilliesii* and *Cajanus cajan* proteins against acetoaminophen overdose-induced hepatic damage. *Toxicology and Industrial Health* 2016, Vol. 32(5) 877–907
16. Mohamed, R. S., Fouda, K., Akl, E. M. (2020). Hepatorenal protective effect of flaxseed protein isolate incorporated in lemon juice against lead toxicity in rats. *Toxicol. Rep.* 7, 30–35. doi: 10.1016/j.toxrep.2019.12.001
17. National Institute of Health Laboratory Animal Welfare. United State Department of Health and Human Services. 1985; 14:8.
18. Ogbu C.O, Bawa I, Suleiman Z, Ocheleka M.I, Zakari H, Ameh M, Offor. C.E. Hepatoprotective Potentials of Ethanolic Leaf Extract of *Cajanus cajan* (linn) in Ethanol-evoked Oxidative Stress in Albino Rats. ; *IRJGH*, 5(2): 1-6, 2022; Article no.IRJGH.84759
19. Rahmi, E. P., Kumolosasi, E., Jalil, J., Husain, K., Buang, F., Abd, R. A., et al. (2020). Anti-hyperuricemic and anti-inflammatory effects of *Marantodespumilum* as potential treatment for gout. *Front. Pharmacol.* 11, 289.
20. Ravipati, E. S., Mahajan, N. N., Sharma, S., Hatware, K. V., Patil, K. (2019). The toxicological effects of lead and its analytical trends: an update from 2000 to 2018. *Crit. Rev. Anal. Chem.*, 1–16. doi: 10.1080/10408347.2019.1678381
21. Salama, S. A., Arab, H. H., Maghrabi, I. A., Hassan, M. H., AlSaeed, M. S. (2016). Gamma-glutamyl cysteine attenuates tissue damage and enhances tissue regeneration in a rat model of lead-induced nephrotoxicity. *Biol. Trace Elem. Res.* 173 (1), 96–107.
22. Shirpoor, A., Rezaei, F., Fard, A. A., Afshari, A. T., Gharalari, F. H., Rasmi, Y. (2016). Ginger extract protects rat's kidneys against oxidative damage after chronic ethanol administration. *Biomed. Pharmacother.* 84, 698–704. doi: 10.1016/j.biopha.2016.09.097
23. Sudjarwo, S. A., Eraiko, K., Sudjarwo, G. W., Koerniasari (2019). The potency of chitosan-*Pinusmerkusii* extract nanoparticle as the antioxidant and anti-caspase 3 on lead acetate-induced nephrotoxicity in rat. *J. Adv. Pharm. Technol. Res.* 10 (1), 27–32. doi: 10.4103/japtr.JAPTR_306_18
24. Vicente-Vicente, L., Gonzalez-Calle, D., Casanova, A. G., Hernandez-Sanchez, M. T., Prieto, M., Rama-Merchan, J. C., et al. (2019). Quercetin, a promising clinical candidate for the prevention of contrast-induced nephropathy. *Int. J. Mol. Sci.* 20 (19), 4961. doi: 10.3390/ijms20194961
25. Wang, Q., Zhao, H., Zhu, M., Gao, L., Cheng, N., Cao, W. (2020). Spectroscopy characterization, theoretical study and antioxidant activities of the flavonoids-Pb(II) complexes. *J. Mol. Struct.* 1209, 127919. doi: 10.1016/j.molstruc.2020.127919
26. Wang, S. W., Fang, Y. J., Yu, X. F., Guo, L., Zhang, X. X., Xia, D. Z. (2019). The flavonoid-rich fraction from rhizomes of *Smilax glabra* Roxb. ameliorates renal oxidative stress and inflammation in uric acid nephropathy rats through promoting uric acid excretion. *Biomed. Pharmacother.* 111, 162–168.
27. Zavinon, F.; Sagbadja, H.A. Pigeon pea [*Cajanuscajan (L.) Millsp*] cultivation, its major constraints and ethnobotanical status in Southern Benin. *J. Agric.* 2019, 7, 95–105