

Ectopic cutaneous umbilical gastric mucosa

Kamal Nain Rattan, Pallavi Sonika¹, Shubha Lal², Ananta Rattan

Departments of Paediatric Surgery, ¹Paediatrics and ²Pathology, PGIMS, Rohtak, Haryana, India

Abstract

A 2-year-old male child presented with a complaint of bleeding from umbilicus every 15 days since birth on and off. Child was managed successfully by exploratory laparotomy and local umbilectomy. Histopathology showed gastric mucosa from the excised tissue.

Key words: Gastric, mucosa, umbilicus

INTRODUCTION

Ectopic tissue refers to the finding of normal tissue in foreign sites, entirely separate from the main organ. Ectopic gastric mucosa has been observed throughout the alimentary tract, everywhere from the oral cavity to the rectum (Langkemper *et al.*, 1980). They have also been seen in the intestinal duplication, Meckel's diverticulum, gallbladder or cystic duct and omphalomesenteric duct (Gorlin *et al.*, 1964; Martinez-Urrutia *et al.*, 1990; Willis 1968). However, occurrence in the umbilicus is extremely rare and after extensive search of literature we found only three cases of ectopic gastric mucosa in the umbilicus (Heo and Jeong 2010; Sharma *et al.*, 2013; Shim and Kim 1992). The first case was reported by Shim *et al.* in 1992 where they had found heteropic gastric mucosa and pancreatic tissue and occurrence of isolated gastric musosa was reported by Heo *et al.* in 2010. We are reporting the case of ectopic gastric mucosa in the umbilicus due to rarity.

Address for correspondence:

Dr. Shubha Lal,
A-19, Aakash Ganga Apartments, Plot No. 17, Sector 6,
Dwarka, New Delhi - 110 075, India.
E-mail: shubha1504@gmail.com

Access this article online	
Quick Response Code:	Website: www.jecajournal.org
	DOI: ***

CASE REPORT

A 2-year-old male child, presented to the outpatient department of our hospital with the complaint of bleeding from umbilicus every 15 days since birth lasting 2–3 days. The child was born through normal vaginal delivery following an uneventful gestational period and had no other complaints like vomiting, constipation, etc. Coagulation profile and platelet counts were normal. Factor 8 and 9 levels were also normal and had no history of bleeding from any other site. There is no history of bleeding diathesis in the family. However, child was anemic and was transfused blood but there was no hepatosplenomegaly.

Physical examination showed a reddish papule with skin rugae. Ultrasound abdomen was normal and revealed no omphalomesenteric duct remnant. The child underwent subumbilical laparotomy. No Meckel's diverticulum or any omphalomesenteric duct remnant was observed. So, local umbilectomy was done, and abdomen was closed in layers. Histopathological examination of the excised tissue revealed the lining of the gastric mucosa. No neoplastic changes were detected. The patient recovered completely after the surgery [Figures 1 and 2].

DISCUSSION

Umbilical nodules and granulomas are common in infants and young children. Mostly these nodules vary from solitary lesions to severe congenital anomalies of omphalomesenteric duct. The following theory has been postulated for ectopic tissue – during embryogenesis, the

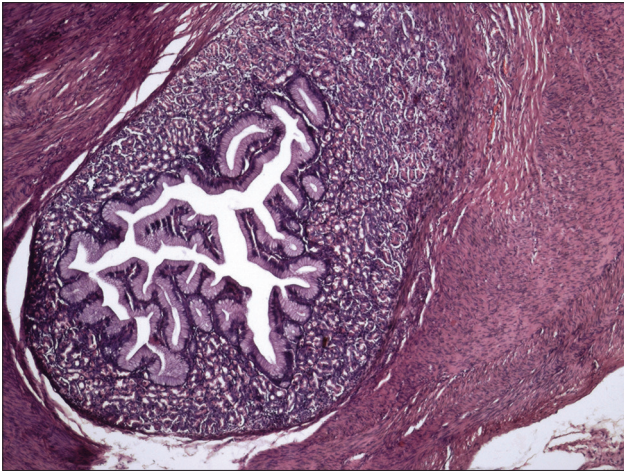


Figure 1: Lining of gastric mucosa surrounded by fibrous tissue and muscle in the excised tissue (H and E, ×40)

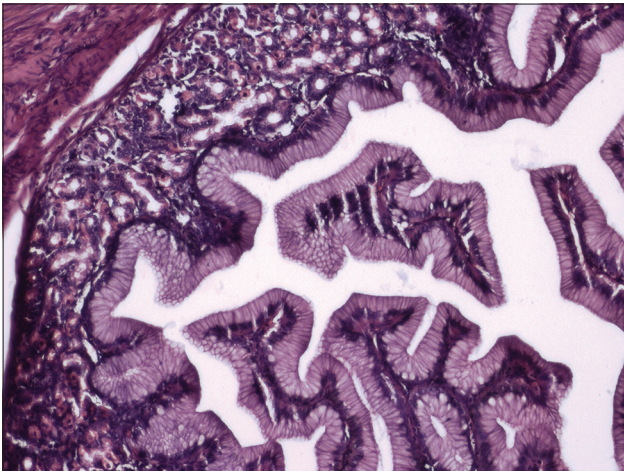


Figure 2: Magnified view (H and E, ×100)

mid gut rotates 90° counter-clockwise within the umbilical cord, around the axis of the superior mesenteric artery,

elongating to form the jejunum and ileum. By 10th week of embryogenesis, the lumen of omphalomesenteric duct closes and midgut returns to the abdominal cavity. It is at this point of time, when gastric mucosa cells could be seeded in the umbilical area (Bauer and Retik 1978). The occurrence of gastric mucosa in umbilicus is very unusual. The main presentation in these cases may be serous discharge, excoriation of skin and bleeding. Ultrasonography is done to rule out any omphalomesenteric remnant. Treatment is complete excision and diagnosis is confirmed by histopathological examination.

REFERENCES

1. Bauer S.B., Retik A.B. (1978). Urachal anomalies and related umbilical disorders. *Urol Clin North Am* 5 (1):195-211.
2. Gorlin R.J., Kahlins V., Izant R.J. (1964). Occurrence of heterotopic gastric mucosa in the tongue. *J Pediatr* 64:604-6.
3. Heo Y.S., Jeong Y. (2010). Heterotopic gastric mucosa in the umbilicus. *Ann Dermatol* 22 (2):223-5.
4. Langkemper R., Hoek A.C., Dekker W. (1980). Elevated lesions in the duodenal bulb caused by heterotopic gastric mucosa. *Radiology* 137 (3):621-4.
5. Martinez-Urrutia M.J., Vasques E.J., Larrauri J. (1990). Gastric heterotropy of the biliary tract. *J Pediatr Surg* 25 (3):356-7.
6. Sharma S., Maheshwari U., Bansal N. (2013). Ectopic pancreatic, gastric and small intestine tissue in an umbilical polyp, causing persistent umbilical discharge in a 2 year old child - A rare case report. 2 (5):447-9.
7. Shim Y.T., Kim S.Y. (1992). Heterotopic gastric mucosa and pancreatic tissue in the skin of the abdominal wall. *J Pediatr Surg* 27 (12):1539-40.
8. Willis R.A. (1968). Some unusual developmental heterotopias. *Br Med J* 3 (5613):267-72.

How to cite this article: ???.

Source of Support: Nil, **Conflict of Interest:** None declared.