

Prevalence of uterine fibroid in a South-Western Nigerian population: A sonographic study

Victor Ukwenya^{1,2}, Nwakaego Maduemezia³, Olasunmbo Afolayan¹, Oluwole Alese⁴, Wilson Thomas²

¹Department of Anatomy, College of Medicine, Ekiti State University, Ado Ekiti, ²Sckye Hospitals Limited, Akure, Ondo State, ³Nwakaego Maduemezia Memorial Medical Centre, Asaba, ⁴Department of Family Medicine, Ekiti State University Teaching Hospital, Ado Ekiti, Nigeria

Abstract

Aim: This study was carried out to evaluate the prevalence of uterine myoma, its variations, location, size and uterine anteroposterior diameter. **Materials and Methods:** The study utilized transabdominal ultrasound to assess myoma in 2,575 female patients. **Results:** Investigation showed 176 cases of myoma, representing a prevalence of 6.83%. 25% of the cases were associated with pregnancy, with solitary myoma accounting for 79.55%. Solitary myoma was noted in 59.09%. Analysis for multiple fibroid showed that 56.94% had 2 myoma; 18.06% had 3; 25% had more than 4 fibroids in-situ. Only 3.41% showed calcific degeneration. **Conclusion:** While higher values have been obtained in Europe, the prevalence of myoma in this study is similar to that documented for other parts of South-Western Nigeria. Results showed the preponderance of solitary myoma both in pregnant and non-pregnant subjects. Findings also showed that increased uterine anteroposterior diameter is correlated with the existence of myoma and could serve as a predictive index for the presence of fibroid.

Key words: Fibroid, prevalence, South-Western Nigeria, ultrasonography, uterus

INTRODUCTION

Uterine fibroids, otherwise known as myoma or leiomyoma, are benign, monoclonal tumors of the smooth muscle cells of the human uterus (Parker, 2007; Kempson and Hendrickson, 2000). They are the most

common tumors in women of reproductive age and are asymptomatic in at least 50% of afflicted women (Gupta *et al.*, 2008). Symptoms include menstrual disturbances such as menorrhagia, dysmenorrhea and intermenstrual bleeding (Gupta *et al.*, 2008); dyspareunia and noncyclic pelvic pain (Lippman *et al.*, 2003) and pressure symptoms such as a sensation of bloatedness, increased urinary frequency, and bowel disturbance are also common (Ciavattini *et al.*, 2013). It may also impair reproductive functions resulting in reduced fertility, early pregnancy loss, increased preterm labor and delivery, and markedly increase the risk for cesarean delivery (Payson *et al.*, 2006, Ciavattini *et al.*, 2013).

Several factors have been implicated in the etiology of fibroids. Epidemiological studies have linked fibroids to the female reproductive hormones, estrogens, and progesterone.

Address for correspondence:

Dr. Victor Ukwenya,
Department of Anatomy, College of Medicine, Ekiti State University,
Ado Ekiti, Nigeria.
E-mail: victorwyn@yahoo.com

Access this article online	
Quick Response Code:	Website: www.jecajournal.org
	DOI: ***

Estrogens and their receptors are reported to exert a great influence on fibroid growth. Several studies found that memory ribonucleic acid (mRNA) and protein expression levels as well as the content of estrogen receptor-alpha (ER- α) and ER- β are higher in leiomyoma compared to those in normal myometrium (Benassayag *et al.*, 1999; Kovács *et al.*, 2001). Estrogens, it is hypothesized, may exert their growth stimulatory effects on leiomyomas intermediated by cytokines, growth factors, or apoptosis factors (Grings *et al.*, 2012).

The role of progesterone in the etiology of fibroids is through its interaction with its receptors, progesterone receptor-A (PR-A) and PR-B (Kastner *et al.*, 1990). Leiomyomas are known to have higher PR content and mRNA levels compared to normal myometrium (Viville *et al.*, 1997; Ying and Weiyuan, 2009). This is further buttressed by the relative overexpression of PR-B mRNA in the surface of leiomyoma as described by Fujimota *et al.*, (1998).

Leiomyoma growth is influenced by progesterone interaction with some growth factors; it upregulates the endothelial growth factor (Shimomura *et al.*, 1998) and transforming growth factor-beta 3 (bimodal action) expression (Arici and Sozen, 2000). On one hand, progesterone seems to downregulate interleukin growth factor-1 expression through PR-B while PR-A appears to inhibit this function (Ying and Weiyuan, 2009).

A study found that the risk of myoma increased 21% with each 10 kg increase in body weight and increasing body mass index (Ross *et al.*, 1986). Shikora *et al.*, (1991) reported similar results in women with >30% body fat. The adipose tissue converts adrenal and ovarian androgens into estrogens, whereas several mechanisms associated with obesity lead to decreased synthesis of sex hormone binding globulin. It is thus possible that the increase of biologically available estrogens could be responsible for an increase in myoma prevalence and/or growth in overweight and obese women.

The incidence of fibroids is highest in blacks than in Caucasian and Hispanic populations (Kjerulff *et al.*, 1996; Marshall *et al.*, 1997). Moreover, blacks tend to have multiple and larger fibroids and more symptomatic fibroids at the time of diagnosis (Gupta *et al.*, 2008).

There are little data from population studies on the true incidence of fibroids (Divakar, 2008). Most research in literature on the prevalence of myoma is based on clinical assessment and retrospective studies of hospital records. Payson *et al.*, (2006) proposed that to ascertain the exact prevalence of myoma, a clinical research should apply ultrasound scanning in a randomly sampled population.

Our model utilized ultrasonography that enabled us to assess the myoma *in situ* in real time as well as engage in morphometric evaluation.

SUBJECTS AND METHODS

This is a 6-month sonographic study of female patients that visited the Ultrasound Unit of Sckye Hospitals, Akure, Nigeria, for routine gynecological and obstetrics evaluation from November 2013 to April 2014. The women were asymptomatic and aged between 25 and 35 years.

A total of 2,575 females were examined by transabdominal ultrasound, using Siemens Ultrasound Machine (Sonoline 450 SL, made in Germany) with a 3.5 MHz probe, during a 6-month period.

The uterus was visualized as a pear-shaped anteverted structure superior to the vagina and posterior to the urinary bladder and having different echogenicity according to the phase of the menstrual cycle. Uterine fibroids were identified ultrasonically as distinct ovoid echopenic, nodular masses [Figure 1].

Data derived from the procedure included patient's age, uterine anteroposterior (A/P) diameter, myoma type, myoma location, myoma size, and number of myoma.

Data were analyzed using computerized software, Microsoft Excel (Microsoft, 2010 version, USA) and SPSS 16.0 (Microsoft Corporation, USA) and presented in figures and tables, using comparative percentages. Values were recorded as mean \pm standard error of mean (SEM). The statistical significance of the difference in the mean and SEM ($P < 0.05$) was analyzed based on the two-sample *t*-test.

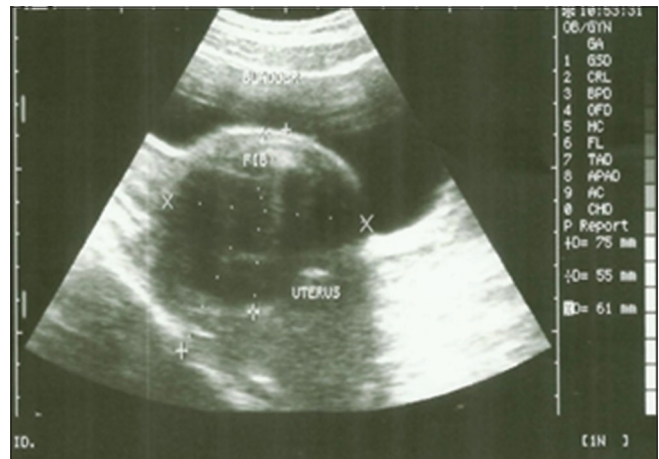

Figure 1: Longitudinal ultrasound scan showing the bladder, uterus, and fibroid (fib). The fibroid was identified as an oval echopenic mass

Informed consent

All procedures followed were in accordance with the ethical standards of the responsible committee on human experimentation (institutional and national) and with the Helsinki declaration of 1975, as revised in 2000. The patient provided written informed consent before enrolment into the study.

RESULTS

Of a total of 2,575 female patients scanned, 176 were diagnosed with myoma, representing a prevalence of 6.83%.

Figure 2 shows the distribution of myoma with respect to gravidarum. 25% of the cases were found to co-exist with viable pregnancies (44/176) while 75% of the patients were nongravid (132/176).

Figure 3 shows the percentage of fibroid type associated with pregnancy: Subserous, 2.27%; pedunculated, 4.54% and intramural fibroid, 93.18%.

Figure 4 shows the analysis of the number of fibroids co-existing with pregnancy. Solitary myoma was associated with 79.55% (35/44) of cases of myoma-associated pregnancy; double myoma was present in 15.91% (7/44) of pregnancies; triple myoma was found in 2.27% (1/44) of cases while instances of ≥ 4 myoma existed in 2.27% (1/44) of cases.

Figure 5 shows the numerical distribution of myoma. Solitary myoma was noted in 59.09% (104/176) of patients while multiple myomas ($n \geq 2$) were present in 40.91% (72/176) of patients. Subclassification of multiple fibroids expressed in Figure 6 shows that 56.94% (41/72) of patients had 2 myoma; 18.06% (13/72) had 3; 25% (18/72) had more than 4 fibroids *in situ*. Only 3.41% (6/176) showed calcific degeneration.

Data on the different types of myoma are expressed in Table 1. Ultrasound examination revealed that most patients had the myoma in varied sites. 7.87% (13/176) had only subserous fibroids, 5.11% (9/176) had only submucous fibroids, 4.55% (8/176) had only

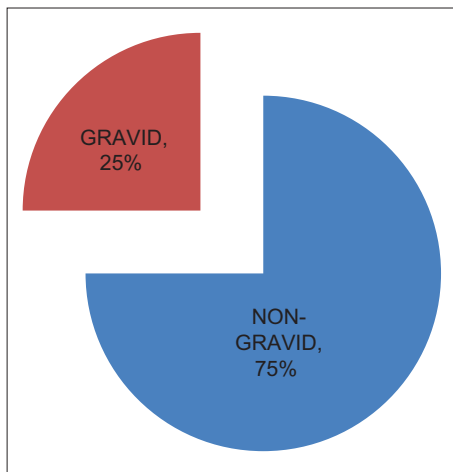


Figure 2: Distribution of myoma in pregnancy

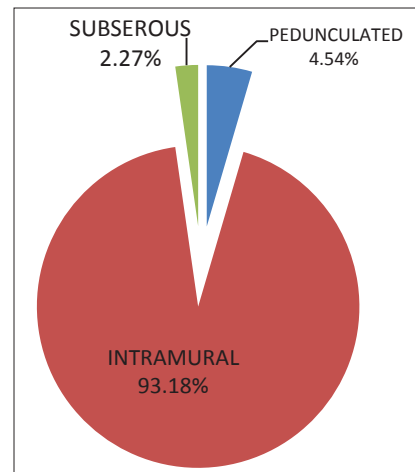


Figure 3: Types of fibroid co-existing with pregnancy

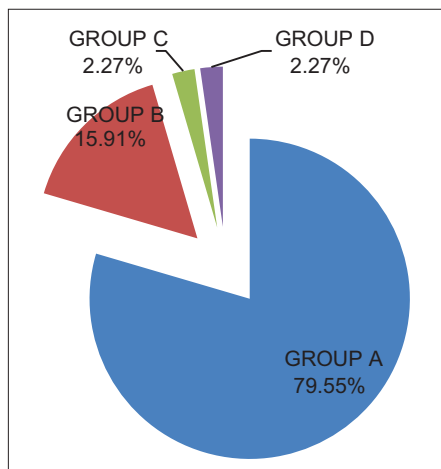


Figure 4: Sub-categorization of number of fibroids co-existing with pregnancy

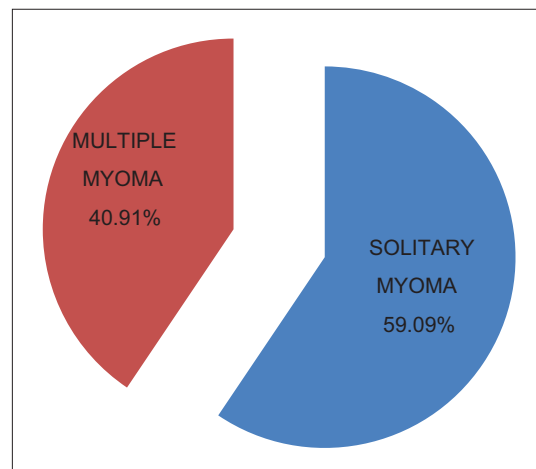


Figure 5: Numerical distribution of myoma

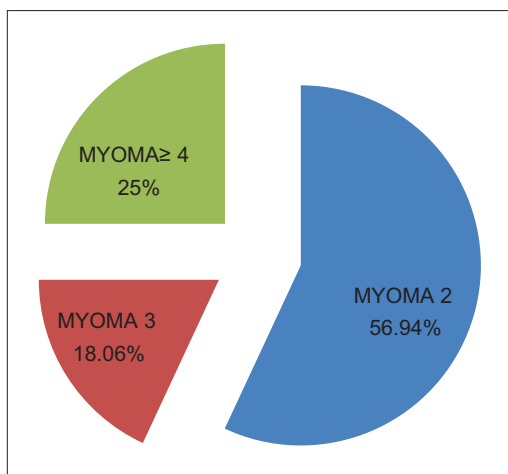


Figure 6: Sub-classification of multiple myoma (myoma 2, n = 41; myoma 3, n = 13; myoma ≥4, n = 18)

pedunculated fibroids while 74.43% (131/176) had only intramural fibroids. Cumulative frequency of myoma location shows that 10.23% (18/176) included subserous, 6.25% (11/176) included submucous, 9.10% (16/176) included pedunculated while 82.39% (145/176) included intramural fibroids.

Data on number of myoma per uterus and mean uterine A/P diameter are shown in Table 2. Patients were classified into four groups A, B, C, and D based on the number of myoma per uterus. Group A had 1 fibroid/uterus, uterine A/P = 6.05 ± 0.17; Group B had two fibroids/uterus, uterine A/P = 7.18 ± 0.27; Group C had three fibroids/uterus, uterine A/P = 6.96 ± 0.33; Group D had more than 4 fibroids/uterus, uterine A/P 8.03 ± 0.32. Results showed that the mean uterine A/P diameter of multiple myomas was significantly larger than that of solitary myoma at P ≤ 0.05.

DISCUSSION

Estimating the overall prevalence of fibroids in the population depends on the population under investigation and the sensitivity and specificity of the methods used to detect fibroids. In this study, ultrasonography estimated a prevalence of 6.83% in asymptomatic Nigerian women. This value is close to what has been reported in other parts of South-West Nigeria: 7.6% and 8.35% were recorded for Ife and Ilesha (both in Osun state), respectively (Oguniyi and Fasuba 1990; Sankaran and Manyonda, 2008); 3.2% for Sagamu, Ogun State (Akinyemi et al., 2004). However, higher values have been reported for other parts of the country, especially the eastern part: 13.6% was recorded in Ebonyi State (Obuna et al., 2008); 19.75% was reported for Irrua, Edo State; 25.9% obtained in Enugu (Ozumba et al., 2011).

Table 1: Location of uterine fibroids as seen with ultrasonography

Myoma type	Only	Cumulative frequency
Subserousal	7.87% (n=13)	10.23% (n=18)
Submucosal	5.11% (n=9)	6.25% (n=11)
Pedunculated	4.55% (n=8)	9.10% (n=16)
Intramural	74.43% (n=131)	82.39% (n=145)

Table 2: Mean±SD values of uterine A/P diameter in patients with myoma

Parameters	Group A (n=69)	Group B (n=34)	Group C (n=12)	Group D (n=17)
Uterine A/P diameter (cm)	6.05±0.17	7.18±0.27*	6.96±0.33*	8.03±0.32*

Values are mean±SEM, n=Number of patients excluding those with co-existing pregnancy, *Significant difference compared with Group A at P<0.05 (Student's t-test). Group A=1 myoma, Group B=2 myomas, Group C=3 myomas, Group D= ≥4 myomas, A/P - Anteroposterior, SD - Standard deviation, SEM - Standard error of the mean

This study revealed the co-existence of pregnancy in 25% of patients with fibroids [Figure 2]. Analysis of the fibroid type revealed: Subserous type to be 2.27%; pedunculated, 4.54%; intramural, 93.18% and submucosal fibroids 0% [Figure 3]. It is noteworthy in this study that submucosal fibroids were not found to co-exist with pregnancy. This support claims that submucosal myomas are associated with infertility in women of childbearing age (Narayan et al., 1994). This might be due to the pressure effect exerted by submucous fibroids on the endometrial cavity. However, genetic factors have been implicated as well. Rackow and Taylor (2010) reported decreased expression of homeobox A10 (*HOXA10*) and homeobox A11 (*HOXA11*) mRNA in uteri with submucosal myoma compared to those in controls with normal uterine cavity and to uteri with intramural myomas. *HOXA10* is a homeobox-containing transcription factor that is essential for embryonic uterine development and is necessary for proper adult endometrial development during each menstrual cycle (Taylor, 2000). *HOXA10* expression is necessary for endometrial receptivity (Taylor et al., 2003).

Of the 44 cases of pregnancy-associated myoma, 35 are of the solitary type, which incidentally had the greater distribution [Figures 4 and 5]. 79.55% of all recorded pregnancies co-existed with solitary myoma, 15.91% co-existed with double myoma, and 2.27% co-existed with three myoma *in situ* while 2.27% of pregnancies were found to co-exist with cases of myoma ≥4.

This indicates the preponderance of solitary myoma in the population; it also shows that nonsubmucosal solitary myoma is not obstructive to conception. Equally apparent from this study is the impression that the chances of conception diminishes with increasing number of myomas and thereby contributing to subfertility and infertility.

This may implicate the type and number of myomas as important factors affecting symptoms and disease progression; and may serve as insight into the dynamics that exist between reproductive dysfunction, noninduced abortions and fibroids.

As noted above, solitary myoma accounted for over half of all the occurrence of fibroids in this study. The prevalence of multiple myomas was 40.91%. Analysis revealed that the occurrence of two fibroids had a prevalence of 56.94%; that of three fibroids was 18.06% while over a quarter of all cases had more than 4 fibroids *in situ* [Figure 6].

In this study, most of the fibroids were found to be intramural in location (74.43%), followed by subserous (7.87%), submucosal (5.11%), and pedunculated (4.55%) [Table 1]. Ezeama *et al.*, (2012) and Akinyemi *et al.*, (2004) also reported a similar trend, though theirs did not account for pedunculated myoma. The implication of this finding with regards to the etiopathogenesis of fibroids is that fibroids start intramuscularly within the myometrium before migrating. This is supported by the work of Tocci *et al.*, (2008) that described the endomyometrial junction, with the aid of magnetic resonance imaging, as the interface between cyclic endometrium and the myometrium and a possible site of origin of submucosal and intramural fibroids.

The mean uterine A/P diameter from previous studies is 2.5 cm and 3.5 cm for nulliparous and multiparous women, respectively (Havens and Sullivan, 2002). Values observed in this study exceeded this standard. Moreover, the mean A/P diameter in this study showed a progressive increase that is correlated with increasing number of fibroids: 6.05 cm for solitary myoma, 7.18 cm for double myoma and 6.96 cm for triple myoma and 8.03 cm for myoma ≥ 4 [Table 2]. According to our result, myoma is associated with increased uterine A/P diameter. Therefore, the sonographic uterine A/P diameter can be a predictive index for the development of myoma.

CONCLUSION

Though our values are higher than those obtained in Europe, the prevalence of myoma in this study is similar to documented values from other parts of South-West Nigeria. Results showed the preponderance of solitary myoma both in pregnant and nonpregnant subjects. Our figures also show submucosal fibroids as contributory to infertility and subfertility. Findings also showed that increased uterine A/P diameter is positively correlated with the presence of myoma and could serve as a predictive index for the presence of fibroids.

REFERENCES

1. Akinyemi B.O., Adewoye B.R., Fakoya T.A. (2004). Uterine fibroids. A review. *Niger J Med* 13 (4):318-29.
2. Arici A., Sozen I. (2000). Transforming growth factor- $\beta 3$ is expressed at high levels in leiomyoma where it stimulates fibronectin expression and cell proliferation. *Fertil Steril* 73 (5):1006-11.
3. Benassayag C., Leroy M.J., Rigourd V., Robert B., Honore J.C., Mignot T.M., *et al.* (1999). Estrogen receptors (ER α /ER β) in normal and pathological growth of the human myometrium: Pregnancy and leiomyoma. *Am J Physiol* 276 (6):E1112-8.
4. Ciavattini A., Di Giuseppe J., Stortoni P., Montik N., Giannubilo S.R., Litta P., *et al.* (2013). Uterine Fibroids: Pathogenesis and interactions with endometrium and endomyometrial junction. *Obstet Gynecol Int* 2013:173184.
5. Divakar H., (2008). Asymptomatic uterine fibroids. *Best Pract Res Clin Obstet Gynaecol* 22 (4):643-654.
6. Ezeama C.O., Ikechebelu J.I., Obiechina N.J., Ezeama N.N. (2012). Clinical Presentation of Uterine Fibroids in Nnewi, Nigeria: A 5-year Review. *Ann Med Health Sci Res* 2 (2):114-8.
7. Fujimota J., Hirose R., Ichigo S., Sakaguchi H., Li Y., Tamaya T. (1998). Expression of progesterone receptor form A and B mRNAs in uterine leiomyoma. *Tumor Biol* 19 (2):126-31.
8. Grings A.O., Lora V., Ferreira D.G., Brum I.S., Corleta H.V.E., Capp E. (2012). Protein expression of estrogen receptors α and β and aromatase in myometrium and uterine leiomyoma. *Gynecologic and Obstetric Investigation* 73(2):113-117.
9. Gupta S., Jose J., Manyonda I. (2008). Clinical presentation of fibroids. *Best Pract Res Clin Obstet Gynaecol* 22 (4):615-26.
10. Havens C.S., Sullivan N.C. (2002). *Manual of Outpatient Gynecology*. 4th ed. Lippincott Williams and Wilkins Publishers, London. 174-5.
11. Kastner P., Krust A., Tureotte B., Stropp U., Tora L., Gronemeyer H., *et al.* (1990). Two distinct estrogen-regulated promoters generate transcripts encoding the two functionally different human progesterone receptor forms A and B. *EMBO J* 9 (5):1603-14.
12. Kempson R.L., Hendrickson M.R. (2000). Smooth muscle, endometrial stromal, and mixed Müllerian tumors of the uterus. *Mod Pathol* 13 (3):328-42.
13. Kjerulff K.H., Langenberg P., Seidman J.D., Stolley P.D., Guzinski G.M. (1996). Uterine leiomyomas: Racial differences in severity, symptoms and age at diagnosis. *J Reprod Med Obstetrician Gynecologist* 41 (7):483-90.
14. Kovács K.A., Oszter A., Göcze P.M., Péter M., Környei J. L., Szabó I. (2001). Comparative analysis of cyclin D1 and oestrogen receptor (α and β) levels in human leiomyoma and adjacent myometrium. *MHR: Basic science of reprod. Medicine* 7 (1):1085-1091.
15. Lippman S.A., Warner M., Samuels S., Olive D., Verellini P., Eskenazi, B. (2003). Uterine fibroids and gynecologic pain symptoms in a population-based study. *Fertil Steril* 80 (6):1488-94.
16. Marshall L.M., Spiegelman D., Barbieri R.L., Goldman M.B., Manson J.E., Colditz G.A., *et al.* (1997). Variation in the incidence of uterine leiomyoma among premenopausal women by age and race. *Obstet Gynecol* 90 (6):967-73.
17. Narayan R., Rajat, Goswamy K. (1994). Treatment of submucous fibroids, and outcome of assisted conception. *J Am Assoc Gynecol Laparosc* 1 (4 Pt 1):307-11.
18. Obuna J.A., Umeora O.U., Ejikeme B.N., Egwuatu V.E. (2008). Uterine fibroids in a tertiary health centre South East Nigeria. *Niger J Med* 17 (4):447-51.
19. Oguniyi S.O., Fasuba O. (1990). Uterine fibromata in Ilesha, Nigeria. *Niger Med Practitioner* 191:93-5.
20. Ozumba B.C., Nzegwu M.A., Nyikam A.A. (2011). Histological patterns of gynecological lesions in Enugu, Nigeria. A five-year review from January 1, 2000 to December 31, 2004. *Adv Biores* 2 (2):132-6.
21. Parker W.H. (2007). Etiology, symptomatology, and diagnosis of uterine myomas. *Fertil Steril* 87 (4):725-36.

22. Payson M., Leppert P., Segars J. (2006). Epidemiology of myomas. *Obstet Gynecol Clin North Am* 33 (1):1-11.
23. Rackow B.W., Taylor H.S. (2010). Submucosal uterine leiomyomas have a global effect on molecular determinants of endometrial receptivity. *Fertil Steril* 93 (6):2027-34.
24. Ross R.K., Pike M.C., Vessey M.P. (1986). Risk factors for uterine fibroids: Reduced risk associated with oral contraceptives. *Br Med J* 293 (6543):359-62.
25. Sankaran S., Manyonda I.T. (2008). Medical management of fibroids. *Best Pract Res Clin Obstet Gynaecol* 22 (4):655-76.
26. Shikora S.A., Niloff J.M., Bistrrian B.R., Forse R.A., Blackburn G.L. (1991). Relationship between obesity and uterine leiomyomata. *Nutrition* 7 (4):251-5.
27. Shimomura Y., Matsuo H., Samoto T., Maruo T. (1998). Up-regulation by progesterone of proliferating cell nuclear antigen and epidermal growth factor expression in human uterine leiomyoma. *J Clin Endocrinol Metab* 83 (6):2192-8.
28. Taylor H.S. (2000). The role of HOX genes in human implantation. *Hum Reprod Update* 6:75-9.
29. Taylor H.S., Daftary G.S., Selam B. (2003). Endometrial HOXA10 expression after Tucci A., controlled ovarian hyperstimulation with recombinant follicle-stimulating hormone. *Fertil Steril* 80 Suppl 2:839-43.
30. Tucci A., Greco E., Ubaldi F.M. (2008). Adenomyosis and endometrial-subendometrial myometrium unit disruption disease are two different entities. *Reproductive BioMedicine Online* 17(2):285-291.
31. Viville B., Charnock-Jones D.S., Sharkey A.M., Wetzka B., Smith S.K. (1997). Distribution of the A and B forms of the progesterone receptor messenger ribonucleic acid and protein in uterine leiomyomata and adjacent myometrium. *Hum Reprod* 12 (4):815-22.
32. Ying Z., Weiyuan Z. (2009). Dual actions of progesterone on uterine leiomyoma correlate with the ratio of progesterone receptor A: B. *Gynecol Endocrinol* 25 (8):520-3.

How to cite this article: ???.

Source of Support: Nil, **Conflict of Interest:** None declared.