

Histological effect of ethanolic leaf extract of *Codiaeum variegatum* on the cerebrum of adult Wistar rats

Elizabeth Finbarrs-Bello, Ogugua Augustine Egwu¹, Vivian Atuadu, Eni Ogonnia Egwu

Department of Anatomy, College of Medicine, Ebonyi State University, Abakaliki, ¹Department of Anatomy, Federal University Ndufu-Alike Ikwo, Ebonyi State, Nigeria

Abstract

Background: Medicinal plants such as *Codiaeum variegatum* are recognized therapeutic agents and sources of the drug. The effect of ethanolic extract of *C. variegatum* was investigated in this study. **Materials and Methods:** Sixteen adult Wistar rats of both sexes weighing between 120 and 180 g were used for the study. They were randomly assigned to four groups 1, 2, 3, and 4 of 4 rats ($N = 4$) per group. The control (group 1) received 0.1 ml of normal saline, while 2, 3, and 4 experimental groups received 200 mg/kg, 400 mg/kg and 600 mg/kg of the leaf extract respectively for 2 weeks. They were sacrificed on the 15th day of the experiment; cerebrum was harvested, processed, and stained using the hematoxylin and eosin histological technique. **Results:** Sections of the cerebrum of the experimental groups showed sparse cellular population, microglia infiltration, focal, and liquefactive necrosis when compared to the control group. **Conclusion:** Ethanolic leaf extract of *C. variegatum* elicits an adverse effect on the cerebrum of adult Wistar rats.

Key words: Cerebral cortex, *Codiaeum variegatum*, liquefaction, microglia, necrosis

INTRODUCTION

In Africa, the use of herbal remedies for curative purposes is rooted in the beliefs and cultures of the people. In recent time, a vast majority of the populace, particularly rural dwellers depend largely on herbal remedies for preventing and treating disease conditions (Hussin, 2001). In addition, many have used various criteria such as minimal side effects, consistent

potency, lack of resistance, affordability, and easy accessibility to qualify the efficacy or potency of herbal medicine (Abbott *et al.*, 2002; Ernst, 2007). However, inappropriate formulation, inadequate knowledge of their mechanism of actions and a drug interaction may potentiate adverse reactions that are sometimes life-threatening or lethal (Shoyinka, *et al.*, 2005).

Codiaeum variegatum also known as the garden croton is an ornamental and medicinal plant (Allan, 2005).

Address for correspondence:

Mrs. Elizabeth Finbarrs-Bello,
Department of Anatomy, College of Medicine,
Ebonyi State University, Abakaliki, Nigeria.
E-mail: finbello@yahoo.com

This is an open access article distributed under the terms of the Creative Commons Attribution-NonCommercial-ShareAlike 3.0 License, which allows others to remix, tweak, and build upon the work non-commercially, as long as the author is credited and the new creations are licensed under the identical terms.

For reprints contact: reprints@medknow.com

Access this article online	
Quick Response Code:	Website: www.jecajournal.org
	DOI: ***

How to cite this article: ***

Traditionally, the leaf concoction of *C. variegatum* is used to treat epilepsy, which is a chronic neurological disorder characterized by uncontrolled or excessive neuronal discharge in any part of the brain or all of the central nervous system (CNS) (Moshi and Kagashe, 2004). It is also accompanied by loss of consciousness and altered brain waves on electroencephalography. Epilepsy can be stimulated by emotional stimuli, fever, drugs, convulsion and loud noise but often occurs in persons genetically predisposed or as a result of traumatic brain injury (Guyton and Hall, 2000; Osim, 2003). Although, can be stopped by fatigue of neurons certain medications have been used to manage epilepsy such as and sometimes surgical excision of the affected area may be required (Guyton and Hall, 2000; Osim, 2003; Bertram *et al.*, 2009).

The major part of the brain affected by epilepsy is the cerebral cortex, an aspect of the brain that coordinate behavioral, motivational, consciousness, memory storage, communication, and control of motor activities across the entire vertebrates' species. Considering the vital role of the cerebrum in humans, the use of *C. variegatum* like the conventional therapy may cause some adverse effect on the cerebrum and consequently compromise its activity. Thus, it is necessary to evaluate the effect of its consumption on this part of the brain.

MATERIALS AND METHODS

Animal

Sixteen adult Wistar rats of both sexes average weight 180 g were used for the study. The rats were purchased from the animal house of the Department of Pharmacy, Faculty of Pharmaceutical Sciences, University of Nigeria, Nsukka. The rats were housed in well-ventilated cages, fed with growers mash manufactured by top feed nig. Plc, twice daily, and allowed water *ad libitum*. They were allowed to acclimatize to the environment of the animal house of Department of Anatomy, Ebonyi State University, Abakaliki for 2 weeks before commencement the extract administration. They were cared for in compliance with applicable guidelines for an animal research study. The animals were randomly assigned to four groups 1, 2, 3, and 4 of four animals per group. Group 1 was taken as the control group while groups 2, 3 and 4 served as the experimental groups.

Preparation of Leaf Extract

The fresh leaves of *C. variegatum* (punctatum spices) were obtained from Ebonyi State University Teaching Hospital Abakaliki, environment. The leaves were identified by Professor O. Onyekwelu of the Department of Applied Biology, Ebonyi State University. The fresh leaves were rinsed with distilled

water and air dried at room temperature. The dried leaves were grinded into fine powder and macerated in ethanol for 24 h. Thereafter the mixture was filtered using a muslin cloth over a funnel, the filtrate was evaporated to dryness by expose to sunlight. The paste form of the extract was stored in a refrigerator at 4°C for the experiment.

Administration of the Leaf Extract

Group 1 (control) received 0.1 ml saline while groups 2, 3, and 4 were given 200 mg/kg, 400 mg/kg, and 600 mg/kg of the extract respectively for a period of 2 weeks by oral intubations using an orogastric tube attach end to the end of an insulin syringe. On the 15th day of the experiment, the animals in all the groups were sacrificed under thiopental anesthesia, the skull was opened and the whole brain dissected out and fixed in 10% formal saline. Thereafter, the cerebrum was removed and processed using the routine histological technique for hematoxylin and eosin.

RESULTS

Histological Findings

In the cerebral section of the control group given 0.1 ml of normal saline, shows normal neurons appearing distinct and glial cells (GC) normal [Figure 1]. Cerebral section of group treated with 200 mg/kg of the *Codiaeum variegatum* leaf extract per body weight revealed sparse cellular population (A) and hypertrophy (H) of the cerebral stroma [Figure 2] when compared with the section of the control group [Figure 1]. Cerebral section of rats treated with 400 mg/kg of *Codiaeum variegatum* leaf extract per body weight shows liquefactive necrosis (LN) and sparse cellular population (A) [Figure 3]. The section of the group treated with 600mg/kg of *Codiaeum variegatum* leaf extract per body weight showed focal liquefaction (FL) surrounded by microglia cells (MC), [Figure 4]. The features were more pronounced and cells were also larger when compared with sections treated with 200 mg/kg and 400 mg/kg of the extract [Figures 2 and 3]. There was also sparse cellular population of neurons (A) when compared with the control group [Figure 1] that received 0.1ml of normal saline

DISCUSSION

The findings revealed necrosis and cellular adaptive changes characterized by inflammation, sparse cellular population, hypertrophy, and liquefactive neurosis in the stroma of the cerebrum. These were evident in sections of the treated groups given 200 mg/kg, 400 mg/kg, and 600 mg/kg compared to the control that received 0.1 ml of normal saline. It is a known fact that the neurons are the specialized basic building blocks of the CNS and are supported by glia cells particularly astrocytes.

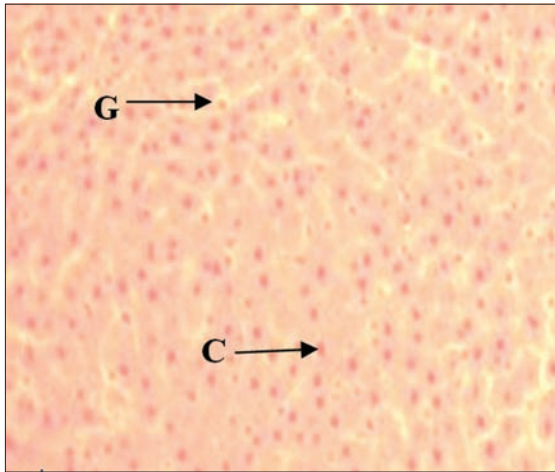


Figure 1: Cerebral section of control rats given 0.1 ml of normal saline, showing normal neurons appearing distinct and glial cells (GC) normal (H and E, x200)

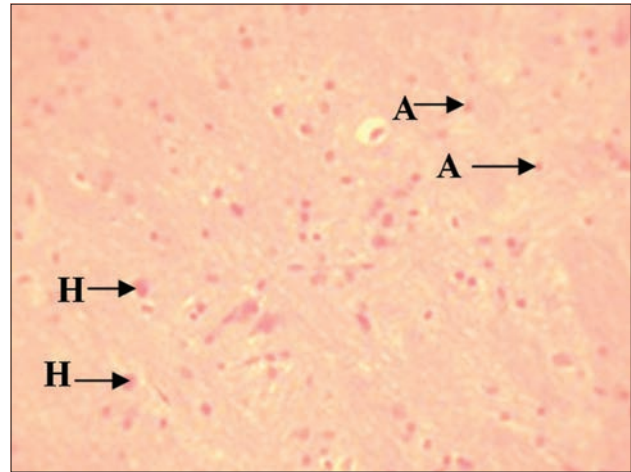


Figure 2: Cerebral section of rats treated with 200 mg/kg of extract. Showing sparse cellular population (A) and hypertrophy (H) of the cerebral stroma H and E, x200

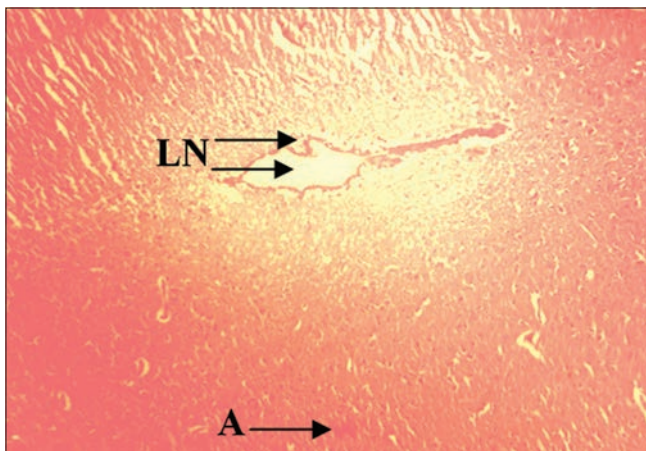


Figure 3: Cerebral section of rats treated with 400 mg/kg of extract, Shows liquefactive necrosis (LN) and sparse cellular population (A) (H and E, x200)

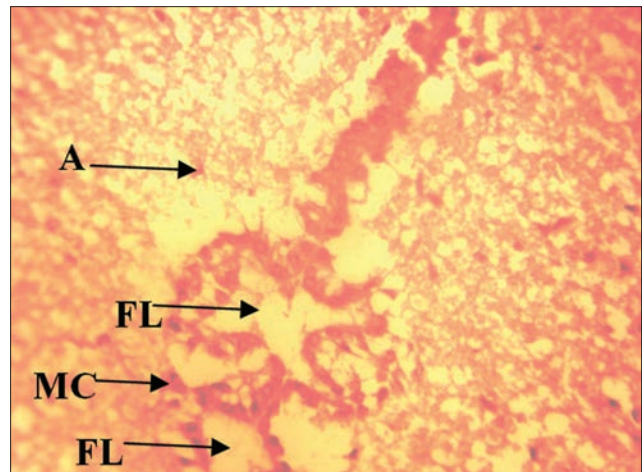


Figure 4: Cerebral section of rats treated with 600 mg/kg extract. Showing focal liquefaction (FL) surrounded by microglia cells (MC) with sparse cellular population (A) (H and E, x200)

Hence, the normal integrity of the neurons and glia are proponent for the normal activities of the cerebrum and CNS at large. However, the cellular changes observed in this study signifies the loss of neuronal integrity and consequently compromises cerebral function. We earlier reported the presence of saponins, phenols, flavonoids, tannins, and glycosides bioactive agents in the leaf extract of *C. variegatum* (Finbarrs-Bello *et al.*, 2014). The effects of *C. variegatum* can be attributed to the presences of the above phytochemical agents.

Abbas and Nelson, (2004) have reported features of degenerative changes that include sparse cellular population, cellular hypertrophy, and liquefactive neurosis. The features were in consistent with the findings in the treated groups that received 200 mg/kg, 400 mg/kg, and 600 mg/kg of the leaf extracts. However, Ankarerona *et al.*, (1995) described necrosis as pathologic and characterized by cell swelling, linked to rapid energy loss and generalized disruption of ionic and internal

homeostasis. These seem to agree with the finding of this study, the ethanolic extract of *C. variegatum* may have acted as a neurotoxin in the cerebral cortex, affecting it cellular integrity.

Financial Support and Sponsorship

Nil.

Conflicts of Interest

There are no conflicts of interest.

REFERENCES

1. Abbas A., Nelson F.K. (2004). Robin and Cotran Pathologie Basis. 7th ed. Elsevier, New Delhi.
2. Abbott N.J., Khan E.U., Rollinson C.M., Reichel A., Janigro D., Dombrowski S.M, *et al.* (2002). Drug resistance in epilepsy: The role of blood brain barrier. Novartis Found Symp 243:38-47.
3. Ankarerona M., Kraine D., Nicotera P., Lipton S.A. (1995). Glutamate-induced neuronal death;a suceession of necrosis or apoptosis depending on mitochondrial function. Neuron15:961-73.

4. Allan H.C. (2005). Croton plant compound combats a second cancer: Pancreatic. *J Pharmacol Exp Ther* 2 (3):105-8.
5. Bertram G.K., Serzan B.M., Anthony J.T. (2009). *Basic and Clinical Pharmacology*. 11th International edition. McGraw Hill Companies Inc., Singapore, p. 371-509.
6. Ernst E. (2007). Herbal medicines: Balancing benefits and risks. *Novartis Found Symp* 282:154-67.
7. Finbarrs-Bello E., Egwu A.O., Esom E., Okefie E.O. (2014). Neurobehavioral and histological effects of Akaki extract on the temporal lobe: Mimicking traditional treatment method. *J Exp Clin Anat* 13 (2):45-9.
8. Guyton A.C., John E.H. (2000). Behavioural and motivational mechanism of the brain, limbic system and hypothalamus. *Textbook of Medical Physiology*. 10th ed. W.B. Saunders Company, USA, p. 678-87.
9. Hussin A.H. (2001). Adverse effects of herbs and drug-herbal interaction. *Malays J Pharm Sci* 2:39-44.
10. Moshi M.J., Kagashe G.A. (2004). Study of the effect of extracts of *Codiaeum variegatum* on picrotoxin- induced convulsions in mice. *Tanzania Med J* 19 (1):11-3.
11. Osim E.E. (2003). The limbic system. *Textbook of Neurophysiology*. 2nd ed. El-Sapphire Ltd., Calabar, Nigeria, p. 177-81, 190-9.
12. Shoyinka S.V., Ikechukwu R.O., Ocheni S.O. (2005). Effect of experimental feeding of *Codiaeum variegatum* leaves on growth, hematology, gonadal and extra-gonadal sperm reserves of adult albino rats. *Comp Clin Path* 19 (1):21-7.