

# Protective effects of ethanolic extract of *Mormodica charantia* leaf on lead nitrate-induced bone marrow toxicity

Richard O. Agbonluai Ehimigbai, Dorothea Baxter Grillo, Gerald Ikechi Eze, Vitalis Chukwuma Ezeuko

Department of Anatomy, School of Basic Medical Sciences, College of Medical Sciences, University of Benin, Benin City, Edo State, Nigeria

## Abstract

**Aim:** The aim of this study was to investigate the effect of ethanolic extract of *Mormodica charantia* leaves on lead-induced toxicity on bone marrow. **Materials and Methods:** A total of 44 adult Wistar rats weighing between 180 g and 220 g were grouped into four groups of eleven rats per group. Animals in Group A (control group) were placed on normal diet for 40 days whereas Group B animals received only 300 mg/kg body weight/day of ethanolic extract of *M. charantia* for 40 days via orogastric tube. Group C animals received only 50 mg/kg body weight lead nitrate via orogastric tube for 40 days. Group D animals received 50 mg/kg body weight lead nitrate and 300 mg/kg body weight/day of ethanolic extract of *M. charantia* for 40 days via orogastric tube. **Results:** The result showed that oral administration of lead nitrate at a dose of 50 mg/kg body weight daily for 40 days significantly induced marked bone marrow injury as revealed by reduction in the activity of the serum erythrocyte count, total leukocyte count, lymphocyte count, monocyte count, mean corpuscular volume and mean corpuscular hemoglobin concentration. The extract also normalized erythrocyte count, total leukocyte count, lymphocyte and monocyte count, mean corpuscular volume and mean corpuscular hemoglobin concentration while the neutrophil count level was decreased. Histologically, lead treated group showed increased fat vacuoles along with significant reduction in primordial blood cell inside bone marrow. Concurrent administration of both lead and the extract caused a restorative effect on the cytoarchitectural structure of the bone marrow. **Conclusion:** In conclusion, this study has shown that the ethanolic extract of *M. charantia* at 300 mg/kg body weight has an ameliorative effect on lead nitrate-induced bone marrow toxicity.

**Key words:** Bone marrow, lead nitrate, *Mormodica charantia*, toxicity

## INTRODUCTION

The last three centuries have witnessed the worst outbreak of lead poisoning among adults, which were occupational in origin, although environmental pollution also reported the adverse effect of lead on health (Jaffery, 2001). Effect of lead nitrate is well documented in mammals, in which it leads to a broad range of physiological, biochemical, and behavioral dysfunctions (Courtois *et al.*, 2003).

Autopsy studies of lead-exposed humans indicate that among soft tissue, liver is the largest repository (33%) of lead, followed by kidney. Lead-induced hepatic damage is mostly rooted in lipid peroxidation and disturbance of the prooxidant–antioxidant balance by generation of

### Address for correspondence:

Dr. Richard O. Agbonluai Ehimigbai,  
Department of Anatomy, School of Basic Medical Sciences,  
College of Medical Sciences, University of Benin, Benin City,  
Edo State, Nigeria.  
E-mail: ehirichard22@yahoo.com

Access this article online	
Quick Response Code:	Website: www.jecajournal.org
	DOI: ***

reactive oxygen species (ROS) (Gurer and Ercal, 2000; Bechara 2004). The presently approved treatment for lead intoxication is to offer chelating agents, such as monoisoamylmeso-2,3-dimercaptosuccinic acid and meso-2,3-dimercaptosuccinic acid, which form an insoluble complex with lead and protect it from biological targets, thereby reducing its toxicity (Flora *et al.*, 2007). However, these chelators are potentially toxic (Flora *et al.*, 2007) and frequently unsuccessful to eliminate lead from all body tissues (Cory-Slechta *et al.*, 1987).

The species, *Momordica charantia*, belongs to the family *Cucurbitaceae* and is commonly referred to as African Cucumber, bitter gourd, balsam pear. In Nigeria, the Yorubas call it Ejinrin-were. The plant contains active components such as momorcharins, gentisic acid, momordenol, momordicin, momordin, cryptoxanthin, momordolol, charantin, charine, momordicins, cucurbitins, cycloartenols, momordicinin, diosgenin, cucurbitanes, elaeostearic acids, erythrodiol, galacturonic acids, gentisic acid, cucurbitacins, goyaglycosides, goyasaponins and multiflorenol (Murakami *et al.*, 2001; Parkash *et al.*, 2002).

Whole plant as well as their seeds, fruits, roots and leaves are commonly used for herbal medicine preparation. Traditionally, *M. charantia* is believed to have carminative, aphrodisiac, and antihelmintic properties and are therefore used in treatment of syphilis, sore, nervous disorder, rheumatism, antimicrobial activity, troubles of spleen, and ophthalmia. It is also believed to be useful in treatment of piles, leprosy, jaundice, and as a vermifuge (Kirtikar and Basu, 2006).

The aim of this study was to evaluate the effects of ethanolic extracts of *M. charantia* leaves on lead nitrate-induced bone marrow toxicity.

## MATERIALS AND METHODS

### Plant Materials Preparation

*Momordica charantia* leaves were harvested from the bush around Ekosodin village in Egor Local Government Area of Edo State, Nigeria. It was identified and authenticated by a curator in the Department of Pharmacognosy, Faculty of Pharmacy, University of Benin, Benin City, Edo State, Nigeria.

The leaves were dried in flat plastic trays in an airy place at ambient temperature away from direct sunlight for 1-week. The completely dried leaves were grounded to fine powdery form using a wooden mortar and pestle. It was thereafter stored in clean stopper bottles. 2.5 L of absolute ethanol (solvent) was used to soak the 8 g of the grinded leaves inside a glass jar for 72 h at room

temperature. The filtrates were then removed from the suspension using cotton wool as a filter.

Thereafter, an evaporating dish containing the filtrates was placed inside an oven invariably evaporating the ethanol solvent from the solution at the temperature of 45°C. The gel-like extract yielded 6.5 g/kg of the leaves and was stored at 4°C in a refrigerator. A known quantity of the leaves extract was dissolved in a measured volume of distilled water whenever needed for the experiments. The concentrated *M. charantia* extract was then given to the Wistar rats at 300 mg/kg body weight for 40 days.

All the preparations were done at the Department of Anatomy, School of Basic Medical Science, College of Medical Sciences, University of Benin, Benin City, Edo State, Nigeria.

### Experimental Animals

Forty-four adult Wistar rats, weighing between 180 g to 220 g were purchased from the animal house section of the Department of Anatomy, School of Basic Medical Sciences, University of Benin, Benin City, Edo State, Nigeria and were used as experimental animals for this study.

The animals were kept in plastic cages for 2 weeks before the experiment for proper acclimatization. The cage was well aerated, cleaned daily and kept free from insects. Food and clean water were served *ad libitum*. They were maintained on standard livestock feed (vital growers feed). The Wistar rats experimental usage was in accordance to the National Institutes of Health Guide for the care and use of laboratory animals (National Institute of Health, 2002 publication, number 83-23, revised 1978).

The Wistar rats were grouped into four groups of 11 animals per group. Group A animals received normal diet for 40 days; Group B animals received 300 mg/kg body weight/day of ethanolic extract of *M. charantia* for 40 days via orogastric tube; Group C animals received 50 mg/kg body weight lead nitrate via orogastric tube for 40 days; Group D animals received 50 mg/kg body weight lead nitrate and 300 mg/kg body weight/day of ethanolic extract of *M. charantia* for 40 days via orogastric tube. The dose lead nitrate used in this study was equivalent to 1/45 of LD<sub>50</sub> (Plastunov and Zub, 2008). The dosage of *M. charantia* leaf extract was given at 300 mg/kg body weight (Thenmozhi and Subramanian, 2011).

The experimental animals were sacrificed via chloroform inhalation after 40 days. The pelvic bones were harvested using a midline abdominal incision and quickly preserved in 10% formal-saline. Blood samples were collected via the abdominal aorta while plasma and red blood cell

were separated by centrifugation before using it for hematological analysis.

### Tissue Processing

The bones were removed from the fixative and decalcified in 10% nitric acid for 7 days. After bone decalcification, the already labeled bone tissues were dehydrated in alcohol, cleared in xylene and impregnate in paraffin. The tissue blocks were then sectioned using a rotary microtome at 5 micron per thickness, dewax in xylene and rehydrate in descending order before staining with hematoxylin and eosin and then observed microscopically.

### Hematological Assays

The platelet count and differential leucocyte counts were determined by method developed by Jain (1986). Total white blood cell count and erythrocyte count were estimated using the improved Neubauer counting chamber under the Olympus binocular electric microscope that is counting by hemocytometric method. Micro-hematocrite method was used in packed cell volume (PCV) estimation. Mean corpuscular volume and mean corpuscular hemoglobin concentration were calculated from PCV.

### Statistical Analysis

Hematological parameters were evaluated for statistical significance. Data are expressed as the mean  $\pm$  standard error of the mean. The data were analyzed by analysis of variance, followed by least square difference using the Statistical Package for the Social Sciences (SPSS), version 17.0 (SPSS, Inc., Chicago, Illinois, USA). The analyzed data were represented tables. The level of significance was set at  $P < 0.05$ .

## RESULTS

### Microscopic Findings

Plate 1 shows photomicrographs of bone marrows in all the experimental groups. Microscopic findings showed that oral administration of *M. charantia* at a dose of 300 mg/kg body weight/day for 40 days resulted in hypercellularity of the bone marrow [Plate 1b] when compared to the control group [Plate 1a]. It was also found that oral administration of lead nitrate at a dose of 50 mg/kg resulted in moderately decreased cellularity in the bone marrow along with moderately increased fat vacuoles [Plate 1c]. Administration of lead nitrate at a dose of 50 mg/kg body weight and *M. charantia* at a dose of 300 mg/kg body weight/day resulted hypercellularity of the medullary cavity of the bone [Plate 1d].

### Haematological Findings

Table 1 shows that neither *M. charantia* nor lead nitrate had a statistically significant ( $P > 0.05$ ) effect on erythrocyte count. *M. charantia* had no statistically significant ( $P > 0.05$ ) effect on the mean corpuscular

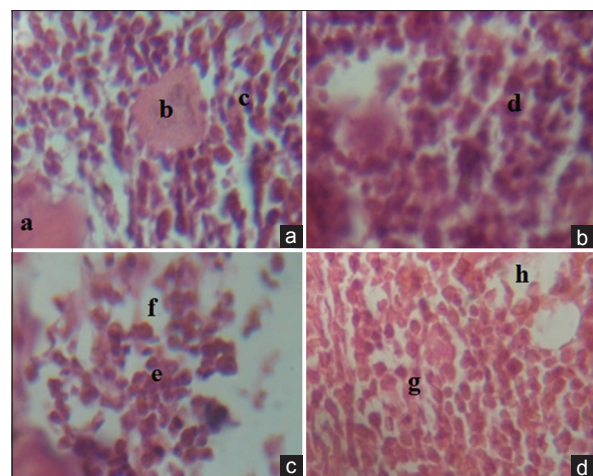
volume, mean corpuscular hemoglobin concentration, platelet count, percentage monocytes, percentage lymphocytes and percentage eosinophils. *M. charantia*, however, significantly reduced ( $P < 0.05$ ) white blood cell count, percentage basophil and percentage eosinophil. Lead nitrate significantly reduced the mean corpuscular volume, mean corpuscular hemoglobin concentration, white blood cell count, platelet count, percentage monocytes, percentage lymphocytes, percentage basophils, percentage neutrophils and percentage eosinophils.

In lead nitrate-treated animals, *M. charantia* significantly increased ( $P < 0.05$ ) mean corpuscular volume, mean corpuscular hemoglobin concentration and percentage eosinophils up to the level of the control animals. It also significantly increased ( $P < 0.05$ ) white blood cell count, platelet count, percentage monocytes, percentage lymphocytes, percentage basophils and percentage neutrophils up to the level of *M. charantia*-treated animals but not up to the control animals.

## DISCUSSION

The outcome of white blood cell count in the lead nitrate-treated rats signifies a reduction in the immune system of the cells. That the toxic effects of lead had been found more often on the teeth (bone), central and peripheral nervous system, hematological and lipid profiles (Balali-Mood *et al.*, 2010). The reduction of platelet count in this study by lead-nitrate in this study is in agreement with earlier findings (Balali-Mood *et al.*, 2010).

The present study showed that lead-nitrate had no effect on the erythrocyte count. This is a variance with an



**Plate 1:** Photomicrograph of rat bone marrow. (a) Bone marrow composed of bones spicule "a," megakaryocyte "b" and other blood cell lines "c" (control group). (b) Bone marrow with high cellularity "d" (treated with 300 mg/kg of *Mormodica charantia* for 40 days). (c) Moderately decreased cellularity in the marrow cavity "e" and moderately increased fat vacuoles "f" (treated with 50 mg/kg of lead nitrate for 40 days). (d) Moderately increased cellularity "g" and moderately reduced fat vacuoles "h" (treated with lead and *M. charantia* for 40 days) (H and E,  $\times 400$ )

**Table 1: Comparison of mean haematological parameters of rat in all experimental groups**

	Control (n=11)	<i>M. charantia</i> only (n=11)	Lead only (n=11)	Lead+ <i>M. charantia</i> (n=11)	P
Mean corpuscular volume (fl)	84.00±2.24 <sup>a</sup>	82.50±2.5 <sup>a</sup>	63.60±2.04 <sup>c</sup>	77.20±1.04 <sup>a</sup>	<0.001
Mean corpuscular hemoglobin concentration (%)	33.70±0.50 <sup>a</sup>	32.70±0.94 <sup>a</sup>	30.30±0.73 <sup>c</sup>	32.60±0.6 <sup>a</sup>	0.011
White blood cell count (/mm <sup>3</sup> )	6600±561.74 <sup>a</sup>	5500±349.60 <sup>b</sup>	2963±36.4 <sup>c</sup>	4890±221.33 <sup>b</sup>	<0.001
Erythrocyte count (/mm <sup>3</sup> )	6.62±0.10 <sup>a</sup>	6.61±0.02 <sup>a</sup>	6.32±0.26 <sup>a</sup>	6.77±0.05 <sup>a</sup>	0.172
Platelet count (/mm <sup>3</sup> )	225.00±18.63 <sup>a</sup>	263.00±14.76 <sup>a</sup>	103.00±5.78 <sup>b</sup>	149.50±7.76 <sup>c</sup>	<0.001
Monocytes (%)	7.40±0.60 <sup>a</sup>	7.10±0.53 <sup>a</sup>	1.32±0.13 <sup>b</sup>	5.60±0.43 <sup>c</sup>	<0.001
Lymphocytes (%)	35.00±3.16 <sup>a</sup>	32.00±3.35 <sup>a</sup>	15.80±1.13 <sup>b</sup>	27.60±1.83 <sup>c</sup>	<0.001
Basophils (%)	0.81±0.07 <sup>a</sup>	0.60±0.03 <sup>b</sup>	0.06±0.05 <sup>c</sup>	0.49±0.07 <sup>d</sup>	<0.001
Neutrophils (%)	55.00±3.42 <sup>a</sup>	45.8±2.05 <sup>b</sup>	29±2.08 <sup>c</sup>	49.8±3.50 <sup>b</sup>	<0.001
Eosinophils (%)	3.75±0.85 <sup>a</sup>	3.80±0.79 <sup>a</sup>	0.66±0.06 <sup>b</sup>	2.80±0.39 <sup>a</sup>	0.002

\*Like superscripts indicates not statistically significant ( $P>0.05$ ) while unlike superscripts indicate statistically significant ( $P<0.05$ ). Post-hoc analysis was done using least square difference. *Mormodica charantia* - *M. charantia*

earlier study by Balali-Mood *et al.* (2010) who indicated pathogenicity of lead anemia.

The reversal potential of *M. charantia* on corpuscular volume, mean corpuscular hemoglobin concentration, percentage eosinophils, white blood cell count, platelet count, percentage monocytes, percentage lymphocytes, percentage basophils and percentage neutrophils in this study is in agreement with the study by Divya *et al.* (2013) who believed that *M. charantia* could act as a new source of natural immune-modulatory and antioxidant agents. This invariably, revealed a better cellular immunity due to the restorative strength of *M. charantia* on the deleterious effect of lead toxicity on white blood cell. Divya *et al.* (2013) indicated the presence of potential free radical scavengers in phenolic extract of *Momordica charantia* leaves that could serve as natural and stable antioxidant that can act as phagocytes at any stage.

The bone marrow showed some histomorphological features, which are well delineated in the photomicrograph [Plate 1]. The hypocellularity of the stem cell lineage in lead nitrate-treated animals is in accordance with previous publication by Balali-Mood *et al.*, (2010). Invariably, the rat also prepared its defense mechanism to ameliorate the effect of the lead nitrate poisoning on the bone marrow by stimulating the proliferation of immune system of the cells.

Bone marrow provides a unique microenvironment for the chronological proliferation, differentiation and release of hematological cells (Kumar *et al.*, 2004). This statement may account for the reason why the bone marrow architecture of control group is well arranged anatomically, but in the lead nitrate only group, there was a distortion of the normal bone marrow architecture.

Furthermore, the *M. charantia*-treated animals showed a significant increase in the population of the hematopoietic stem cell lineage along with a great reduction in the fat vacuoles inside the medullary cavity. These positive

effects might have been generated by the phytochemical nutrients in *M. charantia* as had been proposed by Murakami *et al.* (2001) and Parkash *et al.* (2002).

Moreover, co-administration of lead-nitrate and *M. charantia* resulted in hypercellularity of the bone marrow cells. These might be due to the immuno-proliferative and oxidative strength of the ethanolic extract of *M. charantia* leaves on the erythroid cells and white blood cell precursors in the bone marrow, which enhanced the release of ROS from immune cell by the ethanolic extractions as earlier reported Divya *et al.* (2013).

## CONCLUSION

This study has shown that the ethanolic extract of *M. charantia* at 300 mg/kg body weight has an ameliorative effect on lead nitrate-induced bone marrow toxicity. Further studies are therefore recommended to establish the possibility of administering this extract as a dietary supplement especially to those exposed to environmental toxicants like lead.

## REFERENCES

- Balali-Mood M., Shademanfar S., Rastegar Moghadam J., Afshari R., Namaei Ghassemi M., Allah Nemati H, *et al.* (2010). Occupational lead poisoning in workers of traditional tile factories in Mashhad. North East Iran Int J Occup Environ Med 1 (1):1.
- Bechara E.J. (2004). Lead poisoning and oxidative stress. Free Radic Biol Med 36:22.
- Cory-Slechta D.A., Weiss B., Cox C. (1987). Mobilization and redistribution of lead over the course of calcium disodium ethylene diamine tetra acetate chelation therapy. J Pharmacol Exp Ther 243 (3):804-13.
- Courtois E., Marques M., Barrientos A. (2003). Lead-induced down-regulation of soluble guanylate cyclase in isolated rat aortic segments mediated by reactive oxygen species and cyclo-oxygenase-2. J Am Soc Nephrol 14 (6):1464-70.
- Divya D., Hettiarachchy N.S., Ganesh V., Kanna A., Rayaprolu S. (2013). Phenolic extract from leaves of *Momordica charantia* with antioxidant properties. J Agric Sci Appl 2 (1):28-34.
- Flora S.J., Saxena G., Mehta A. (2007). Reversal of lead-induced neuronal apoptosis by chelation treatment in rats: Role of ROS and intracellular Ca<sup>2+</sup>. J Pharmacol Exp Ther 322 (1):108-16.

7. Gurer H., Ercal N. (2000). Can antioxidants be beneficial in the treatment of lead poisoning? *Free Radic Biol Med* 29 (1):927-45.
8. Jaffery F.N. (2001). Current Status of Lead Poisoning in India. Available from: <http://www.leadpoisoning.net> [Last accessed on 2004 Dec 21].
9. Jain W.C. (1986). Schalm's Veterinary Haematology. 4<sup>th</sup> ed. Lea and Febiger, Philadelphia, 69-71.
10. Kirtikar K.R., Basu B.D. (2006). Indian Medicinal Plants. 2<sup>nd</sup> ed., Vol. 2. International Book Distributors, Dehradun, 1130.
11. Kumar V., Abbas A.K., Fausto N. (2004). Diseases of organ system. Robins and Contran Pathologic Basis of Disease. 7<sup>th</sup> ed., Vol. 19. Philadelphia, Pennsylvania, Elsevier Saunders, 622.
12. Murakami T., Emoto A., Matsuda H., Yoshikawa M. (2001). Structures of new cucurbitane-type triterpene glycosides, goyaglycosides-a, -b, -c, -d, -e, -f, -g, and -h, and new oleanane-type triterpene saponins, goyasaponins I, II, and III, from the fresh fruit of Japanese *Momordica charantia*. *Chem Pharm Bull* 49 (1):54-63.
13. National Institutes of Health, NIH. (1978). Guide for the Care and Use of Laboratory Animals (NIH Publication No. 83-23). National Institutes of Health, Bethesda, MD, USA.
14. Parkash A., Ng T.B., Tso W.W. (2002). Purification and characterization of charantin, a napin-like ribosome-inactivating peptide from bitter melon (*Momordica charantia*) seeds. *J Pept Res* 59 (5):197-202.
15. Plastunov B., Zub S. (2008). Lipid peroxidation processes and antioxidant defense under lead intoxication and iodine-deficient in experiment. *Atrum Univ Mariae Curie Sklodowska Lublin Pol* 21:215-7.
16. Thenmozhi J., Subramanian P. (2011). Antioxidant potential of *Momordica charantia* in ammonium chloride-induced hyperammonemic rats. *Evid Based Complementary Alternat Med* 2011:612023.

**How to cite this article:** ???.

**Source of Support:** Nil, **Conflict of Interest:** None declared.