

# Anatomical investigation on the appendicular skeleton of the cattle egret (*Bubulcus ibis*)

Hamdy Mahmoud Rezk

Department of Anatomy and Embryology, Faculty of Veterinary Medicine, Cairo University, Egypt

## Abstract

**Introduction:** The Cattle Egret (*Bubulcus ibis*) is a cosmopolitan species of heron (family Ardeidae) found in the tropics, subtropics and warm temperate zones. It is the only member of the monotypic genus *Bubulcus*. Cattle egret is popular for its role in the bio-control of cattle parasites and land pests. **Materials and Methods:** The present study was conducted on five adult, apparently healthy, cattle egrets. The birds were euthanized and the skeletons were prepared by the cold maceration method. **Results:** The appendicular skeleton of the cattle egret consists of the pectoral (shoulder) girdle and appendage, and pelvic girdle and appendages. The pectoral girdle comprises the long flat scapula, coracoid bone, and the united paired clavicles. Canalis triosseum is a canal formed by the attachment of the three bones of the pectoral girdle. The furcula formed fibrous connection with the sternum. The radius and ulna have the same length. The wrist comprises two carpal bones, carpometacarpus and three digits. The pubic bones are not fused ventrally. The pes consists of tibiotarsus, tarsometatarsus and four pedal digits. The tibiotarsus is longer than the femur. The spur is not found in the male bird. **Conclusion:** The skeleton of the cattle egret has a unique conformation that accommodates its ability to flight as well as being an insectivorous animal.

**Key words:** Anatomy, bone cleaning, cattle egret, limbs, skeleton, synsacrum

## INTRODUCTION

The cattle egret (*Bubulcus ibis*) is a cosmopolitan species of heron (family *Ardeidae*) found in the tropics, subtropics, and warm temperate zones. It is the only member of the monotypic genus *Bubulcus*, cattle egret is popular for its role in the bio-control of cattle parasites and land pests, it feeds

on a wide range of prey, particularly insects and moths as well as spiders, frogs, earth-worms, and fishes and is locally distributed in Nile Delta and Valley About Shafey (2012).

The importance of cattle egret to the farmer has initiated an increasing interest to establish more accurate and specific anatomical facts about the skeleton of cattle egret.

The available anatomical literatures concerning this subject are extensively reviewed, but the cattle egret skeleton is rather scanty. Therefore, it appeared that it received the least interest. The present study was conducted to investigate in details the specific structures of the skeleton of the cattle egret.

### Address for correspondence:

Dr. Hamdy Mahmoud Rezk,  
12, Cairo University Street, Giza-12211, Egypt.  
E-mail: hamdyrezk81@cu.edu.eg

| Access this article online |                                 |
|----------------------------|---------------------------------|
| Quick Response Code:       | Website:<br>www.jecajournal.org |
|                            | DOI:<br>***                     |

## MATERIALS AND METHODS

The present study was conducted on five adult, apparently healthy, cattle egrets. The birds were euthanized, and then eviscerated, skinned and muscles were removed from the skeleton. The specimen was soaked in cold water with

0.03% ammonia solution for 24 h to remove blood and making the bones white (Tahon *et al.* 2013).

The wings and the hind limbs were skinned and fleshed with leaving the joints intact, and the toes were inserted in boiling water for 5 min then scratched till the complete removal of skin. The wings and hind limbs were soaked for 14 days in a strong solution of ammonia (90%). The specimens were checked every 2 days then rinsed and brushed carefully with toothbrush to remove the remaining flesh. The previous step was repeated every 2 days with scraping and trimming any tendons on the plantar surface of the feet. The specimens were rinsed in dilute Clorox® to remove the odor of ammonia (Tahon *et al.* 2013).

The nomenclature used in this study was that given by the Nomina Anatomica Avium by Baumel *et al.* (1993).

## RESULTS


### Skeleton of the Forelimb

Bones of the pectoral girdle are composed of three pairs of bones, the scapulae, the coracoids and the fused clavicles.

Scapula [Figure 1/1] lies against the upper part of the thoracic wall, parallel to the vertebral column. Its caudal narrow extremity [Figure 1/2] extends to the level of the ilium while the cranial extremity [Figure 1/3] is large, articulates with the clavicle, coracoids, and the head of the humerus.

### Coracoideum

The coracoid bone [Figure 1/4] is short, thick bone, extends from the shoulder joint and articulates with the sternum with its spatula shaped distal end [Figure 1/5]. The proximal extremity [Figure 1/6] attaches to the clavicle by connective tissue. It carries the glenoid process



**Figure 1:** 1-Scapula, 2-Extremitas caudalis scapulae, 3-Extremitas cranialis scapulae, 4-Coracoideum, 5-Extremitas sternalis coracoidei, 6-Extremitas omalis coracoidei, 7-Facies articularis humeralis, 8-Canalis triosseus, 9-Clavicula, 10-Hypocleidium

which forms the glenoid cavity [Figure 1/7] with the glenoid process of the scapula for lodging the head of the humerus. Between the attachment of the scapula and clavicle, there is the triosseal canal [Figure 1/8] for the passage of the tendon of the supracoracoid muscle.

### Claviculae

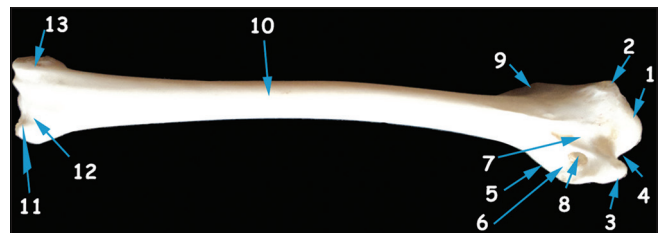
The clavicles [Figure 1/9] are narrow strap-like curved bones which fuse into a single wishbone (furcula). The proximal end of the clavicular bone unites with the scapulae and the coracoid bone. The fused ventral ends continue as small bony plate, the hypocleidium [Figure 1/10] which connects to the cranial sterni of the sternum by fibrous joint.

### The wing bones

The skeleton of the wings consists of the humerus, the ulna and the radius, the wrist or carpus, the metacarpus and the digits (Fingers).

The humerus [Figure 2 and 3] is the strongest of the wing bones. It is flat, expanded at both ends and tubular along its shaft. The proximal extremity carries a large ovoid head (caput humeri) [Figures 2 and 3/1]. Dorsal to the latter lies the dorsal tubercle [Figures 2 and 3/2] which continuous as the prominent lateral tubercular crest (deltoid crest) [Figures 2/9 and 3/6]. The ventral tubercle [Figures 2 and 3/3] is slightly larger, and is separated from the humeral head by a deep capital groove [Figures 2 and 3/4]. Distal to the latter lies the coracobrachial groove [Figure 2/7]. The ventral tubercle is continuous caudally as the bicipital crest [Figures 2 and 3/5]. Below the ventral tubercle lies the deep pneumotricipital fossa [Figures 2/6]. The latter fossa contains large pneumatic foramina (foramen pneumaticum) [Figures 2/8].

The distal extremity [Figure 3/7] presents the flexor process [Figure 2/11] on its caudal surface and comprises the larger ulnar condyle and smaller radial condyle [Figure 3/8] for articulation with the ulna and both radius and ulna respectively forming the elbow joint. The two condyles are separated by the intercondylar notch (incisura intercondylaris) [Figure 3/9].



**Figure 2:** 1-Caput humeri, 2-Tuberculum dorsal, 3-Tuberculum ventral, 4-Incisura capitis humeri, 5-Crista bicipitalis, 6-Fossa pneumotricipitalis, 7-Sulcus coracobrachialis, 8-Foramen pneumaticum, 9-Crista deltopectoralis, 10-Corpus humeri, 11-Proc. flexorius, 12-Fossa olecrani, 13-Epicondylus dorsalis

The ulnar epicondyle [Figure 3/12] and radial epicondyle [Figure 2/13 and 3/11] lie external to the corresponding condyles. In addition; the caudal aspect of the humeral distal end presents a relatively wide and shallow olecranon fossa [Figure 2/12].

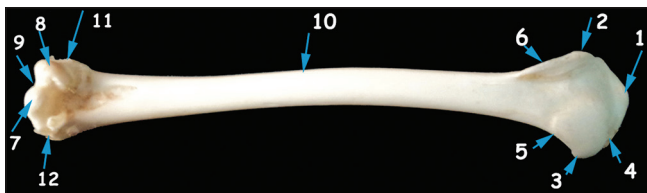
Ulna and radius [Figure 4 and 5] constitute the bones of the forearm. The ulna is thicker than the radius. The cylindrical shaft of ulna [Figures 4 and 5/1] is slightly curved proximally leaving a wide interosseous space [Figures 4 and 5/2] between it and the radius. The shaft present small raised projections [5/4] indicates the origin of the secondary follicles of the wing feathers. The proximal end of ulna carries the olecranon [Figures 4 and 5/3] and two concave articular surfaces for the condyles of the humerus [Figure 4/4] as well as a radial articular facet.

The distal end of the ulna is trochlear in shape [Figure 4 and 5/5]. It consists of a small cranial condyle that articulates with the ulnar carpal bone and relatively large caudal condyle that articulates with both ulnar carpal and radial carpal bones. On the distal end of the ulna, there is a small radial sulcus (sulcus radialis) to form the distal radioulnar joint.

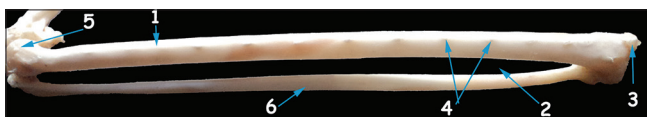The radius [Figure 4 and 5] is a small, rod-like bone. Its proximal extremity represents the head of the bone (caput radii) [Figure 4/7] which articulates with the humerus, as well as the ulna. The shaft of the radius is slightly curved [Figure 4 and 5/6]. The distal end of the radius bears the radiocarpal articular surface for articulation with radial carpal bone. The distal ends of the radius and ulna are separated by the radioulnar interosseous ligament.

#### Ossa carpi

The wrist [Figures 6 and 7] consists of two carpal bones; the ulnar carpal bone [Figure 7/1] and radial



**Figure 3:** 1-Caput humeri, 2-Tuberculum dorsal, 3-Tuberculum ventral, 4-Incisura capitis humeri, 5-Crista bicipitalis, 6-Crista deltopectoralis, 7-Condylus ventralis humeri, 8-Condylus dorsalis humeri, 9-Incisura intercondylaris, 10-Corpus humeri, 11-Epicondylus dorsalis, 12-Epicondylus ventralis



**Figure 5:** 1-Corpus ulnae, 2-Spatium interosi, 3-Olecranon, 4-Papillae remigales ventrales, 5-Trochlea carpalis, 6-Corpus radii

carpal bone [Figure 6/1]. The U-shaped ulnar carpal bone (os carpi ulnare) is situated in the caudal aspect of the wrist region, and it articulates proximally with ulna while distally with the carpometacarpal bone. The radial carpal bone (os carpi radiale) is rectangular in shape, situated on the cranial aspect of the wrist. It articulates proximally with the distal end of the radius and the ulna and distally with the carpometacarpus.

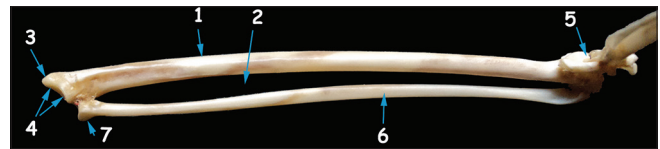#### Carpometacarpal bones

The distal row of carpal bones fuse with the proximal end of the metacarpus forming the carpometacarpal bones [Figures 6 and 7]. The proximal end of this compound bone bears the cranial and the caudal carpal fossae, the carpal trochlea as well as a strong pisiform process (processus pisiformis) [Figure 6/2] is projected from the palmar surface of the proximal end of the carpometacarpus.

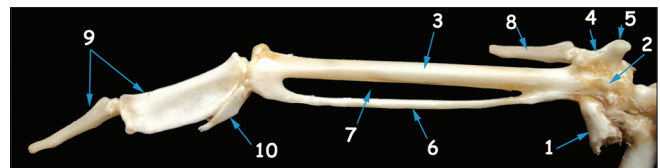
From the compound carpometacarpus, three carpometacarpal bones extend distally. The third carpometacarpal bone (major carpometacarpus) [Figures 6/3 and 7/2] is the largest and strongest of them. From its proximal radial end projects, a small projection represents the second carpometacarpal bone (alular carpometacarpus) [Figures 6/4 and 7/3] that carries the extensor process [Figures 6/5 and 7/4] on its proximal end. The fourth carpometacarpus [Figures 6/6 and 7/5] is a thin arched bone, fuses proximally and distally with the third carpometacarpus leaving a large interosseous space [Figures 6/7 and 7/6].

#### Ossa digitorum manus (digits of wing)

There are three digits in the wing articulating proximally with the corresponding carpometacarpal bones. The second digit [Figures 6/8 and 7/7] is also called thumb or pollex consists of one long proximal phalanx. It articulates proximally with the second carpometacarpus. The third digit [Figures 6/9 and 7/8] is the longest and strongest digit; it articulates with the distal end of the



**Figure 4:** 1-Corpus ulnae, 2-Spatium interosi, 3-Olecranon, 4-Proc. cotylaris dorsalis, 5-Trochlea carpalis, 6-Corpus radii, 7-Caput radii



**Figure 6:** 1-Os carpi radiale, 2- Processus pisiformis, 3-Os metacarpale majus, 4- Os metacarpale alulare, 5- Proc. extensorius, 6-Os metacarpale minus, 7-Spatium intermetacarpale, 8- Phalanx digiti alulae, 9-Phalanx digiti majoris, 10-Phalanx digiti minoris

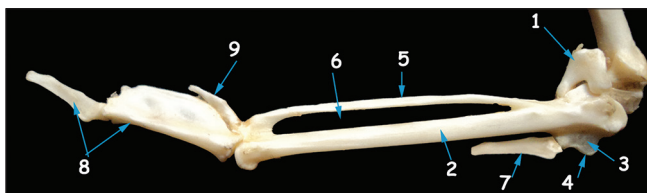
third carpometacarpus and consists of two phalanges. The first phalanx (proximal) is the larger and has thick cranial border and a sharp curved edge. The distal phalanx is in the form of a pointed cone. The fourth digit (the minor digit) [Figures 6/10 and 7/9] is had only one phalanx which articulates with the distal end of the fourth carpometacarpus.

### Skeleton of the Pelvic Limb

The pelvic girdle is formed by the fusion of the two hip bones (os coxae) with the synsacrum. Each hip bone is formed by the ankylosis of ilium, ischium, and pubis.

Ilium is an elongated bone; it has two parts; a long preacetabular part [Figures 8, 9 and 10/1] and a short, broad postacetabular part [Figure 8/2]. The dorsal surface of the preacetabular part presents a deep dorsal iliac fossa while its ventral surface is excavated to accommodate the cranial division of the kidney. In addition, the dorsal border of the preacetabular part forms the dorsal iliac crest (crista iliaca dorsalis) [Figure 10/2] while, the lateral border forms the lateral iliac crest (crista iliaca lateralis) [Figures 8/3, 9/2 and 10/3]. The lateral edge of the postacetabular ilium bears the dorsolateral iliac crest [Figures 8 and 10/4].

The acetabulum is a circular bony ring formed by the ilium and ischium [Figure 10/5]. On the floor of the acetabulum is the large acetabular foramen [Figure 10/6]. Just caudal to the acetabulum is a large elliptical ilio-ischiatic foramen [Figures 10/7], and in addition caudoventral to the acetabulum a smaller oval Obturator foramen [Figures 9 and 10/8]. The obturator process [Figure 10/9] partially separates the obturator foramen from the ischiopubic fenestra [Figures 9/3 and 10/10]. A strong bony prominence representing the antitrochanter [Figure 10/11] is presented caudodorsal to the acetabulum. The renal fossa [Figure 9/4] is a deep depression located ventrally on each side of the body of synsacrum. Its cranial smaller part is the ischiatic fossa, which contains the middle division of the kidney and the lumbosacral plexus. While the larger, deeper caudal part of the renal fossa is the pudendal fossa, which accommodates the caudal division of the kidney. The renal fossa continued caudally as an invagination between the postacetabular ilium and the ischium to form the renal caudal recess [Figure 9/5].



**Figure 7:** 1-Os carpi ulnare, 2-Os metacarpale majus, 3-Os metacarpale alulare, 4-Proc. extensorius, 5-Os metacarpale minus, 6- Spatium intermetacarpale, 7-Phalanx digiti alulae 8-Phalanx digiti majoris, 9-Phalanx digiti minoris

### Ischium

The ischium [Figures 9/6 and 10/12] is a long bony plate situated caudal and ventral to the ilio-ischiatic foramen. Its cranial thick part forms most of the acetabulum while its caudal part fuses with the ilium to form a broad bony plate. The short terminal process which projects from the caudoventral part of the caudal border of the ischium forms the ischiatic terminal process (ischiatic angle) [Figure 9/7] which connects with the pubis by connective tissue.

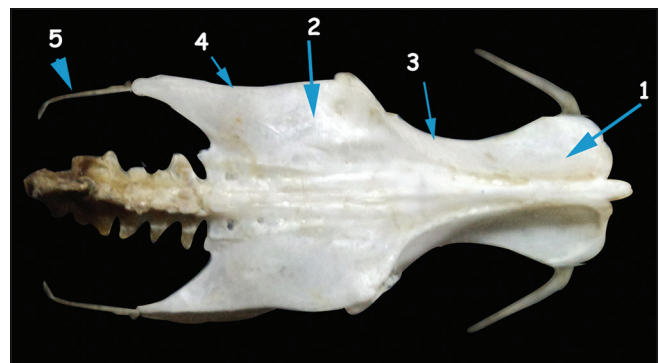
### Pubis

The pubis [Figures 8/6, 9/8 and 10/13] is a thin, rib-like bony rod, runs closely parallel to the ventral border of ischium.

### Bones of the Pelvic Limb

#### Femur

The femur [Figures 11 and 12] is a strong tubular bone. Its proximal end comprises ill-developed trochanter [Figures 11 and 12/1], the hemispherical head of femur [Figures 11 and 12/2]. Between them, is the antitrochanter articulation surface (facies articularis antitrochanterica) [Figures 11 and 12/3]. The trochanter of the femur articulates with the antitrochanter of the ilium. The head of the femur contains fovea capitis [Figures 11 /4] on its medial aspect and articulates with acetabulum to form hip joint. In addition, the femoral trochanter carries the trochanteric crest [Figures 12 /5] on its cranial border. The distal extremity of the femur is very large and bears on its cranial surface the trochlea of the femur, which consists of the medial condyle [Figures 12 /6] and lateral condyle [Figures 12 /7] separated by a wide intercondylar sulcus (patellar sulcus) [Figures 12/8]. Each condyle bears a small epicondyle. The medial condyle extends proximally as a thin ridge to form the medial supracondylar crest [Figures 12 /9] and continues proximally on the caudal surface as the caudal intermuscular line (linea aspera) [Figures 11 /5]. The lateral condyle of the trochlea extends more distal and is divided caudally into two ridges forming the fibular trochlea [Figures 11 /6].



**Figure 8:** 1-Pars preacetabularis ilii, 2-Pars postacetabularis ilii, 3-Crista iliaca lateralis, 4- Crista dorsolateralis ilii 5-Pubis

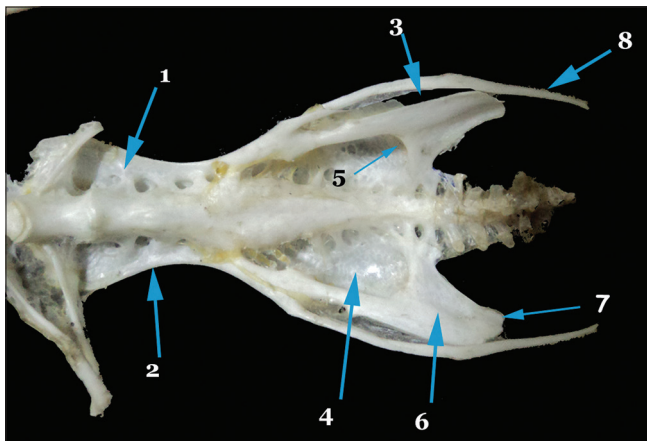


## Patella

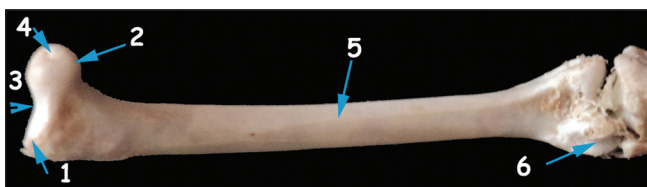
The patella [Figure 12/12] appears as a small, ovoid sesamoid bone that accommodated to the intercondylar sulcus (Patellar sulcus) and glides over the femoral trochlea where it forms the knee cap.

## Tibiotarsus

The tibiotarsus [Figures 13 and 14] is strong long bone formed by fusion of the distal end of the tibia with the proximal row of the tarsal bones. It is longer than the femur. Its proximal end has lateral and medial condyles for articulation with the femur. Distal to lateral condyle toward the lateral surface found the tibial articular facet [Figures 13 /1] for articulation with the fibula. The proximal end of tibiotarsus also possesses a large, sharp cranial cnemial crest [Figure 13/2]. The tuberos lateral cnemial crest [Figure 13/3] is located on the lateral side of the proximal end of the tibiotarsus. Intercnemial sulcus (sulcus intercnemialis) [Figure 13/4] is the wide longitudinal sulcus between the cranial and lateral cnemial crests while the patellar crest [Figure 13/5] is the oblique crest connecting the proximal ends of the two latter crests. The caudal surface of the proximal end of tibiotarsus has the flexor fossa [Figure 14/1] distal to the lateral condyle. The interosseous foramen [Figures 13/6 and 14/2] was a small vertical foramen distal to the flexor fossa and between the head of fibula and tibiotarsus.



**Figure 9:** 1-Pars preacetabularis ilii, 2-Crista iliaca lateralis, 3-Fenestra ischiopubica, 4-Fossa renalis, 5-Recesses caudalis foosae, 6-Ischium, 7-Proc. terminalis ischii, 8-Pubis



**Figure 11:** 1-Tochanter femoris, 2-Caput femoris, 3-Facies articularis antitrochanterica, 4-Fovea lig. Capitis, 5-Linea aspera, 6-Trochlea fibularis

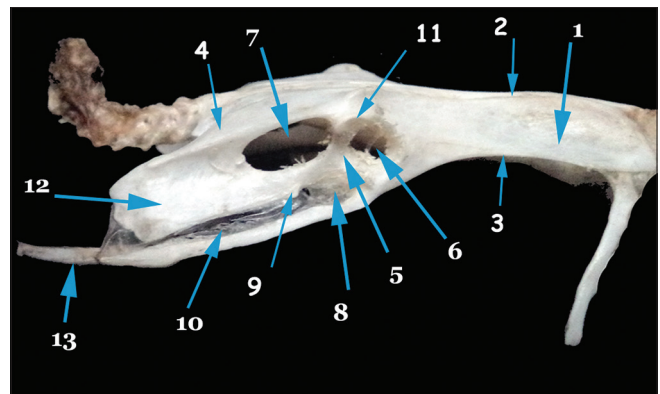
The caudal surface of the distal end of tibiotarsus carries the tibial cartilage trochlea [Figure 14/3] for articulation with the tibial cartilage. On the distal end of tibiotarsus at the cranial surface found lateral condyle [Figure 13/7] and medial condyle [Figure 13/8] of the tibiotarsus. On either sides of the distal end found shallow depressions called lateral and medial epicondyles [Figures 13 /9 and 14/4]. A deep passage on the cranial surface of tibiotarsus proximal to its distal condyles is called the extensor canal [Figure 13/10]. This canal is covered by the supratendinal bridge [Figure 13/11] which appears as a bony bridge over the canal. Extensor sulcus [Figure 13/12] is the longitudinal groove leading to the extensor canal and found proximal to the supratendinal bridge.

## Fibula


The fibula [Figures 13/13 and 14/5] is a reduced long bone on the lateral side of tibiotarsus, which has a prominent large head (capitulum fibulae) [Figures 13/14 and 14/6]. On its medial side has a fibular articular facet for articulation with the tibiotarsus. The shaft of the fibula is a thin rod like with pointed end called spina fibulae [Figures 13/15 and 14/7] and extends 2–3 cm on the shaft of the tibiotarsus.

## Tarsometatarsus

The tarsometatarsus [Figures 15 and 16] is formed by metatarsal bones II, III, IV which are fused



**Figure 10:** 1-Pars preacetabularis ilii, 2-Crista iliaca dorsalis, 3-Crista iliaca lateralis, 4-Crista dorsolateralis ilii, 5-Acetabulum, 6-Foramen acetabuli, 7-Foramen Ilioschiadicum, 8-Foramen obturatum, 9-Proc. obturatorius, 10-Fenestra ischiopubica, 11-Antitrochanter, 12- Ischium, 13-Pubis



**Figure 12:** 1-Tochanter femoris, 2-Caput femoris, 3-Facies articularis antitrochanterica, 4-Fovea lig. Capitis, 5-Crista trochanteris, 6-Condylus medialis, 7-Condylus lateralis, 8-Sulcus patellaris, 9-Cristis supracondylaris medialis, 10-Linea aspera, 11-Trochlea fibularis, 12-Patella

with each other and with the distal tarsal bone. Metatarsal (I) [Figures 15 and 16/1] is a rudimentary, small bone which has a ligamentous attachment ventromedially with tarsometatarsus. The proximal end of tarsometatarsus carries concave articular surfaces called lateral cotyla [Figure 15/2] and medial cotyla [Figure 15/3]; they articulate with the distal condyles of tibiotarsus. A protuberance found between them called intercotylar eminence [Figure 15/4].

On the planter surface of the proximal end of tarsometatarsus found hypotarsus (calcaneus) is formed mostly by the distal tarsal bone and it consists of three longitudinally directed crests which are called lateral, intermediate and medial crests of hypotarsus [Figure 16/2]. A canal is found between the medial and intermediate crests [Figure 16/3]. On the planter surface of the shaft found a longitudinal groove called flexor sulcus. The latter are bounded by sharp, prominent lateral and medial planter crests. The dorsal surface of the proximal end bears an excavation, distal to its cotyla called dorsal infracotylar fossa (fossa infracotylaris dorsalis) [Figure 15/5] where three proximal vascular foramina [Figure 15/6] open in it. In addition, the longitudinal extensor sulcus [Figure 15/7] is found on this surface.

The distal end of tarsometatarsus has three articular trochlea of the metatarsal bone II, III and IV [Figure 15/8]. Lateral and medial intertrochlear notches [Figure 15/9] are present between trochlea.

### Ossa Digitorum Pedis

The pedal digits [Figures 15 and 16] are four digits; the first digit is directed in a medial and plantar direction and consists of two phalanges [Figures 15/10 and 16/4], the second digit points forward and consist of three phalanges [Figures 15/11 and 16/5], the third digit [Figures 15/12 and 16/6] consists of four phalanges and the fourth digit consists of five phalanges [Figures 15/13 and 16/7]. The distal phalanx of each digit has a claw-shape which forms the bony core of the keratinized claw. The other phalanges have concave articular surfaces proximally and a trochlea distally.

## DISCUSSION


Concerning the scapula, it is a flat elongated bone with sharp. These findings simulated the observations of Nickel *et al.* (1977) and Dyce *et al.* (2002) and Tahon *et al.* (2013) in chicken.

In agreement with Dyce *et al.* (2002), Tully *et al.* (2003) and Tahon *et al.* (2013) in chicken the humerus is short, flat at both ends and its proximal extremity carries dorsal and ventral tubercles.

In agreement with the description of Nickel *et al.* (1977) the ulna and radius are about of equal length. On the other hand, Tully *et al.* (2003), Akers and Denbow (2008) and Tahon *et al.* (2013) in chicken mentioned that the ulna is larger and longer than the radius.

The olecranon is a pointed process on the proximal end of the ulna for the muscle attachment. On the other hand, Barnett and Lewis (1958) mentioned that the olecranon is lacking in some birds.

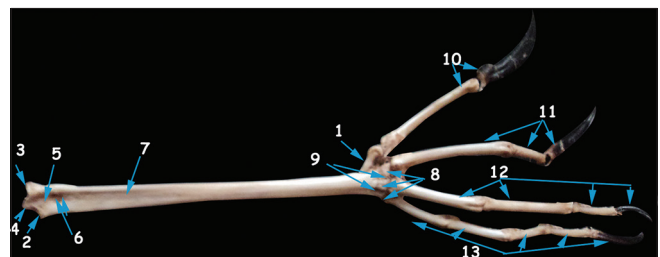
In accordance with Hinchliffe (1985) and Tahon *et al.*, (2013) in chicken the adult proximal carpal bones are the radial (os carpi radiale) and the ulnar (os carpi ulnare),



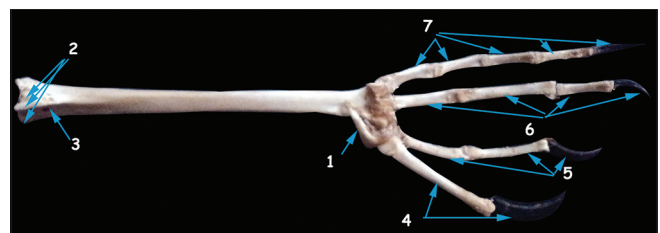
**Figure 13:** 1-Facies articularis fibularis, 2-Crista cnemialis cranialis, 3-Crista cnemialis lateralis, 4-Sulcus intercnemialis, 5-Crista patellaris, 6-Foramen interosii, 7-Condylus lateralis, 8-Condylus medialis, 9-Epicondylus, 10-Canalis extensorius, 11-Pons supratendineus, 12-Sulcus extensorius, 13-Fibula, 14-Caput fibulae, 15-Spina fibulae



**Figure 14:** 1-Fossa flexoria, 2-Foramen interosii, 3-Trochlea cartilaginis tibialis, 4-Epicondylus, 5-Fibula, 6-Caput fibulae, 7-Spina fibulae



**Figure 15:** 1-Os metatarsale I, 2-Cotyla lateralis, 3-Cotyla medialis, 4-Eminence intercotylaris, 5-Fossa infracotylaris dorsalis, 6-Foramina vasculare proximale, 7-Sulcus extensorius, 8-Trochleae metatarsi II, III, IV, 9-Incisurae intertrochleare, 10-Os digiti pedis I, 11-Os digiti pedis II, 12-Os digiti pedis III, 13-Os digiti pedis IV



**Figure 16:** 1-Os metatarsale I, 2-Cristae hypotarsi, 3-Hypotarsus, 4-Os digiti pedis I, 5-Os digiti pedis II, 6-Os digiti pedis III, 7-Os digiti pedis IV

while the remaining carpals are fused with the proximal ends of the metacarpals, forming the carpometacarpus.

Similar to the observations of Akers and Denbow (2008) and Tahon *et al.* (2013) in chicken the carpometacarpal bones are composed from three metacarpal bones fused with the distal carpal bones at the proximal end of the fused three metacarpal bones.

The intermetacarpal process mentioned by Baumel *et al.* (1993) and Tahon *et al.* (2013) in chicken as a small triangular shaped process projecting from the third carpometacarpal bone which is directed caudally and overlapping part of the fourth carpometacarpus. This process was not found in this study. On the other hand, Ballmann (1969a) named it as *Tuberositas muscularis*.

In accordance with Feduccia (1975), Hinchliffe (1985) and Muller and Alberch (1990), the digits of wing are composed of; the second digit (II), the third digit (III), and the fourth digit (IV). This result disagreed with Ostrom (1976) and Nickel *et al.* (1977) as they mentioned that the three digits of the wing were the first digit (I), the second digit (II), and the third digit (III).

The present study was as well as those of Tully *et al.* (2003), Hathaway and Buckley (2004), Akers and Denbow (2008) and Tahon *et al.* (2013) in chicken the Hip bone is formed by the fusion of an ilium, an ischium, and a pubis while the pelvis is formed by the two hip bones with the synsacrum, The pubic bones are not fused ventrally, so there is no pubic symphysis.

In accordance with Nickel *et al.* (1977) and Tahon *et al.* (2013), in chicken, the renal fossa is the paired deep fossa which accommodates the kidney and it is located on the ventral surface of ilium.

In agreement with Baumel *et al.* (1993), some birds as *Tinamous* and *Apteryx* have incompletely closed caudal end of the ilio-ischiatic foramen. On the other hand, Tahon *et al.* (2013) in chicken mentioned that the ilio-ischiatic foramen is a large closed elliptical foramen.

The trochanter of femur is an elevated, broad part of the proximal end of femur and it articulates with the antitrochanter of the ilium. On the other hand, Ametov (1971) observed that certain birds as passer domesticus, parus major and sitta europaea lack the femoral trochanter.

In accordance with Mclelland (1990) and Tully *et al.* (2003), tibia is fused with the proximal row of tarsal bones forming tibiotarsus.

Similar to the observations of Nickel *et al.* (1977), Tibiotarsus is longer than femur; also Kaiser (2007) stated that, in very long-legged birds, the tarsometatarsus and tibiotarsus usually have very similar lengths.

In agreement with Heyer (2008), the Tarsal bones fuse with tibia and metatarsal bones to form tibiotarsus and tarsometatarsus, respectively.

In accordance with Tully *et al.* (2003) and Tahon *et al.* (2013), in chicken, the tarsometatarsus is formed by metatarsal bones II, III, IV which are fused with each other and to the distal tarsal bone.

Pedal digits are four digits; the first digit consists of two phalanges, the second digit consists of three phalanges, the third digit consists of four phalanges and the fourth digit consists of five phalanges, these results were in agreement with Tully *et al.* (2003), Akers and Denbow (2008) and Tahon *et al.* (2013) in chicken.

## REFERENCES

1. Abou Shafey H.E. (2012). *Desportesius invaginatus* (Linstow, 1901) Chabaud and E. Campana, 1949 (Nematoda, Aeuariidae) from *Ardeola ibis ibis* with Reference to the Fine Structure of the Cordons. *PUJ*; 2012, 5(1): 49-57.
2. Akers R.M. and Denbow D.M. (2008). *Anatomy and physiology of domestic animals*, Blackwell publishing, Ames, Iowa.
3. Ametov Z. (1971). Peculiarities of the structure and function of the joints and tendon ligament apparatus of the pelvic bones and extremities of saltigrade birds. *DoeladyAkad. Nauk SSSR* 200(2): 492-495.
4. Ballmann P. (1969a). The bird from the altburdigalenSpaltenfillung Wintershof of (West) beiEichstat in Bavaria. *Zitteliana* (Munchen) 1: 5-60.
5. Barnett C. H. and Lewis O. J. (1958). The evolution of some traction epiphyses in birds and mammals. *J. Anat.* 92: 593-601.
6. Baumel J.J., King A.S., Breazile J.E., Evans H.E., Vanden Berge J.C. (1993). *Nomina Anatomica Avium*. Handbook of Avian Anatomy. 2<sup>nd</sup> ed., Ch. 4. Nuttall Ornithological Club, Cambridge, Massachusetts, 45-132.
7. Dyce K.M., Sack W.O., and Wensing C.J.G. (2002). *Text book of Veterinary Anatomy*, 3rd edition, p.p. 815-819. Saunders Company, Philadelphia, London, New York, ST. Louis, Sydney, Toronto.
8. Feduceia A. (1975). In Sisson and Grossman's the Anatomy of the domestic animals. 5th edition. R. Getty. Volume: 2, Chapter: 60 *Aves osteology*, Saunders company. p. 1791.
9. Hathaway L. and Buckley, (2004). Analysis of the anatomy and physiology of the chicken in comparison to the human. Block 2 anatomy/ physiology honors, November 19.
10. Heyer B. (2008). *Vertebrate structure and adaptation*. Biology 6A/ Sanhita Datta, winter, p. 1-11.
11. Hinchliffe J. R. (1985). 'One, two, three' or 'two, three, four': An embryologist's view of the homologies of the digits and carpus of modern birds. In: *Beginnings of Birds*. In: Hecht M.K., Ostrom J.H., Viohl G., Wellenhofer P., editors. *Beginnings of Birds*. Freunde Jura Museum Eichst-Att, Willibaldsburg, Germany, 141-7.
12. Kaiser G.W. (2007). *The inner bird: Anatomy and Evolution*. ISBN 978-0-7748-1343-3.
13. Mclelland J. (1990). *A color Atlas of Avian Anatomy*. Wolfe

- Publishing LTD. p. 33-46.
14. Muller G. B., and Alberch P. (1990). Ontogeny of the limb skeleton in Alligator mississippiensis: Developmental invariance and change in the evolution of archosaur limbs. *J. Morph.* 203:151-164.
  15. Nickel R., Schummer A., and Seiferle E. (1977). Anatomy of Domestic Birds. Verlag Paul Parey, Berlin and Hamburg, ISBN 3-489-55418-3. p. 5-25.
  16. Ostrom J. H. (1979). Bird flight: How did it begin? *Amer. Scientist* 67: 46-56. Owen R. (1842). Monograph on Apteryx australis. including its myology. *Proc. Zool. Soc. London*, p. 22-41.
  17. Tahon R. R., Ragab S. A., Abdel Hamid M. A., Rezk H. M. (2013). Some anatomical studies on the skeleton of chickens. Ph.D. Thesis. Anatomy and Embryology, Faculty of Veterinary Medicine, Cairo University.
  18. Tully T.N., Lawton M.P.C., and Dorrestein, G.M. (2003). Avian medicine. pp. 4-14. ISBN 0 7506 3598 3. Collection Forum 1999; 13(2):51-62.

**How to cite this article:**

**Source of Support:** Nil, **Conflict of Interest:** None declared.