

# Anatomical variations in the level of bifurcation of the sciatic nerve in Ethiopia

Mengstu Desalegn Kiros, Dawit Habte Woldeyes

Department of Human Anatomy, College of Medicine and Health Sciences, Bahir Dar University, Bahir Dar, Ethiopia

## Abstract

**Background:** The sciatic nerve, the largest nerve in the body is derived from the sacral plexus. It is composed of tibial and common fibular nerves; the division of this nerve varies; it may occur within the pelvis, gluteal region, upper, mid and lower part of thigh. Injury of the nerve may lead to loss of sensation in posterior thigh, whole leg and foot. The anatomical variations of the level at which the sciatic nerve divides is considered important by clinicians during neuromuscular diagnosis and treatments of the lower limb. **Objective:** To determine the level of sciatic nerve bifurcation and its side symmetry. **Materials and Methods:** Observational based descriptive study was conducted to determine the variation of sciatic nerve level of bifurcation on 25 human preserved cadavers. The data were analyzed manually using numbers, frequencies and percentages. **Results:** The findings of this study states that in 4 limbs (8%), the nerve divided in the pelvis region; in 2 limbs (4%), in the gluteal region; in 12 limbs (24%), at upper, middle and lower part of the posterior. The highest incidence of division occurs in 32 limbs (64%) in the popliteal fossa; in addition 8 (32%) of the 25 cadavers were asymmetrical between right and left sides. **Conclusion:** The findings of this study revealed that the majority of sciatic nerve divisions occur in the popliteal fossa while some divided into other regions such as pelvis, gluteal and thigh regions.

**Key words:** Bifurcation, common peroneal nerve, ethiopia, sciatic nerve, symmetry, tibial nerve

## INTRODUCTION

The sciatic nerve is the thickest and longest nerve in the body derived from the sacral plexus; it is composed of tibial and common fibular (Marieb *et al.*, 2012).

### Address for correspondence:

Mr. Mengstu Desalegn Kiros,  
Department of Human Anatomy, College of Medicine and Health Sciences, Bahir Dar University, Po Box 79, Bahir Dar, Ethiopia.  
E-mail: mengstud2003@gmail.com

The sciatic nerve is the most frequently injured nerve (Kumar *et al.*, 2011). Studies declared that variations exist to the level of sciatic nerve bifurcation (Saritha *et al.*, 2012; Babinski1 *et al.*, 2003). The anatomical variations of the level at which the sciatic nerve divides is considered important by clinicians (Mishra and Stringer, 2010).

As far as we know, there are no studies regarding the bifurcations of the sciatic nerve in Ethiopia. Therefore; the purpose of this study is to assess the level of bifurcation of the sciatic nerve and its side symmetry among Ethiopian population.

## MATERIALS AND METHODS

Observational based descriptive study design was conducted to describe the sciatic nerve bifurcation. A total of 25 unclaimed cadavers (4 females and 21 males) or 50 lower limbs (25 cadavers, left and right sides), which

Access this article online	
Quick Response Code:	Website: www.jecajournal.org
	DOI: ***

were obtained during routine dissections at Departments of Human Anatomy; University of Gondar, Bahir Dar University, GAMBY College of Medical Sciences, Mekelle University; Ethiopia.

Ethical approval was obtained from Ethical Review board of University of Gondar. Official letters were submitted to the above-mentioned colleges, explaining the purpose and the importance of the study and permission were obtained from each. Confidentiality was maintained at all levels of the study. Cadavers that were dry, difficult to dissect, damaged gluteal and thigh regions were excluded from the study.

### Operational Definitions

Type A: Division of sciatic nerve in the pelvis region,  
 Type B: Division of sciatic nerve in the gluteal region,  
 Type C: Division of sciatic nerve in the upper thigh,  
 Type D: Division of sciatic nerve in the middle thigh,  
 Type E: Division of sciatic nerve in the lower thigh,  
 Type F: Division of sciatic nerve in the popliteal fossa.

### Procedures

Sciatic nerve was exposed in the left and right lower limbs of the cadavers by the dissection technique which we use regularly for teaching; (according to the standard procedures of Cunningham's manual of dissection volume I) (Romanes, 2000). All dissections were carried out on the cadavers placed in prone position on a flat surface; bilateral gluteal regions and posterior compartment of the thigh were dissected to expose the nerve.

The level of bifurcation of the sciatic nerve was inspected on 25 cadavers and photographs were taken using digital camera (Fujifilm camera 1WP50964, 16.1 Mp) and the data observed were recorded, on the data collection form.

Data obtained in the level of bifurcation of the sciatic nerve were checked for completeness clarity, accuracy and consistency before analysis. Analysis was performed manually using numbers, frequencies and percentages.

## RESULTS

### General Information

In this study, 25 adult cadavers (50 lower limbs, 4 females and 21 males) were used. All cadavers were obtained from the above mentioned universities.

The results of the study are summarized as follows:

### Level of Bifurcation

The findings of this study states that in 4 limbs (8%), the sciatic nerve divided in the pelvis region [Figure 1].

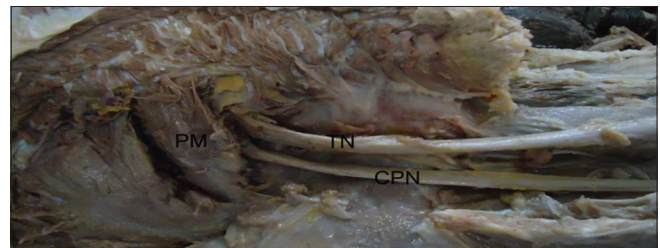
In 2 limbs (4%), it divides in the gluteal region [Figure 2]. In 6 limbs (12%), the nerve divided at the upper part of the posterior compartment of the thigh [Figure 3]. In 2 limbs (4%) of the specimens, division of sciatic nerve occurred at the middle part of the back of the thigh [Figure 4]. Four limbs (8%) have got their division at the lower part of the posterior compartment of the thigh [Figure 5]. The highest incidence of sciatic nerve division occurs in 32 limbs (64%) in the popliteal fossa [Figure 6 and Table 1].

### Side Symmetry

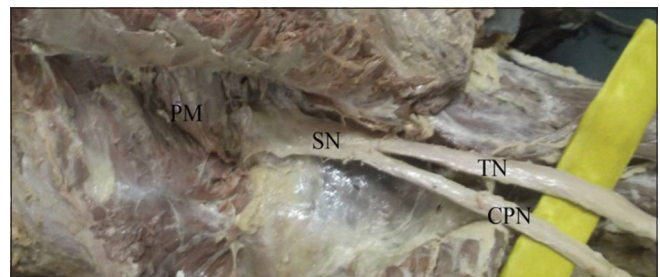In the current study, 8 (32%) of the 25 cadavers were asymmetrical between right and left sides [Table 2].

## DISCUSSION

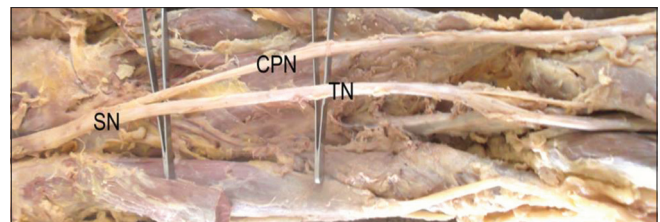
Most of the textbooks of human anatomy, orthopedics and surgery state that the sciatic nerve bifurcation levels are important in clinical and treatment aspects. Normally undivided sciatic nerve passes out through greater sciatic foramen below piriformis and divides at the apex of the popliteal fossa (85–89%); interpretation



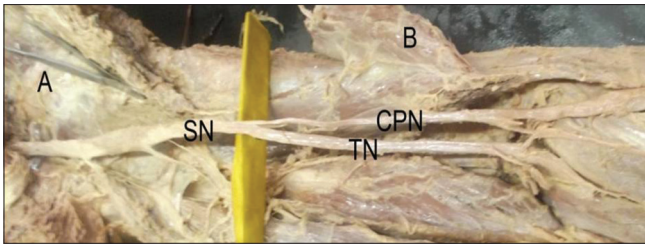
**Figure 1:** Sciatic nerve divided in the pelvis (Type A). PM = Piriformis muscle, TN = Tibial nerve, CPN = Common peroneal nerve




**Figure 2:** Bifurcation of sciatic nerve in gluteal region (Type B). PM = Piriformis muscle, SN = sciatic nerve, TN = Tibial nerve, CPN = Common peroneal nerve



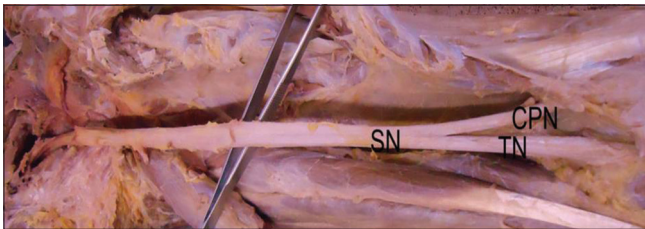**Figure 3:** Sciatic nerve bifurcation in the upper thigh (Type C). SN = Sciatic nerve, TN = Tibial nerve, CPN = Common peroneal nerve



**Figure 4:** Bifurcation of sciatic nerve in the middle thigh (Type D). SN = Sciatic nerve, TN = Tibial nerve, CPN = Common peroneal nerve



**Figure 5:** Sciatic nerve bifurcation in the lower thigh (Type E). SN = Sciatic nerve, TN = Tibial nerve, CPN = Common peroneal nerve



**Figure 6:** Sciatic nerve is divided in the popliteal fossa (Type F). SN = Sciatic nerve, TN = Tibial nerve, CPN = Common peroneal nerve

of the nerve variation in the limbs requires a consideration of phylogeny and development of the sacral plexus (Saritha *et al.*, 2012; Babinski *et al.*, 2003).

Bifurcation into its two major divisions (common peroneal and tibial nerves) may occur anywhere between the sacral plexus and the lower part of the thigh (Ali and Eweidah, 2010).

### Level of Bifurcation

The findings of this study revealed that the division of sciatic nerve in the pelvic region, was observed in 8% [Figure 1]; this result was different from other similar studies where the magnitudes were 19%, 48%, 17%, 20.1% of higher observation in Poland, Turkey, India and Kenya respectively (Okraszewska *et al.*, 2002; Mustafa *et al.*, 2009; Prakash *et al.*, 2010; Ogeng'o *et al.*, 2011).

Sciatic nerve bifurcation in the gluteal region was observed in 4% [Figure 2]; this result was in agreement with 2.3% and 2.4% observations reported on similar studies done in India and Kenya (Prakash *et al.*, 2010; Ogeng'o *et al.*, 2011). On the other hand, 8%, 14% were reported in India and Poland respectively (Kumar *et al.*, 2011; Okraszewska *et al.*, 2002).

**Table 1: The level of bifurcation of the sciatic nerve and its frequency**

Type	Number of limbs	Percentage
A	4	8
B	2	4
C	6	12
D	2	4
E	4	8
F	32	64

**Table 2: Side symmetry of the sciatic nerve bifurcation among the 25 cadavers**

Cadaver number	Right	Left
1*	Lower thigh	Politeal fossa
2	Politeal fossa	Politeal fossa
3	Politeal fossa	Politeal fossa
4*	Middle thigh	Gluteal region
5	Politeal fossa	Politeal fossa
6	Politeal fossa	Politeal fossa
7	Pelvis	Pelvis
8	Politeal fossa	Politeal fossa
9*	Politeal fossa	Upper thigh
10*	Upper thigh	Politeal fossa
11	Politeal fossa	Politeal fossa
12	Lower thigh	Lower thigh
13	Politeal fossa	Politeal fossa
14	Politeal fossa	Politeal fossa
15	Politeal fossa	Politeal fossa
16*	Politeal fossa	Pelvis
17	Upper thigh	Upper thigh
18*	Lower thigh	Politeal fossa
19*	Middle thigh	Gluteal region
20	Upper thigh	Upper thigh
21*	Pelvis	Politeal fossa
22	Politeal fossa	Politeal fossa
23	Politeal fossa	Politeal fossa
24	Politeal fossa	Politeal fossa
25	Politeal fossa	Politeal fossa

\*Asymmetrical

Bifurcation of sciatic nerve in the upper thigh was observed in 12% in the present study [Figure 3]; which was in line with a study done in India; whereas, 14% and 3.5% in India which was different from this study (Kumar *et al.*, 2011; Prakash *et al.*, 2010).

Middle thigh sciatic nerve bifurcation was observed in 4% in the current study [Figure 4]; this result was similar with 2.3% observed in India (Mustafa *et al.*, 2009); while 10.4% and 38% was observed in Kenya and India (Kumar *et al.*, 2011; Ogeng'o *et al.*, 2011).

Lower thigh sciatic nerve bifurcation [Figure 5] variety was observed in 8% in this study; this result was in agreement with 8% observation reported in India (Kumar *et al.*, 2011). In contrast, higher observation 14%, 40.7% was reported in Poland and



India respectively (Okraszewska *et al.*, 2002; Prakash *et al.*, 2010).

In the present study, 64% of bifurcation of sciatic nerve in the popliteal fossa was observed [Figure 6]; this result was in agreement with 72%, 72.5%, and 67.1%, observations reported in Poland, Serbia and Kenya respectively (Okraszewska *et al.*, 2002; Ugrenović *et al.*, 2005; Ogeng'o *et al.*, 2011) however, lower percentage, were observed in India 34.9% (Kumar *et al.*, 2011; Ugrenović *et al.*, 2005). This difference between the present study and the study done in India may be due to embryologic reasons, race, etc. [Table 3].

### Side Symmetry

As far as we know, most textbooks and journals have little information about the variations of side symmetry; in the current study 8 (32%) of the 25 cadavers were asymmetrical between right and left sides.

## CONCLUSION AND RECOMMENDATION

In this study, the majority of sciatic nerve divisions occur in the popliteal fossa; while, some divided into other regions such as pelvis, gluteal and thigh. These variations in the bifurcation levels might be difficult for clinicians, radiologists, surgeons, etc. Further research needs to be

done on a large number of samples so that generalization for the total population will be more accurate.

## REFERENCES

1. Ali M.H., Eweidah M.H. (2010). A case of a unilateral unusual genicular branch of the common peroneal nerve with bilateral high division of sciatic nerves and unusual bilateral thickness of peroneal communicating nerve. *Int J Anat Var* 3:33-5.
2. Babinski M.A., Machado F.A., Costa W.S. (2003). A rare variation in the high division of the sciatic nerve surrounding the superior gemellus muscle. *Eur J Morphol* 4 (1):41-2.
3. Kumar T.M., Srimathi., Rani A., Latha S. (2011). A cadaveric study of sciatic nerve and its level of bifurcation. *J Clin Diagn Res* 5:1502-4.
4. Marieb E.N., Wilhelm P.B., Mallatt J. (2012). *Human Anatomy: The Peripheral Nervous System*. Pearson Education, Inc., Publishing, San Francisco, 451-4.
5. Mishra P., Stringer M.D. (2010). Sciatic nerve injury from intramuscular injection: A persistent and global problem. *Int J Clin Pract* 64:1573-9.
6. Mustafa G., Iyem C., Akyer P., Tetik S., Naderi S. (2009). Variations in the high division of the sciatic nerve and relationship between the sciatic nerve and the piriformis. *Turk Neurosurg* 19:139-44.
7. Ogeng'o J.A., El-Busaidy H., Mwika P.M., Khanbhai M.M., Munguti J. (2011). Variant anatomy of sciatic nerve in a black Kenyan population. *Folia Morphol (Warsz)* 70:175-9.
8. Okraszewska E., Migdalski L., Jedrzejewski K.S., Bolanowski W. (2002). Sciatic nerve variations in some studies on the Polish population and its statistical significance. *Folia Morphol (Warsz)* 61:277-82.
9. Prakash, Bhardwaj A.K., Devi M.N., Sridevi N.S., Rao P.K., Singh G. (2010). Sciatic nerve division: A cadaver study in the Indian population. *Singapore Med J* 51:721-3.
10. Romanos G.J. (2000). *Cunningham's Manual of Practical Anatomy: The Lower Limb*. Oxford Medical Publications, New York, 165-8.
11. Saritha S., Kumar M.P., Supriya G. (2012). Anatomical variations in the bifurcation of the sciatic nerve; a cadaveric study and its clinical implications. *Anat Physiol* 2:1-4.
12. Ugrenović S., Jovanović I., Krstić V., Stojanović V., Vasović L. (2005). The level of the sciatic nerve division and its relations to the piriform muscle. *Vojnosanit Pregl* 62:45-9.

**Table 3: Summary of studies done in different areas of the world**

Study area	Number of cadavers	Number of limbs	Type (%)					
			A	B	C	D	E	F
India (2011)	25	50	-	8	14	38	8	32
Poland	18	36	-	14	-	-	14	72
Turkey	25	50	48	-	-	-	-	-
India (2010)	43	86	17.4	2.3	3.5	2.3	40.7	34.9
Serbia	100	200	4	27.5	72.5	-	-	-
Kenya	82	164	20.1	2.4	-	10.4	-	67.1
This study (Ethiopia)	25	50	8	4	12	4	8	64

**How to cite this article:** ???.

**Source of Support:** Nil, **Conflict of Interest:** None declared.