

Neurobehavioral and histological effects of Akaki extract on the temporal lobe: Mimicking traditional treatment method

Finbarrs-Bello E, Egwu A. O¹, Esom E², Okefie E. O

Department of Anatomy, Faculty of Basic Medical Science, Ebonyi State University, Abakaliki, ¹Department of Anatomy, Federal University, Ndufu-Alike, Ikwo, Ebonyi State, ²Department of Anatomy, University of Nigeria, Enugu Campus, Enugu State, Nigeria

Abstract

Introduction: Neurobehavioral and histological effect of akaki extract on the temporal lobe of wister rats was carried out. In the study we evaluate a traditional prescription method for the treatment of mental illness using the akaki extract on the temporal lobe. **Material and Methods:** Twenty rats of average weight 200 g were divided into four groups ($n = 5$). The rats in the control group (Group A) were given feed and water, while the rats in the experimental Groups B, C, and D were treated daily with 3 mg/kg, 6 mg/kg and 9 mg/kg of the extract for 7 days respectively. **Results:** Preliminary phytochemical analysis revealed presence of bioactive agents. The behavioral study was performed using the elevated plus-maze (EPM) to access anxiety and routine H and E histological technique. The mean difference was significant at level ($P < 0.05$). The study showed that the rat exhibited antianxiety property in the EPM. This was more pronounced in the experimental rats. The histological study performed showed that there were progressive changes in the temporal lobe integrity of the sections of the rat in the experimental groups with the rat that received 9 mg/kg of the Akaki extract showing more prominent features of these changes which include cytoplasmic vacuolations and eccentric nuclei within the pyramidal cell layer than granular cell layer as compared to the control group (Group A). **Conclusion:** In conclusion, the akaki extract shows positive indication of its use in the treatment of mental illness.

Key words: Akaki extract, behavioral, histological, temporal lobe

INTRODUCTION

In developing countries, particularly Nigeria, the use of herbal remedies for curative purposes is rooted in

Address for correspondence:

Mrs. Finbarrs-Bello E,
Department of Anatomy, Faculty of Basic Medical Science,
Ebonyi State University, Abakaliki, Ebonyi State, Nigeria.
E-mail: finbello@yahoo.com

the belief and cultures of the people. Herbal medicine or phytomedicine, refer to the use of plant parts, fruits, seeds, berries, roots, leaves, barks or flower for medicinal purposes (Lalnundanga and Lalrinkima 2012). An herbal therapy differs from the orthodox medicine in the nature of raw materials used, methods of preparation, dosing, and administration. The treatment patterns between these forms of medicinal practices are not the same. Almost one-fourth of pharmaceutical drugs are derived from herbs through standard analytic methods and quality control aimed at the specific active agent in the herb or of a combined herbs (Kennedy and Wightman 2011).

The use of herbs for treating of physical, mental and social diseases by man dates back to antiquity (Hussin, 2001). These medicinal plants are used as a whole or its parts; they can be used singly or in combination with

Access this article online	
Quick Response Code:	Website: www.jecajournal.org
	DOI: 10.4103/1596-2393.154398

more than one plant for the treatment of an identified disease condition (Hussin, 2001). *Costus afer* is commonly used as a medicinal plant through tropical African to manage various ailments of the digestive, respiratory and nervous systems (Aguiyi *et al.*, 1998). *Sarcocephalus latifolius* belongs to the family *Rubiaceae*. The common name of the plant is Africa peach. The *Sarcocephalus latifolius* was good for the treatment of malaria, yellow fever, cough, febrile condition, thrush, jaundice, pills, emetic menstrual disorder, measles, and sore (Aiyelaja *et al.*, 2006; Odugbemi, 2008; Ogunleye, 2010). *Culcasia scandens* leaf extract has an anti-inflammatory activity (Shin *et al.*, 2009)

In the south-eastern part of Nigeria, the three herbs are locally named Oka leaf (*Costus afer*), Obala Ilu (*Sarcocephalus latifolius*), Aki Okwuru (*Culcasia scandens*). These herbs are combined in the management of central nervous systems (CNSs) disorders such as epilepsy and convulsion. The combination of the three herbs as used in this study is referred to as (Akaki). Inappropriate formulation or lack of understanding of plants and drug interaction has led to adverse reaction that are sometimes life-threatening or lethal (Ernest and Pittler, 2002). Herbal remedies can be contaminated, lack established efficiency, and the expected synergist efficacy may result in an undesirable effect unknowingly. Hence, this study mimics the traditional application of the herbal therapy in the management of CNS disorders. Particularly, the temporal lobe of the brain is mostly affected in most disorders of the CNS. Thus, the integrity of its microanatomy might have been altered as well.

MATERIALS AND METHODS

Collection and Identification of the Plants

Fresh leaves of *costus afer*, *sarcocephalus latifolius*, and *culcasia scandens* were collected from herbal man in Agbani, Nkanu-West Local Government Area of Enugu State; Southeast part of Nigeria. The leaves were taken to the Department of Plant Science and Biotechnology of the University of Nigeria Nsukka for taxonomical identification. The leaves were identified and confirmed by a taxonomist professor Mrs. M. O. Nwosu.

Preparation of the Plant Material

The fresh leaves of *Costus afer*, *Sarcocephalus latifolius*, and *Culcasia scandens* were washed in distilled water and air-dried at room temperature. 50 g of each plant was measured and mixed together. This fine powder was divided into two portions. A portion of the powder was taken to Project Development Institute (PRODA) for preliminary phytochemical analysis while the rest portion was used for extract preparation.

Aqueous Extraction

125 g of the dry leaf powder was submerged into 1250 ml of hot water and allowed to boil for 45 min from the boiling point. After which it was allowed to cool and then filtered with cheese over a funnel. Thereafter, the residue was discarded while the filtrate obtained (aqueous extract) was evaporated to a paste using a vacuum evaporator. This yielded 2 g of the aqueous extract, referred to as the Akaki extract in the study was transferred into a suitable container and kept in the refrigerator at low temperature for the experiment.

Experimental Animal Care

Twenty adult Wistar rats of both sexes weighing about 150–180 g were used for the study. The rats were purchased at the Department of Biotechnology Ebonyi State University Abakaliki. The animals were kept at room temperature and properly feed with growers mesh 3 times daily. The rats were accommodated in a well-ventilated cage with adequate environmental condition and allowed to acclimatize at the animal facility of the department of anatomy for 2 weeks before the commencement of the extract administration. Thereafter, they were randomly assigned to four Groups A, B, C, and D. Group A has two rats while the remaining three groups have six rats each. The first group (Group A) was taken as the control group while Group B, C, and D serve as the experimental groups, respectively. The different groups were housed in iron netting with water bottles inside and cared for in compliance with applicable guidelines for animal research study.

Administration of the Akaki Extract

The Akaki extract was administered orally for a period of 1-week as traditionally prescribed. The dosage was based on the weight of the rat and was calculated using human dosage consumption used in traditional treatment pattern. Control group received feed and water, experimental groups were given 3 mg/kg, 6 mg/kg, and 9 mg/kg/body weight daily, respectively, for a period of 1-week.

Elevated Plus-maze

At the end of the administration period (7 days), the rats one after the other were placed in the central square of the plus-maze facing an open arm and were allowed to explore the apparatus for 5 min. A video camera located 150 cm above the center of the maze records the behaviors of the animal in the maze. After 5 min each of the rats was removed, and the maze was cleaned and allowed to dry between tests. A 25-W red fluorescent light 100 cm above the maze served as a source of illumination. Behavioral parameters scored includes (1) number of closed and

open arm entries – absolute value and percentage of the total number; (2) Time spent in exploring the open and closed arms of the maze – absolute time and percentage of the total time of testing. An arm entry was counted only when all four limbs of the mouse were within a given arm.

Histological Study

All the animals were anesthetized by 50 mg thiopental injection intraperitoneally. The rats' brains were carefully dissected out and immediately fixed in 10% formal saline. Thereafter the temporal lobes of the rats' brain were dissected out using a surgical blade, processed for routine histological method and stained with H and E. The stained tissue sections were micrographed and interpreted.

Statistical Analysis

The data were analyzed using the SPSS software version 20 (SPSS Inc., IBM Statistics, 2014) for mean \pm standard deviation, Bar chart, and tables at significant level of 0.05.

RESULTS

Phytochemical Analysis

The qualitative phytochemical analysis of the equally mixed proportions of the grounded leaves of *Costus afer*, *Sarcocephalus latifolius*, and *Culcasia scandens*, showed the presence of the following phytochemical compounds: saponin, phenols, flavonoid, tannin and glycosides.

DISCUSSION

Phytochemical Findings

Herbs contain bioactive compounds like alkaloid, Saponin, phenol, flavonoid, tannin, steroids, and glycosides (John *et al.*, 2001). The phytochemical analysis carried in this research work revealed the presence of saponin, phenol, flavonoid, tannin, and glycosides while alkaloid and steroid were absent. The glycoside concentration was, however, higher than the phenols, flavonoids, and saponins contents which were moderate and trace tannin content. Glycoside and phenols have been reported to possess neuroprotective property against assault particularly in ischemic stroke (James *et al.*, 2006). It is also associated with neurosensory disorder such as depression hallucination, headache, confusion, and drowsiness (James *et al.*, 2006). This probably may explain the neuronal changes observed in this section of the experimental rats in this work

Behavioral Findings

The elevated plus-maze (EPM) test relies on the inherent conflict between exploration of a novel area and avoidance of its aversive features (Crawley, 1999). This test has been widely validated for measuring anxiolytic- and anxiogenic- like activities in rodents being bi-directionally

sensitive to both anxiolytic drugs like benzodiazepines, as well as compounds that induce anxiety in man (Holmes *et al.*, 2000). The behavioral parameters often used as criteria for scoring animal behaviors in the EPM include number of closed and open arm entries, Time spent in exploring the open and closed arms of the maze, number of head dips; protruding the head over the ledge of either an open (unprotected) or closed (protected) arm, and down toward the floor, number of stretch-attend postures (absolute value and percentage of the total number) the rat stretches forward and retracts to the original position from a closed (protected) or an open (unprotected) arm. An arm entry was counted only when all four limbs of the mouse were within a given arm (Rodgers *et al.*, 1997, Kalynchuk, 2000).

The study measured the arm entries and durations of time spent in both arms. Normal rats that have not received any antianxiety drugs will become moderately anxious in their new environment thus they tend to prefer the close arms over the less secured open arms (Treit *et al.*, 1993). Our finding was consistent with that of Salum *et al.*; (2000), rats show strong preference for the close arms over the open arm, they tend to spend more time in the closed arms than open arm [Figure 1]. Anxious rats show more open-arm activity than normal rats and sometimes exhibit extreme behavior like purposefully jumping to the floor from the open arms (Kalynchuk *et al.*, 1992). The result of this experiment is consistent with the report given by Trullas and Skolnick (1993) "the index of the open arm avoidance also gives a measure of anxiety." The Akaki extract exhibited antianxiety properties in that the rats entered into the closed arm and also spent more time in the closed arm of the EPM. However, in this experiment the Akaki extract may have acted as antianxiolytic agent on the rats.

Histological Finding

The brain is extremely complex and composed of neurons and glial cells (Guyton and John, 2001). The normal state of these cells is important for the normal activities of the CNS. Injury or trauma to the neurons disrupts neuronal activity lead to various neuronal changes. Abbas and Nelson (2004) enumerated possible causes of neuronal assaults which include obstructed blood flow, crushing of nerve fibers and injection of toxic substances like drugs. The sections of the temporal lobe of the control group revealed normal cytoplasm with centrally placed nuclei in granular cell and pyramidal cell layers [Figure 2]. The treated groups which received 3 mg/kg, 6 mg/kg and 9 mg/kg showed neuronal cells with vacuolated cytoplasm and pknotic nuclei eccentric nuclei in both granular cell and PCLs [Figures 3-5].

The observed cytoplasmic vacuolations and eccentric nuclei were more pronounced in sections of the group

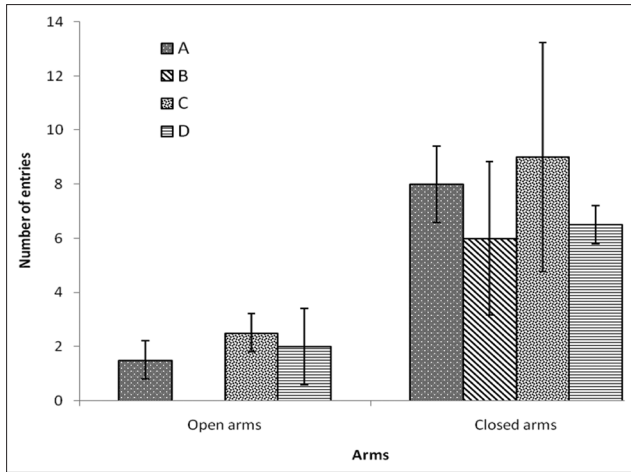


Figure 1: Number of entries and durations in the elevated plus maze

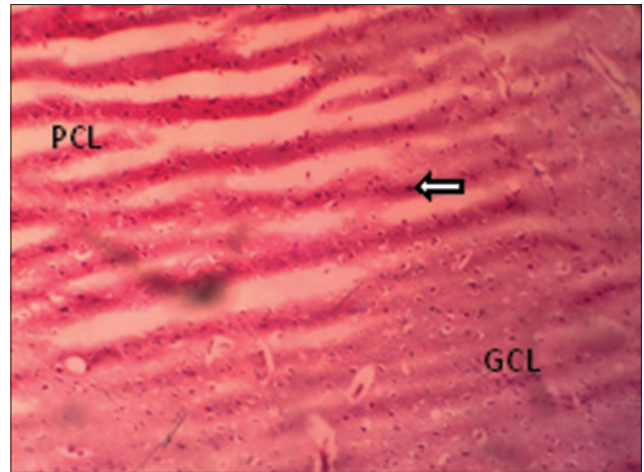


Figure 2: Section of temporal lobe of the control showing normal cytoplasm with centric nuclei in pyramidal cell layer (PCL) and granular layer (GCL). (H and E, magnification ×100)

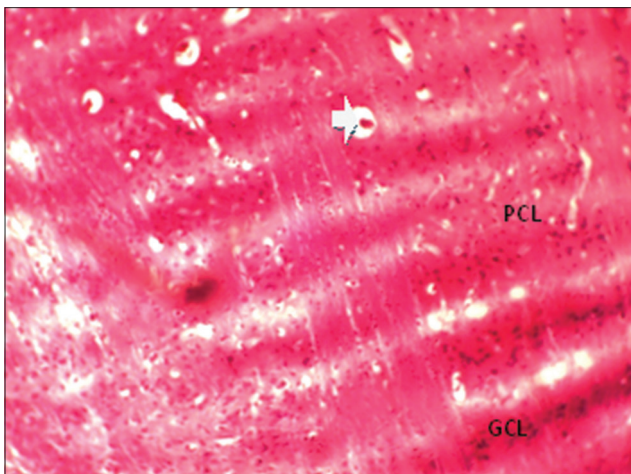


Figure 3: Section of temporal lobe of rats given with 3 mg/kg/bw Akaki extract. Showing pyramidal cell layer, granular cell layer with vacuolated cytoplasm (H and E, magnification ×100)

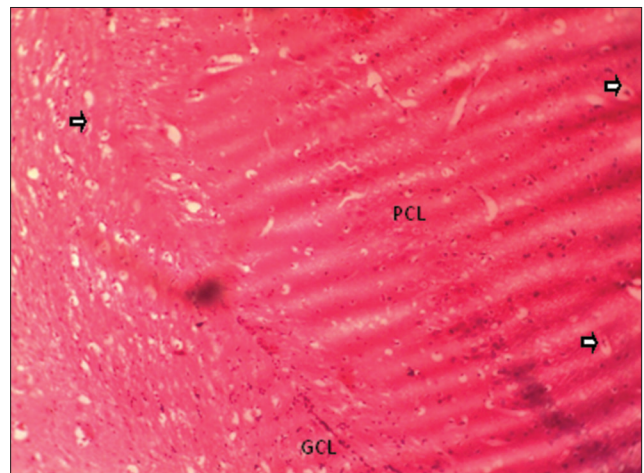


Figure 4: Section of temporal lobe treated with 6 mg/kg/bw Akaki extract showing more vacuolated cytoplasm and eccentric nuclei in the pyramidal cell layer, granular cell layer (H and E, magnification ×100)

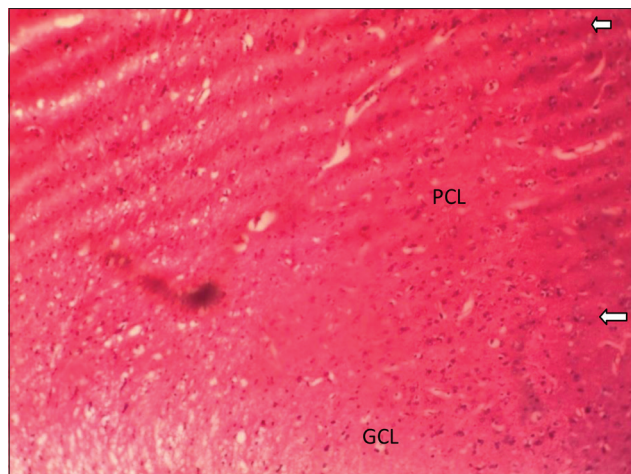


Figure 5: Section of temporal lobe of rats' treated with given 9 mg/kg/bw, showing cytoplasmic vacuolations and pyknotic nuclei in pyramidal cell layer (H and E, magnification ×100)

which received lower dose of 3 mg/kg [Figure 3] and less pronounced in groups which received 6 mg/kg and

9 mg/kg [Figures 4 and 5]. These improved neuronal changes at higher dose may have resulted from the higher concentrations of some neuroprotective phytochemical agents in the Akaki extract. Specifically, which phenols and glycosides which have been known to offer some degree of neuroprotection. Thus, reveal that Akaki extract (combination of *costus afer*, *sarcocephalus latifolius*, and *culcasia scandens*) showed possible scientific justification of its traditional use to cure mental illness.

REFERENCES

1. Abbas A., Nelson F.K. (2004). Robin and Cotran Pathologic Basis of Diseases. 7th ed. Elsevier, New Delhi. 127-31.
2. Aguiyi J.C., Olorunfemi P.O., Igveh A.C. (1998). Antibacterial activity of costus afer. *Fitoterapia* 69 (3): 272-3.
3. Crawley J.N. (1999). Behavioral phenotyping of transgenic and knockout mice: Experimental design and evaluation of general health, sensory functions, motor abilities, and specific behavioral tests. *Brain Res* 835: 18-26.

4. Kennedy D.O., Wightman E.L. (2011). Herbal extracts and phytochemicals: plant secondary metabolites and the enhancement of human brain function. *Adv Nutr* 2: 32-50.
5. Guyton A.C., John E.H. (2000). Behavioural and motivational mechanisms of the brain, limbic system and hypothalamus. *Textbook of Medical Physiology*. 10th ed. W. B. Saunders Company, Philadelphia, 678-87.
6. Holmes A., Parmigiani S., Ferrari P.F., Palanza P., Rodgers R.J. (2000). Behavioral profile of wild mice in the elevated plus-maze test for anxiety. *Physiol Behav* 71: 509-16.
7. Hussin A.H. (2001). Adverse effects of herbs and drug-herbal interaction. *Malays J Pharm Sci* 2: 39-44.
8. James K.T., Portbury S., Thomas M.B., Barney S., Ricca D.I., Morris D.L., *et al.* (2006). Cardiac glycosides provide neuroprotection against ischemic stroke: Discovery by a brain slice-based compound screening platform. *J Neurophysiol* 103 (27): 10461-6.
9. Kalynchuk L.E. (2000). Long-term amygdala kindling in rats as a model for the study of interictal emotionality in temporal lobe epilepsy. *Neurosci Biobehav Rev* 24: 691-704.
10. Lahnundanga L.N., Lalrinkima R. (2012). Phytochemical analysis of the methanol extract of root bark of *Hiptage benghalensis* (L.). *Kurz Sci Vis* 12 (1): 8-10.
11. Odugbemi T. (2006). *A Textbook of Medicinal Plant from Nigeria*. 1st ed. University of Lagos Press, Lagos, 28-31.
12. Rodgers R.J., Cao B.J., Dalvi A., Holmes A. (1997). Animal models of anxiety: An ethological perspective. *Braz J Med Biol Res* 30: 289-304.
13. Salum C., Morato S., Roque-da-Silva A.C. (2000). Anxiety-like behaviour in rats: A computational model. *Neural Netw* 13: 21-9.
14. Treit D., Menard J., Royan C. (1993). Anxiogenic stimuli in the elevated plus-maze. *Pharmacol Biochem Behav* 44: 463-9.
15. Trullas R., Skolnick P. (1993). Differences in fear motivated behaviors among inbred mouse strains. *Psychopharmacology (Berl)* 111: 323-31.
16. Wang J.K., Portbury S., Thomas M.B., Barney S., Ricca D.J., Morris D.L., *et al.* (2006). Cardiac glycosides provide neuroprotection against ischemia stroke: Discovery by a brain slice based compound screening platform. *Natl Acad Sci* 103 (27): 10461-6.

How to cite this article: Finbarrs-Bello E, Egwu AO, Esom E, Okefie EO. Neurobehavioral and histological effects of Akaki extract on the temporal lobe: Mimicking traditional treatment method. *J Exp Clin Anat* 2014;13:45-9.

Source of Support: Nil, **Conflict of Interest:** None declared.