

Uvaria afzelii root extract protects the liver against damage caused by carbontetrachloride ingestion

Sylvester Ifeanyi Omoruyi, Madu Ifeoma Joan, Enogieru Adaze Bijou, Momodu Oghenakhogie Irobodu

Department of Anatomy, University of Benin, Benin City, Nigeria

Abstract

Introduction: Hepatoprotective activity of crude aqueous extract of *Uvaria afzelii* (UV) root was investigated and compared with a standard hepatoprotective drug (silymarin) in Wistar rats. **Materials and Methods:** Twenty-five adult Wistar rats were randomly assigned into a control Group (A) and four treatment Groups (B-E) each containing five rats ($n = 5/\text{group}$). Animals in each group were allowed access to 200 g/day growers' mash and water ad libitum. Rats in the treatment groups were administered with intraperitoneal injection of 1 ml/kg body weight of 30% carbon tetrachloride (CCL_4)/olive oil mixture every 72 h interval during the 15 days experimental period. Rats in Group B were not pretreated while Groups C, D and E rats were pretreated daily with 50 mg/kg body weight of silymarin, 250 mg/kg and 500 mg/kg body weight of crude aqueous extract of UV root respectively. On the 15th day of the experiment, the rats were sacrificed and blood samples were collected to assay for serum liver enzymes; aspartate aminotransferase (AST), alanine aminotransferase (ALT), alkaline phosphatase (ALP) as well as total protein (TP). The liver tissues were also excised and fixed in 10% buffered formal saline for routine histological examination. **Result:** The result obtained showed that UV root extract significantly ($P < 0.05$) decreased serum AST, ALT, ALP while TP was significantly ($P < 0.05$) increased when compared with nonpretreated rats administered with CCL_4 /olive oil and not significant ($P < 0.05$) when compared with silymarin pretreated rats. Histological observation of the liver of rats injected with CCL_4 /olive oil only showed vacuolation (presence of fat droplets), portal vein congestion, and moderate tissue separation. These observations were reduced in the liver of rats pretreated with UV root extract and silymarin. **Conclusion:** These findings indicate that root extract of UV possess hepatoprotective activity against ingested hepatotoxic insults.

Key words: Carbon tetrachloride, histology, liver enzymes, silymarin, *Uvaria afzelii*

Address for correspondence:

Mr. Sylvester Ifeanyi Omoruyi,
Department of Anatomy, University of Benin,
Benin City, Nigeria.
E-mail: sylvester.omoruyi@uniben.edu

Access this article online	
Quick Response Code:	Website: www.jecajournal.org
	DOI: 10.4103/1596-2393.154396

INTRODUCTION

Medicinal plants have been used to treat for various diseases in all over the world. Now-a-days, Indian medicinal plants belonging to about 40 families have been investigated as liver protective drugs (Handa *et al.*, 1986).

Uvaria afzelii (UV) is a small tree or spreading shrub growing up to 5 m tall. The tree is used locally, being harvested from the wild for food and medicines. It is widely distributed and grown in the South and Eastern part of Nigeria, where it is known by various local names such as “gbogbonishe” (Yoruba), “Umimiofia” (Igbo) and “Osu-umimi” (Ukwani) (Odugbemi, 2008). Locally

it is used in the treatment of cough, vaginal tumor, breast aches, swollen hands and feet's, diabetes as well as leucorrhoea and gonorrhoea (Kayode *et al.*, 2009). A number of investigations carried out to ascertain the claimed uses of the plant include its reported bacteriocidal activity against Gram-positive and acid-fast bacteria (Okoli, 2004; Lawal *et al.*, 2011), antihelminthic and antiparasitic activities (Okpekon, 2004). Other ethnomedicinal uses of the plant include its benefit as a remedy for jaundice, infections of the liver, kidney and bladder (Kerharo and Bouquet, 1950; Bouquet and Debray, 1974; Gill, 1989). Silymarin is a standardized extract of the milk thistle plant (*Silybum marianum*) which majorly contains flavonoids: Silybin, silybinin, silydianin and silychristin (Flora *et al.*, 1996). Seeds of this plant have been used for >2000 years to treat liver and gall bladder disorders, including hepatitis, cirrhosis and jaundice and to protect the liver against poisoning from chemicals, environmental toxins, snake bites, insect stings, mushroom poisoning and alcohol (Kren and Walterova, 2005). More so, it is used as a standard drug with exhibition of potent hepatoprotective activity at the dose range from 25 to 200 mg/kg in various experimental and clinical studies (Ramadan *et al.*, 2002; Wills and Asha, 2006; Salam *et al.*, 2007).

The liver is a metabolic organ involved in the regulation of internal chemical environment. Its' metabolic functions, such as detoxification, predisposes it to a number of toxicants (Meyer and Kulkarni, 2001). Therefore the damage to the liver inflicted by a hepatotoxic agent is of critical consequence. However, conventional or synthetic drugs (e.g., silymarin) used in the treatment of liver diseases are sometimes inadequate and can have adverse effect (Guntupalli *et al.*, 2006). This has necessitated a global search for herbal alternatives with minimal or no side effect (Venkateswaran *et al.*, 1997; Dhuley and Naik, 1997; Mitra *et al.*, 2000).

Researchers have developed systematic methodology to evaluate the scientific basis for the use of herbal alternatives for protecting the liver against hepatotoxic agent. Carbon tetrachloride (CCL₄) is a known chemical for induction of liver damage, and its effect is comparable to that of acute viral hepatitis (Rubinstein, 1962). The toxic effect of CCL₄ is attributed to trichloromethyl radical produced during oxidative stress (Stoyanovsky and Cederbaum, 1999). Therefore, CCL₄ mediated the hepatotoxicity was employed as an experimental model for liver injury in this study. The aim of this research was to investigate the effect of roots extracts of UV on CCL₄-induced liver damage and to compare the observed effects with a known hepatoprotective drug (silymarin).

MATERIALS AND METHODS

Plant Material

The roots of the plant UV were gotten from a forest in Orhionmwon near Benin City during the month of July 2013. The plant was identified by Mr. Sunny Nweke, the curator of the Department of Pharmacognosy, Faculty of Pharmacy, University of Benin Edo state.

Preparation of Extract

The roots of *Uvaria afzelii* were chopped into little bits and allowed to dry at room temperature for 5 weeks. The dried roots were pounded in a wooden mortar and pestle and milled into a fine powder in an electric blender. 1.5 kg of the powder was obtained soaked in 2litres of distilled water for 24 h. The mixture was filtered with white filter paper and the residual was separated from the filtrate. The filtrate was evaporated at 60°C in a vacuum rotary evaporator. The residue obtained was dried and stored in the refrigerator. A measured portion of the extract was dissolved in distilled water, and an appropriate dose was administered to the animals daily.

Animal Care and Management

Twenty-five adult Wistar rats were used for the experiment. The animals were inbred rats of the animal holdings of the Department of Anatomy, School of Basic Medical sciences, University of Benin, Benin City. The animals were housed, fed and cared for in accordance with the guidelines of the Research Ethics Committee of the College of Medical Sciences, University of Benin, Benin City.

Treatment Regimen

The rats were randomly assigned into a control Group (A) and four treatment Groups (B-E) each containing five rats ($n = 5/\text{group}$). Animals in each group were allowed access to 200 g/day growers' mash and water *ad libitum*. Rats in the treatment groups were administered with intraperitoneal injection of 1 ml/kg body weight of 30% CCL₄/olive oil mixture every 72 h interval throughout the 15 days experimental period. Rats in Group B were not pretreated while Groups C, D and E rats were pretreated daily with 50 mg/kg body weight of silymarin, 250 mg/kg and 500 mg/kg body weight of crude aqueous extract of UV root respectively.

Sacrifice of the Animals

The experimental period lasted for 14 days and on the 15th day animals were sacrificed by cervical dislocation. A midline incision was made through the anterior abdominal wall of the rats. A volume of 5 ml blood samples were collected from the descending abdominal aorta, in heparin-coated bottles from biochemical analysis, and the liver was excised and fixed in 10% buffered formal saline.

Assay of Marker Enzymes of Liver Damage

The blood samples collected were centrifuged at 3000 revolutions/min using a table-top centrifuge (Shanghai Surgical Instrument Factory, Shanghai, China) at 37°C for 15 min to separate the sera. Serum alanine aminotransferase (ALT) and aspartate aminotransferase (AST) and alkaline phosphatase (ALP), as well as total protein (TP), were assayed using Randox Diagnostic Kits (Reitman and Frankel, 1957).

Histological Procedure

Following fixation, specimens were dehydrated, embedded in paraffin wax, and then sectioned at a thickness of 5 µm. Procedure for h and e staining was carried out using the method of Drury *et al.*, (1976) and observed under a Light Microscope.

Statistical Analysis

The data generated were analyzed using descriptive and inferential statistics. All values were presented as mean ± standard error of means. All statistical analysis was carried out using Statistical Package for Social Sciences (SPSS) (version 17). The significance of the difference in the means of all parameters was determined using one-way analysis of variance (95% confidence interval). Least square difference, *post-hoc* test was carried out for all groups with control and comparison of all pairs of groups respectively. Values were statistically significant when $P < 0.05$.

RESULT

Effect of *Uvaria afzelli* Extract on Liver Function Enzymes

From the result as shown in Figure 1, there was a marked significant ($P < 0.05$) increase of serum alkaline phosphatase level (ALP), serum transaminases (AST and ALT) in the group 2 animals that were treated with carbon tetrachloride when compared with control group 1 animals. On pretreatment with Silymarin at 50 mg/kg, *Uvaria afzelli* at 250 mg/kg, 500 mg/kg of body weight respectively, there was a significant ($P < 0.05$) decrease of the level of these enzymes as the values were found to be retrieving towards normal. More so, there was a marked significant ($P < 0.05$) decrease in the concentration of the total protein (4.70 ± 0.11) in the CCl₄-treated when compared to the control (6.98 ± 0.11). However, *Uvaria afzelli* at 250 mg/kg and 500 mg/kg as well as Silymarin at 50mg/kg of body weight improved these values (6.00 ± 0.09 ; 7.23 ± 0.13 and 6.75 ± 0.16) respectively [Figure 1].

Effect of *Uvaria afzelli* Extract on Liver Histology

Result of liver histology section of normal control animals exhibited normal hepatic cells each with well defined cytoplasm, prominent nucleus and well brought out portal triad [Figure 2], whereas that of CCl₄ intoxicated

group animals showed total loss of hepatic architecture with hepatic necrosis, fatty changes and vacuolization [Figure 3]. More so, pretreated animals with silymarin at 50 mg/kg and *Uvaria afzelli* (250 and 500 mg/kg) protected the liver hepatocytes from damage induced by CCl₄ with reduction in the severity of fat deposits in the hepatic parenchymal [Figures 4-6].

DISCUSSION AND CONCLUSION

Carbon tetrachloride is metabolized in the liver to the highly reactive trichloromethyl radical and this free radical leads to auto-oxidation of the fatty acids present in the cytoplasmic membrane phospholipids and causes functional and morphological changes in the cell membrane (Recknagel, 1967). Trichloromethyl free radical when combined with cellular lipids and proteins in the presence of oxygen form trichloromethyl peroxy radical, which may attack lipids on the membrane of the endoplasmic reticulum faster than trichloromethyl free radical. Thus, trichloromethyl peroxy free radical leads to elicit lipid peroxidation, the disruption of Ca²⁺ homeostasis, and finally, results in cell death (Opoku *et al.*, 2007).

In this present study, hepatocyte degeneration and cytoplasmic vacuolation (lipid deposition) was observed in the group treated with CCl₄/olive oil. Histological observation of the liver section of normal control animal showed normal hepatocytes with a well defined cytoplasm, prominent nucleus, and a well organized portal triad [Figure2]. Liver sections from animals pretreated with 250 and 500 mg/kg body weight UV prior to treatment with CCl₄/ olive oil showed a dose dependent reduction in severity of liver damage observed in CCl₄/olive oil treated group [Figures 3, 5 and 6]. Silymarin at 50 mg/kg body weight also protected the liver from damage induced by CCl₄ with reduction in the severity of fat deposits in the hepatic parenchymal cells as shown in Figure 4. This investigation was supported by liver enzyme assay.

The level of activities of serum marker enzymes, such as AST, ALT and ALP can guide us to monitor liver function when hepatocytes are damaged, as these enzymes are released from the cytosol into the blood stream. Their level in the serum is a useful quantitative marker of the extent and type of the hepato-cellular damage (Mitra, *et al.*, 1998). There was significant ($P < 0.05$) increase in serum ALP level (54.90 ± 2.96) in Group B compared with the control group control (27.50 ± 2.50). On pretreatment with 250 mg/kg and 500 mg/kg body weight of aqueous extract of UV prior to CCl₄ treatment and 50 mg/kg body weight silymarin prior to CCl₄/olive oil treatment, there was a decrease (35.75 ± 2.17 ; 30.75 ± 2.02 and 28.25 ± 2.43 respectively) in ALP but the decrease

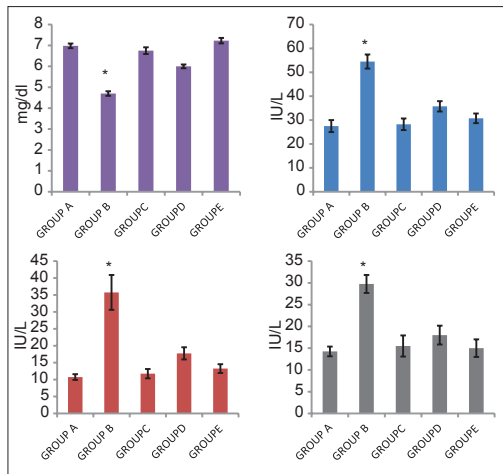


Figure 1: Bar graphs showing the effect of *Uvaria afzelii* extract on liver function enzymes. Mean difference is significant at $P < 0.05^*$ compared with control

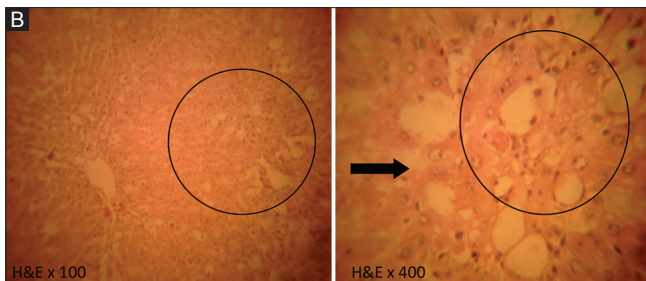


Figure 3: Micrograph of liver tissue of Group B (treated with of 1 ml/kg body weight of 30% carbon tetrachloride/olive oil mixture every 72 h) animals showing cytoplasmic deposit of large fat globules (circle) and mild degeneration of hepatocyte (arrow)

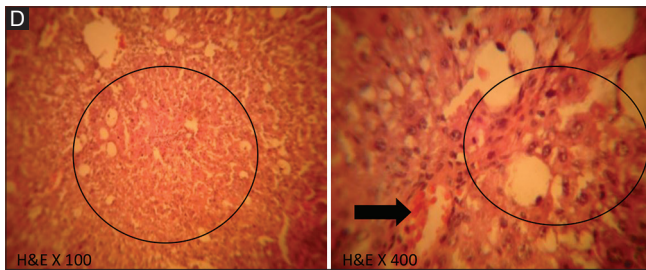


Figure 5: Micrograph of liver section of Group D (pretreated with 250 mg/kg body weight of *Uvaria afzelii* prior to treated with 1 ml of 30% carbon tetrachloride/olive oil mixture for 14 days) animals showing fairly moderate cytoplasmic fat deposits (circle) and portal vein congestion (arrow)

was not significant ($P < 0.05$) compared to control. Similarly, There was significant ($P < 0.05$) increase in serum transaminases (AST and ALT) (35.75 ± 5.14 and 29.75 ± 2.06 respectively) in Group B, animals treated with 1 ml of 30% CCL₄/olive oil, compared to the control group (10.75 ± 0.85 and 14.25 ± 1.11). On pretreatment with 250 mg/kg and 500 mg/kg body weight of aqueous extract of UV prior to CCL₄ treatment and 50 mg/kg body weight silymarin prior to CCL₄/olive oil treatment, there was a decrease in AST and ALT (17.75 ± 1.08 ; 18.00 ± 2.17 ; 13.25 ± 1.13 respectively and 15.00 ± 2.02 ; 11.75 ± 1.38 ; 15.50 ± 2.43), but the decrease was not

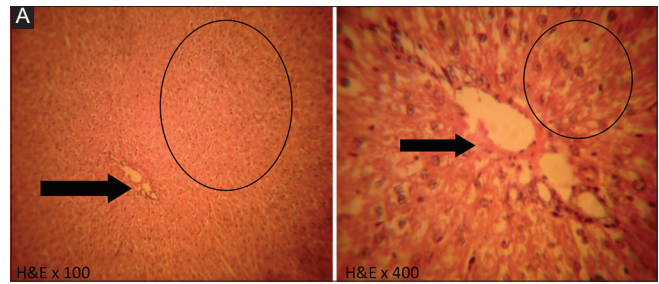


Figure 2: Micrograph of liver tissue of control animals (Group A) showing a normal portal triad (arrow) and hepatocytes (circle)

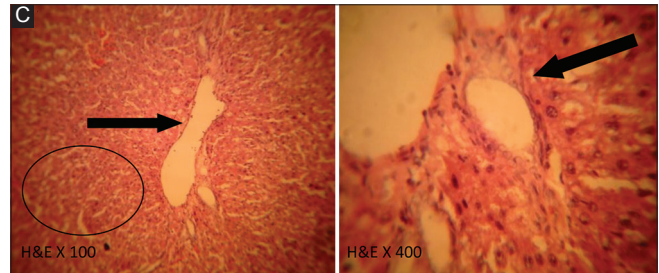


Figure 4: Micrograph of liver section of Group D (pretreated with 50 mg/kg body weight of silymarin prior to treated with 1 ml of 30% carbon tetrachloride/olive oil mixture for 14 days) animals showing mild tissue separation (circle) and portal area (arrow)

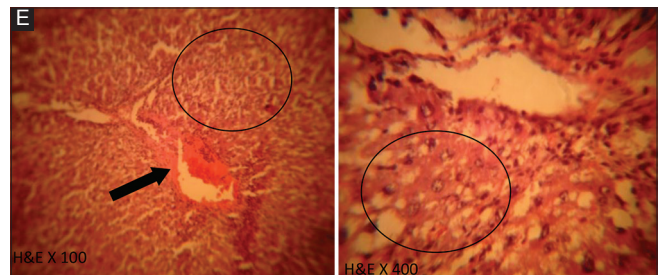


Figure 6: Micrograph of liver section of Group E (pretreated with 500 mg/kg body weight of *Uvaria afzelii* prior to treated with 1 ml of 30% carbon tetrachloride/olive oil mixture for 14 days) animals showing portal area with portal vein congestion (arrow) and severe reduction in cytoplasmic fat deposit (arrow)

significant ($P < 0.05$) compared to control. There was a significant ($P < 0.05$) decrease in the concentration of TP (4.70 ± 0.11) in the CCL₄ treated compared with control (6.98 ± 0.11). However, UV at 250 mg/kg body weight as well as silymarin at 50 mg/kg body weight showed no significant ($P < 0.05$) difference compared with control (6.00 ± 0.09 ; 7.23 ± 0.13 ; 6.75 ± 0.16 respectively).

From the results above, we could infer that aqueous extracts of UV possess hepatoprotective protection against CCL₄-induced liver damage just as silymarin, the standard liver protective drug. This finding had been corroborated by earlier studies, which attributed the protective potential of UV to presence of some phytochemical constituents, such as glycoside, flavonoid, terpenoids, phenols and sterols, in the root (Pietta, 2000; Jovanovic et al., 1994). Phyto-constituents such as flavonoids, triterpenoids and

phenols were reported to exhibit hepatoprotective activity (Pietta, 2000; Jovanovic *et al.*, 1994).

However, the active compounds of *Uvaria afzelii* responsible for the observed effects have not been identified in this study. Although, other researchers have postulated that the observed protective effect of the plant extract against CCL₄-induced liver damage may be attributed to the many compounds known to be protective against CCL₄-induced liver damage and exert their protective action by toxin-mediated lipid peroxidation either via a decreased production of CCL₄ derived free radicals or through the antioxidant activity of the protective agents themselves (Jayatilaka *et al.*, 1990 and Thabrew *et al.*, 1987).

Conclusively, the mechanism by which *Uvaria afzelii* exerts its protective action against CCL₄-induced damage in the liver may be due to the antioxidative effect of the plant extract. It is, therefore, recommended that further studies be carried out to decipher the mechanism as well as the exact constituent of *Uvaria afzelii* root extract responsible for its hepatoprotective potential.

REFERENCES

- Bouquet A., Debray M. (1974). Medicinal Plants of the Ivory Coast. Trau. Doc. Orstom. Seru. Cent. Document Orstom; 310-21.
- Dhuley J.N., Naik S.R. (1997). Protective effect of Rhinax, a herbal formulation, against CCL₄-induced liver injury and survival in rats. *J Ethnopharmacol* 56: 159-64.
- Drury R.A., Wallington E.A., Cameron R.C. (1976). *Histological Techniques*. 4th ed. Oxford University Press, New York, U.S.A. 279-80.
- Flora K., Hahn M., Rosen H., Benner K. (1998). Milk thistle (*Silybum marianum*) for the therapy of liver disease. *Am J Gastroenterol* 93: 139-43.
- Gill L.S. (1989). *Ethnomedical Uses of Plants in Nigeria*. University of Benin Press, Benin City, Nigeria. 134.
- Rao G.M., Rao C.V., Pushpangadan P., Shirwaikar A. (2006). Hepatoprotective effects of rubiadin, a major constituent of *Rubia cordifolia* Linn. *J Ethnopharmacol* 103: 484-90.
- Handa S.S., Sharma A., Chakraborti K.K. (1986). Natural products and plants as liver protecting drugs. *Fitoterapia* 57: 307-51.
- Jayatilaka K.A., Thabrew M.I., Perera D.J. (1990). Effect of Melothria maderaspatana on carbon tetrachloride-induced changes in rat hepatic microsomal drug-metabolizing enzyme activity. *J Ethnopharmacol* 30: 97-105.
- Jovanovic S., Steekens S., Mihaylo T., Marjanovic B., Simic M. (1994). Flavonoids as antioxidants. *J Am Chem Soc* 116 (11): 4846-51.
- Kayode J., Ige O.E., Adetogo T.A., Igbakin A.P. (2009). Conservation and biodiversity erosion in Ondo State, Nigeria: (3). Survey of plant barks used in native pharmaceutical extraction in akoko region. *Ethnobotanical Leaflet* 13: 665-7.
- Kerharo J., Bouquet A. (1950). *Plants medicinale et toxique de la Cote d'ivoire, Haute-Volta*. Vigot Frères, Paris, France. 165-240.
- Kren V., Walterová D. (2005). Silybin and silymarin – New effects and applications. *Biomed Pap Med Fac Univ Palacky Olomouc Czech Repub* 149 (1): 29-41.
- Lawal T.O., Adeniyi B.A., Wan B., Franzblau S.G., Mahady G.B. (2011). *In vitro* susceptibility of Mycobacterium tuberculosis to extracts of *Uvaria afzelii* Scott Eliot and *Tetracera alnifolia* wild. *Afr J Biomed Res* 14: 17-21.
- Meyer S.A., Kulkarni A.P. (2001). In: *Introduction to Biochemical Toxicology*. 3rd ed. John Wiley and Sons, New-York. 487.
- Mitra S.K., Seshadri S.J., Venkataranganna M.V., Gopumadhavan S., Udupa U.V., Sarma D.N. (2000). Effect of HD-03 – A herbal formulation in galactosamine-induced hepatopathy in rats. *Indian J Physiol Pharmacol* 44: 82-6.
- Mitra S.K., Venkataranganna M.V., Sundaram R., Gopumadhavan S. (1998). Protective effect of HD-03, a herbal formulation, against various hepatotoxic agents in rats. *J Ethnopharmacol* 63: 181-6.
- Odugbemi T. (2008). *A Textbook of Medicinal Plants from Nigeria*. University of Lagos Press, Lagos, Nigeria. 467.
- Okoli A.S. (2004). Evaluation of extracts of *Anthocheista djalensis*, *Nauclea latifolia* and *Uvaria afzelii* for activity against bacterial isolates from non-gonococcal urethritis. *J Ethnopharmacol* 92: 235-44.
- Okpekon T., Millot M., Champy P., Gleye C., Yolu S., Bories C., *et al.* (2009). A novel 1-indanone isolated from *Uvaria afzelii* roots. *Nat Prod Res* 23 (10): 909-15.
- Opoku A.R., Ndlovu I.M., Terblanche S.E., Hutheging A.H. (2007). *In vivo* hepatoprotective effects of *Rhoicissus tridentata* subsp. euneifolia, a traditional Zulu medicinal plant, against CCL₄-induced acute liver injury in rats. *South Afr J Bot* 73: 372-7.
- Pietta P. (2000). Flavonoids as anti-oxidants. *J Nat Prod* 63 (7): 1037-47.
- Ramadan L.A., Roushdy H.M., Abu Senna G.M., Amin N.E., El-Deshw O.A. (2002). Radioprotective effect of silymarin against radiation induced hepatotoxicity. *Pharmacol Res* 45 (6): 447-54.
- Recknagel R.O. (1967). Carbon tetrachloride hepatotoxicity. *Pharmacol Rev* 19: 145-208.
- Reitman S., Frankel S.A. (1957). Colorimetric method for the determination of serum levels of glutamic oxaloacetic acid and pyruvic acid transaminases. *Am J Clin Pathol* 10: 394-9.
- Rubinstein D. (1962). Epinephrine release and liver glycogen levels after carbon tetrachloride administration. *Am J Physiol* 203: 1033-7.
- Abdel Salam O.M., Sleem A.A., Omara E.A., Hassan N.S. (2007). Effect of ribavirin alone or combined with silymarin on carbon tetrachloride induced hepatic damage in rats. *Drug Target Insights* 2: 19-27.
- Stoyanovsky D.A., Cederbaum A.I. (1999). Metabolism of carbon tetrachloride to trichloromethyl radical: An ESR and HPLC-EC study. *Chem Res Toxicol* 12: 730-6.
- Subramoniam A., Evans D.A., Rajasekharan S., Pushpangadan P. (1998). Hepatoprotective activity of *Trichopus zeylanicus* extract against paracetamol-induced hepatic damage in rats. *Indian J Exp Biol* 36: 385-9.
- Thabrew M.I., Joice P.D., Rajatissa W. (1987). A comparative study of the efficacy of *Pavetta indica* and *Osbeckia octandra* in the treatment of liver dysfunction. *Planta Med* 53: 239-41.
- Venkateswaran S., Pari L., Viswanathan P., Menon V.P. (1997). Protective effect of Livex, a herbal formulation against erythromycin estolate induced hepatotoxicity in rats. *J Ethnopharmacol* 57: 161-7.
- Wills P.J., Asha V.V. (2006). Protective effect of *Lygodium flexuosum* (L.) Sw. extract against carbon tetrachloride-induced acute liver injury in rats. *J Ethnopharmacol* 108: 320-6.
- Wolf P.L. (1999). Biochemical diagnosis of liver disease. *Indian J Clin Biochem* 14: 59-90.

How to cite this article: Omoruyi SI, Joan MI, Bijou EA, Iroboodu MO. *Uvaria afzelii* root extract protects the liver against damage caused by carbontetrachloride ingestion. *J Exp Clin Anat* 2014;13:40-4.

Source of Support: Nil, **Conflict of Interest:** None declared.