

Morphological evaluation of the superior colliculus of young Wistar rats following prenatal exposure to *Carica papaya* leaf extract

Enaibe B. U., Omotoso G. O., Olajide O. J., Lewu S. F., Adeyemi S. O.

Department of Anatomy, Faculty of Basic Medical Sciences, College of Health Sciences, University of Ilorin, Ilorin, Nigeria

Abstract

Aim: This study was carried out to determine the effects of prenatal administration of *Carica papaya* on the superior colliculi (SC) of Wistar rats. **Materials and Methods:** Twenty adult female Wistar rats were mated and randomly assigned to 4 groups, each comprising of 5 rats. The aqueous leaf extract of *C. papaya* was prepared at a concentration of 100 mg/kg, and administered to rats on days 9 and 10 of gestation (Group A); days 16 and 17 (Group B); and on days 9, 10, 16 and 17 (Group C); while Group D represented the control, and received distilled water throughout gestation. The grouping was designed to represent 2nd gestational week (Group A), 3rd gestational week (Group B), and a combination of 2nd and 3rd gestational week (Group C). After the pregnant rats had littered, the pups were sacrificed on postnatal days 1, 14 and 35. The SCs was identified in the brain specimen and fixed in 10% formol calcium, and the tissue was processed for histological studies using hematoxylin and eosin stains. **Results:** The leaf extract of *C. papaya* was associated with low birth weight, changes in growth rate and morphological changes in the histology of SCs, especially in animals exposed during the 3rd week of gestation. **Conclusion:** The use of *C. papaya* leaf extract during pregnancy is detrimental to fetal development and can affect the morphology and function of the SCs, with possible neurologic deficits after birth.

Key words: *Carica papaya*, histology, prenatal, superior colliculus

INTRODUCTION

Plants have attracted attention in most parts of the world due to their medicinal and dietary values. Some

Address for correspondence:

Dr. Gabriel O. Omotoso,
Department of Anatomy, Faculty of Basic Medical Sciences, College
of Health Sciences, University of Ilorin, P.M.B. 1515, Ilorin, Nigeria.
E-mail: gabrielolaiya@yahoo.com

Access this article online	
Quick Response Code:	Website: www.jecajournal.org
	DOI: 10.4103/1596-2393.154393

of these medicinal plants have been noted to be of therapeutic effects in the management of certain diseases. However, when excessively consumed, they could result in damage of particular tissues in the body or vital functions of the body (Soladoye *et al.*; 2010). The use of medicinal plants in pregnancy is delicate, and the effects on the growing fetus might be quite detrimental. Unfavorable pregnancy outcomes have been noticed following exposure of the growing fetus to certain plant preparations or drugs (Enaibe *et al.*; 2012, Omotoso *et al.*; 2013). Hence, pregnant women are usually advised to avoid indiscriminate use of medications during pregnancy to prevent adverse fetal outcomes.

Papaya is a large, tree-like plant, with a single stem growing from 16 to 33 feet tall, with spirally arranged leaves confined to the top of the trunk. The lower trunk is conspicuously scarred where leaves and fruits are borne.

The leaves are large, 20-28 inches in diameter, deeply palmately lobed, with seven lobes (Ikeyi et al., 2013).

Various components of *C. papaya* have been used for their medicinal purpose, such as the fruits, leaves and seeds (Sadek, 2012). The fruit is rich in carotene, Vitamin C, Vitamin B, flavonoids, folate, and is a good source of fiber (Franco et al.; 1993). The leaf of *C. papaya* contains various phytochemicals, including alkaloids, cardiac glycosides, polyphenols and tannins which are all of great pharmacological importance (Nwiloh et al.; 2009).

The beneficial properties attributed to the extract of *C. papaya* include its use in the treatment of worm infestation, beriberi, rheumatism, fever, asthma, indigestion and cancer (Otsuki et al.; 2010, Akah et al.; 1997, Agoha, 1981). It is also said to have antioxidant properties, and has been useful in the treatment of cardiovascular diseases, such as in reducing the incidence of coronary artery disease and other heart diseases, and as antihypertensive and antihyperglycaemic (Mohamed Sadek, 2012, Andrade-Cetto and Heinrich, 2005, Haramaki et al.; 1995).

The superior colliculi (SC), which are visual reflex centers, form the rostral two bumps (one on each side) on the dorsal aspect of the midbrain. Although not exclusively related to visual function, SC plays some roles in helping orient the head and eyes to all types of sensory stimuli (Collins et al; 2005).

Aside the beneficial effects reported of *C. papaya*, other studies have observed detrimental effects following its use. According to Muhammed et al.; (2013) the seed of *C. papaya* was implicated in the disruption of the normal architecture of the SCs and cell morphology, whereas treatment with the pulp component had no deleterious effects.

The rationale for this study is to ascertain if the use of herbal concoction containing leaves extract of *C. papaya* is safe for consumption during pregnancy since the use of such concoction to combat various kinds of illnesses is common in this part of the world. Hence, this study examined the effect of prenatal administration of aqueous extract of *C. papaya* leaves on the morphology of young and Prepubertal Wistar rats, as well as the histology of the SCs, as a component of the visual pathway.

MATERIALS AND METHODS

Experimental Animals

Twenty female and five male Wistar rats with average weights of 220 g and 175 g respectively were used. The rats were procured from the Anatomy Laboratory of the Ladok Akintola University of Technology, Ogbomosho, Nigeria. The animals were allowed to acclimatise for 2 weeks

at the Animal House of the College of Health Sciences, University of Ilorin, where the study was conducted. They were exposed to normal laboratory conditions of temperature, light, and humidity. The rats were fed with growers mash (Bendel Feeds®) and water *ad libitum*. The animals were randomly assigned to four Groups A-D.

Determination of Proestrous Phase of the Estrous Cycle via Vaginal Smear

To determine the estrous cycle of the female rats, vaginal fluids were taken between 8 a.m. and 9 a.m. for analysis. This was done by inserting a plastic pipette containing 1 ml of normal saline into the vagina, emptying its content, then scooping it back into the pipette after 2 s and in the process taking the vagina fluid into the pipette. The vagina fluid was placed on a glass slide where $\times 10$ and $\times 40$ objective lenses of the light microscope were used to analyze the nature of the cells (Marcondes et al.; 2002). Cells that showed predominantly nucleated epithelial cells indicated pro-estrous stage of the sexual cycle (Marcondes et al.; 2002).

Mating of the Female Rats

Male rats were introduced into the cages of the female rats at the pro-estrous phase for mating. Pregnancy was confirmed by the presence of life spermatozoa after performing a vaginal smear the following morning. This was taken as the 1st day of conception.

Preparation of Aqueous Extract of *Carica papaya* Leaves

Carica papaya leaves were plucked from a farm in Tanke, Ilorin. The midribs and veins were removed after which the leaves were sliced into tiny pieces of about 0.5 cm and air-dried for 1-week. The dried leaves were then pulverised using an electric blender. 100 g of the powdered *C. papaya* was then soaked in 300 ml of distilled water for 72 h. The solution thereof was sieved using a clean sieve; the filtrate was poured into an amber reagent bottle and kept in a refrigerator at 4°C before each administration.

Treatment of Experimental Animals

- Group A pregnant rats received 100 mg/kg of AECPL on days 9 and 10 of gestation (2nd gestational week)
- Group B pregnant rats received 100 mg/kg of AECPL on days 15 and 16 of gestation (3rd gestational week)
- Group C pregnant rats received 100 mg/kg of AECPL on days 9, 10, 15 and 16 of gestation; and
- Group D pregnant rats served as a control and received water.

Administration of the extract was via the oral route.

Histological Procedures

After parturition, the weights of pups were monitored, and at postnatal days 1, 14 and 35 (P1, P14, P35), they were

sacrificed by cervical dislocation. The SCs was excised from the brain and fixed in formo-calcium for 72 h, dehydrated through graded alcohol solutions, cleared in xylene and embedded in molten paraffin wax. Tissue blocks were sectioned at 5 μm thickness, deparaffinized and stained with Hematoxylin and Eosin stains. The slides were examined under a light microscope.

RESULTS

Physical Observation

The total number of pups delivered by pregnant rats was highest in Group A and the control Group D, whereas it was least in Group B treated with the extract in the 3rd week of gestation. The average number of litters per pregnant rat was however highest in the control group compared with all the treated groups [Table 1].

The groups of rats that received the *C. papaya* leaf extract in the 2nd week of gestation (Group A) and in both 2nd and 3rd weeks of gestation (Group C) had low birth weights compared to the other groups. The rate of growth differed in all the groups, with Group A having the least growth rate, and consistently lower body weights compared with the control and other treated groups. Body weights at P14 and P35 were higher in Groups B and C compared with the Control. Group C rats had caught up weights as early as P7, and the weight was consistently higher than the Control till P35, though lower than Group B at P35 [Figure 1].

Table 1: Number of pups delivered

Groups	Average number of pups per rat	Total number of pups
A	8	32
B	8	18
C	9	27
D	10	30

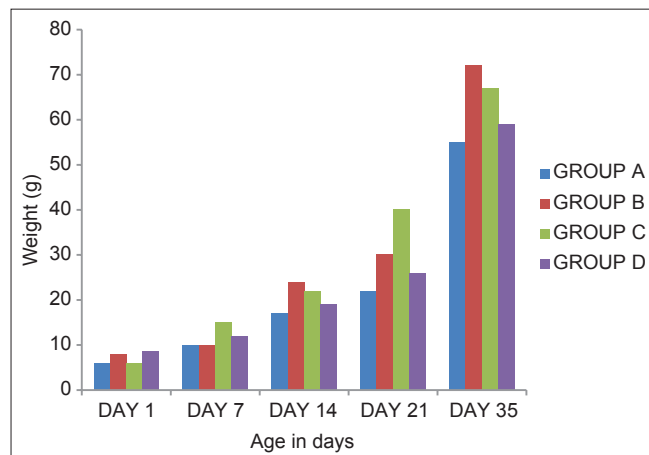


Figure 1: Average weights of pups

Histological Observation

The photomicrographs of the treated rats examined at P1, P14 and P35, showed relatively smaller-sized neurons compared with the control group. Group B animals that received the extract at the beginning of the 3rd week of intrauterine life showed poorly stained cells and lower population of cells compared with other treated groups and control [Figures 2-4]. At P35, Group B showed markedly reduced population of cellular components. Closer observation showed most neurons in treated Groups A and C and control Group D have centrally placed and fairly prominent nuclei when compared with those from Group B.

DISCUSSION

The use of *C. papaya* has been shown to adversely affect reproductive parameters especially in males; hence, its use as antifertility preparation (Lohiya *et al.*; 2005). Earlier studies by (Abdulazeez *et al.*; 2009) showed that the unfermented seed extract of *C. papaya* adversely affects female reproduction, with particular effect on the implantation process. This might account for the low number of pups, especially in rats treated with *C. papaya* in the 2nd week of gestation, although there was no evidence suggestive of fetal loss.

Low birth weight was a characteristic feature of all animals exposed to *C. papaya* leaf extract, but this was minimal in rats treated in the 3rd week of gestation. Body weight was consistently reduced in animals exposed to the extract in the 2nd week of intrauterine life, whereas animals administered with *C. papaya* in the 3rd week of gestation had a form of catch up growth exceeding the rate of growth of the control animals. However, in

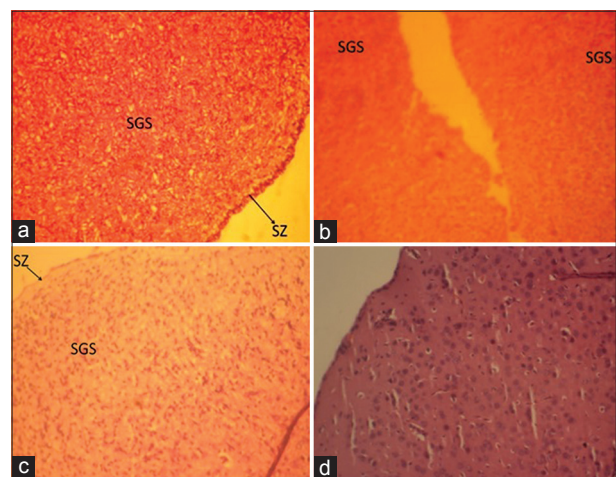


Figure 2: (a-d): Photomicrographs of the superficial layer of the superior colliculus of a day old Wistar rats showing numerous neurons in treated Groups A and C, and control Group D compared with treated Group B. The cells in all the treated groups appeared smaller in size compared with the control, while treated Group B appeared poorly stained. SZ: Stratum zonale, SGS: Stratum superficialis. H and E, $\times 100$

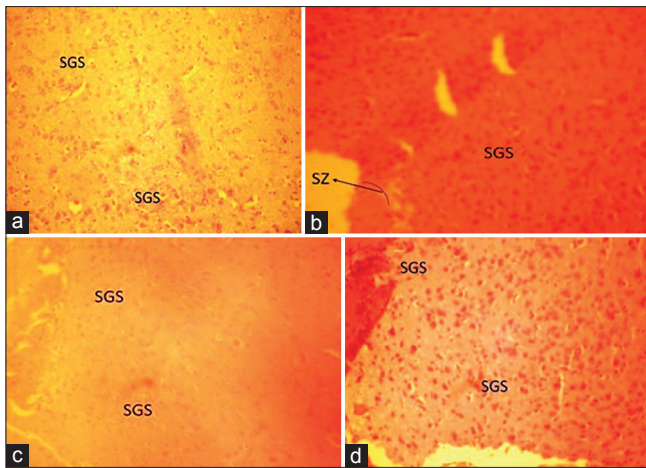


Figure 3: (a-d): Photomicrographs of the superficial layer of the superior colliculus of 14 days old Wistar rats showing reduction in number of neurons in all the treated groups, and especially Group B that received the *Carica papaya* extract in their 3rd week of intrauterine life. SZ: Stratum zonale, SGS: Stratum superficialis. H and E, $\times 100$

another study by (Abdulazeez *et al.*; 2009) only very minimal and nonsignificant reduction in weight was observed in rats treated with *C. papaya* during the 1st and 2nd weeks of gestation. Administration of the leaf extract of *C. papaya* has previously been shown to induce a significant reduction in blood glucose level (Juárez-Rojop *et al.*; 2012), and a decrease in the activity of carbohydrate-hydrolyzing enzymes in the small intestine, with a consequent reduction in the conversion of disaccharides into absorbable monosaccharides, have been suggested as possible mechanisms (Juárez-Rojop *et al.*; 2012, Hamden *et al.*; 2011). This might contribute to the reduction in weight noticed in the current study.

The SC is a visual relay center that transforms both visual and nonvisual sensory signals into motor commands that control orienting behaviors (Omotoso *et al.*; 2013). Previous studies on the effects of the seeds of *C. papaya* on the SC of adult rats revealed some degree of degeneration of the neuronal cells (Muhammed *et al.*; 2013). In the current study, aqueous extract of the leaf of *C. papaya* was administered to pregnant rats at different gestational periods to observe the effects on the developing SC. Postnatal histological assessment of the SC of the prenatally exposed rats showed some degrees of alterations in the general architecture of the tissue and an apparent reduction in cell population. The 3rd week of gestation of rats appeared, in this study, to be most vulnerable to this toxic effect. This observation revealed that the leaf extract of *C. papaya* is neuroteratogenic to the developing SC.

Cellular processes involved in neurodevelopment are usually susceptible to the effects of neurotoxic substances, which could result in different varieties of neurodevelopmental and neurological disorders in




Figure 4: (a-d): Photomicrographs of the superficial layer of the superior colliculus of 35 days old Wistar rats showing markedly reduced population of cellular components in treated Group B that received *Carica papaya* extract in their 3rd week of intrauterine life. SZ: Stratum zonale, SGS: Stratum superficialis. H and E, $\times 100$

postnatal life (Giordano and Costa, 2012). However, further definitive researches are required to identify specifically the processes affected following insult by this extract prenatally, as well as associated neurological disorders, especially as it relates to the visual pathway and other functions of the SCs.

Although no neurological examinations were conducted for the animals in the current study prior to their sacrifice, the structural alterations in the SC warrant further study on the other component of the developing visual pathway, as well as neurologic and visual function tests in subjects exposed to *C. papaya* during pregnancy.

In conclusion, the use of the leaf extract of *C. papaya* during pregnancy is detrimental to fetal development and can affect the morphology and function of the SCs in later life.

REFERENCES

1. Soladoye M.O., Amusa N.A., Raji-Esan S.O., Chukwuma E.C., Taiwo A.A. (2010). Ethnobotanical survey of anti-cancer plants in Ogun State, Nigeria. *Ann Biol Res* 1 (4): 261-73.
2. Enaibe B.U., Omotoso G.O., Ayanwale O.O. (2012). Histological evaluation of the embryotoxic and neurotoxic effects of *Mangifera indica* in prenatally exposed Wistar rats. *J Exp Clin Anat* 11 (2): 8-13.
3. Omotoso G.O., Ibitolu J.O., Femi-Akinlosotu O.M., Akinola O.B., Enaibe B.U. (2013). Morphological and neurohistological changes in adolescent rats administered with nicotine during intrauterine life. *Niger J Physiol Sci* 28 (2): 147-51.
4. Ikeyi A.P., Ogbonna A.O., Eze F.U. (2013). Phytochemical analysis of pawpaw (*Carica papaya*) leaves. *Int J Life Sci Biotechnol Pharm Res* 2 (3): 347-51.
5. Mohamed Sadek K. (2012). Antioxidant and immunostimulant effect of *Carica papaya* linn. Aqueous extract in acrylamide intoxicated rats. *Acta Inform Med* 20: 180-5.
6. Franco M.R.B., Amaya D., Rodriguez M.H., Carrillo J.L. (1993). Volatile components and flavour of pawpaw (*Carica Papaya*): A reappraisal. *Alimentose Nutrexao* 5: 99-108.

7. Nwilo B.I., Nwinuka N.M., Monanu M.O. (2009). The effect of aqueous extract of *Carica papaya* leaves on liver enzyme and blood cell counts of normal albino rats. *Int J Biol Chem Sci* 3 (3): 561-6.
8. Otsuki N., Dang N.H., Kumagai E., Kondo A., Iwata S., Morimoto C. (2010). Aqueous extract of *Carica papaya* leaves exhibits anti-tumor activity and immunomodulatory effects. *J Ethnopharmacol* 127: 760-7.
9. Akah P., Oli A., Enwerem N., Gamaniel K. (1997). Preliminary studies on purgative effect of *Carica papaya* root extract. *Fitoterapia* 68 (4): 327-31.
10. Agoha R.C. (1981). *Medical Plants of Nigeria*. Offset Drukkerij Faculted Der Wiskunde en Natuorwetens, Chappens, Nijmegen, Netherland.
11. Andrade-Cetto A., Heinrich M. (2005). Mexican plants with hypoglycaemic effect used in the treatment of diabetes. *J Ethnopharmacol* 99: 325-48.
12. Haramaki N., Marceoci L., D'Anna R., Yan L.J., Kobuchi H., Packer L. (1995). Fermented papaya preparation supplementation: Effect on oxidative stress to isolated rat hearts. *Biochem Mol Biol Int* 36 (6): 1263-8.
13. Collins C.E., Hendrickson A., Kaas J.H. (2005). Overview of the visual system of *Tarsius*. *Anat Rec A Discov Mol Cell Evol Biol* 287 (1): 1013-25.
14. Muhammed O.A., Adekomi A.D., Enaibe B.U., Ademosun A.A. (2013). Histological, histochemical and immunohistochemical evaluation of the effects of seed and pulp of *Carica papaya* on the visual relay centres in animal model. *J Med Plants Res* 7 (16): 1030-8.
15. Marcondes F.K., Bianchi F.J., Tanno A.P. (2002). Determination of the estrous cycle phases of rats: Some helpful considerations. *Braz J Biol* 62 (4a): 609-14.
16. Lohiya N.K., Mishra P.K., Pathak N., Manivannan B., Bhande S.S., Panneerdoss S., et al. (2005). Efficacy trial on the purified compounds of the seeds of *Carica papaya* for male contraception in albino rat. *Reprod Toxicol* 20 (1): 135-48.
17. Abdulazeez M.A., Ameh A.D., Ibrahim S., Ayo J.O., Ambali S.F. (2009a). Effect of fermented and unfermented seed extracts of *Carica papaya* on pre-implantation embryo development in female Wistar rats (*Rattus norvegicus*). *Sci Res Essay* 4 (10): 1080-4.
18. Abdulazeez M.A., Ameh A.D., Ibrahim S., Ayo J.O., Ambali S.F. (2009b). Effect of fermented seed extract of *Carica papaya* on litters of female Wistar rats (*Rattus norvegicus*). *Afr J Biotechnol* 8(5): 854-7.
19. Juárez-Rojop I.E., Díaz-Zagoya J.C., Ble-Castillo J.L., Miranda-Osorio P.H., Castell-Rodríguez A.E., Tovilla-Zárate C.A., et al. (2012). Hypoglycemic effect of *Carica papaya* leaves in streptozotocin-induced diabetic rats. *BMC Complement Altern Med* 12: 236.
20. Hamden K., Jaouadi B., Zarái N., Rebai T., Carreau S., Elfeki A. (2011). Inhibitory effects of estrogens on digestive enzymes, insulin deficiency, and pancreas toxicity in diabetic rats. *J Physiol Biochem* 67 (1): 121-8.
21. Omotoso G.O., Enaibe B.U., Caxton-Martins E.A. (2013). Microarchitectural changes in the superior colliculi of male Wistar rats after cigarette and cotton wool smoke exposure. *Trop J Health Sci* 20 (1): 37-40.
22. Giordano G., Costa L.G. (2012). Developmental neurotoxicity: Some old and new issues. *ISRN Toxicol* 2012: 814795.

How to cite this article: Enaibe BU, Omotoso GO, Olajide OJ, Lewu SF, Adeyemi SO. Morphological evaluation of the superior colliculus of young Wistar rats following prenatal exposure to *Carica papaya* leaf extract. *J Exp Clin Anat* 2014;13:29-33.

Source of Support: Nil, **Conflict of Interest:** None declared.