

# Histomorphological Effect of Zidovudine on the Testes of Adult Male Wistar Rats (*Rattus Novegicus*)

Lilian E Chris-Ozoko, Aienobe A Charity, Victor O Ekundina

Department of Anatomy, Delta State University, Abraka, Delta State, Nigeria

## ABSTRACT

**Background:** Zidovudine (ZDV) also referred to as azidothymidine (AZT) was the first approved treatment for human immunodeficiency virus, although, its impact on the reproductive system has not been clearly understood. **Aim:** The aim is to analyze the effect of dose dependent administration of ZDV (AZT) on the testes of adult Wistar rats was carefully studied. **Materials and Methods:** The rats ( $n=20$ ), with an average weight of 150 g were randomly assigned in to a control group (Group 1) ( $n=5$ ) and three treatment groups ( $n=5$ ). The control Group 1 received distilled water while the treatment groups divided into Group 2, (subnormal), Group 3 (normal) and Group 4 (excess) were administered 0.3 mg/ml, 1.3 mg/ml and 2.3 mg/ml of AZT respectively (in line with the recommended dose of 600 mg/70 kg) dissolved in distilled water daily for 30 days, using an orogastric cannula. The rats were fed with growers mash and given water liberally. The rats were euthanized under chloroform vapor on the 31<sup>st</sup> day of the experiment, and the testes were carefully harvested and fixed in 10% formol saline for histological studies. **Results:** Histological results of treated group revealed significant changes in testes histoarchitecture (the control showed normal histoarchitecture). **Conclusion:** ZDV may cause structural abnormalities to testicular tissues.

**KEY WORDS:** Hypospermatogenesis, structural abnormalities, testes, zidovudine

## INTRODUCTION

Zidovudine (ZDV) also referred to as azidothymidine (AZT) was the first approved treatment for human immunodeficiency virus (HIV), under the names Retrovir and Retrovis. AZT use was a crucial breakthrough in acquired immunodeficiency syndrome (AIDS) therapy in the 1990s that significantly altered the course of the disease and helped to destroy the notion that HIV/AIDS was a death sentence. ZDV is a nucleoside analog nucleotide reverse transcriptase inhibitors (NRTI) a variety of antiretroviral drug used for the treatment of HIV/AIDS.

Nucleoside and NRTI inhibit reverse transcription by being incorporated into the newly synthesized viral deoxyribonucleic acid (DNA) strand as a faulty nucleotide. This causes a chemical reaction resulting in DNA chain termination.<sup>[1]</sup>

HIV is a *lentivirus* (a member of the retrovirus family) that causes AIDS<sup>[2,3]</sup> a condition in humans in which progressive failure of the immune system allows life-threatening opportunistic infections and cancers to thrive. Infection with HIV occurs by the transmission through body fluids such as blood, semen, vaginal fluid, pre-ejaculate or breast milk. Within these body fluids, HIV is present as both free virus particles and virus within infected immune cells. *Lentiviruses* have many morphologies and biological properties in common. Many species are infected by *lentiviruses*,<sup>[4]</sup> which are characteristically responsible for long-duration illnesses with a long incubation period.

Two types of HIV have been characterized: HIV-1 and HIV-2. HIV-1 is more virulent, more infective;<sup>[5]</sup> and is the cause of the majority of HIV infections globally. The lower infectivity of HIV-2 compared to HIV-1 implies that fewer of those exposed to HIV-2 will be infected per exposure. Because of its relatively limited capacity for transmission, HIV-2 is largely confined to West Africa.<sup>[6]</sup> The effect of ZDV on the histology of some organs especially the liver has been studied,<sup>[7]</sup> but there is a dearth of information on

### Access this article online

#### Quick Response Code



#### Website:

www.jbcrs.org

#### DOI:

10.4103/2278-960X.118642

#### Address for correspondence

Dr. Lilian E Chris-Ozoko,  
Department of Anatomy, Delta State University, PMB1,  
Abraka, Delta State, Nigeria.  
E-mail: lilyzoks@yahoo.com

the effect of this drug on the testicular histoarchitecture. Although the combination of ZDV and lamivudine has been found to reduce sperm motility and testosterone level,<sup>[8]</sup> the actual histological changes in the testis is still unclear. Consequently, the aim of this work is to determine whether any changes occur in testicular histologic patterns and whether it affects reproductive functions. This is to appreciate the importance of retroviral drugs (ZDV) and to add to the information already available on the drug.

## MATERIALS AND METHODS

A total of 20 adult male Wistar rats, obtained from the animal house of the faculty of basic medical sciences Delta state university, with an average weight of 150 g were used for this study. They were divided into four groups made up of five rats each, fed growers mash, obtained from top feeds, Sapele, Delta State, Nigeria given water liberally and acclimatized for a week. Daily consumption of 0.3 mg/ml, 1.3 mg/ml, and 2.3 mg/ml of ZDV, obtained from the pharmacy unit of central hospital Benin city. In consonance with the administration by Sikka *et al.*<sup>[9]</sup> was administered orally to rats in Groups 2 (subnormal dose group), 3 (normal dose group), and Group 4 (excess dose group) respectively for 30 days using an orogastric cannula, while rats in Group 1 were administered distilled water only. The rats were also weighed weekly. The rats were euthanized under chloroform vapor on the 31<sup>st</sup> day and the testes harvested from each group were fixed in 10% formol saline. These were then processed for histological examination using hematoxylin and eosin stains. Photomicrographs were obtained using a digital microscopic eyepiece.

Numerical data were presented as mean and standard deviation, using SPSS version 15.0 (Chicago, Illinois, USA).

## RESULTS

### Histopathological examination of testes tissue

#### **Micrograph 1**

Group 1 (control, distilled water). Normal testes. Sections of the testes showed normal histoarchitecture with typically organized layers of spermatogenic cells at different stages of maturation (H and E,  $\times 100$ ).

#### **Micrograph 2**

Group 2 (subnormal, 0.3 mg/ml of ZDV). Sections showed distortion of the tubular architecture and disorganization of the spermatogenic cells in seminiferous tubules (H and E,  $\times 100$ ).

#### **Micrograph 3**

Group 3 (normal, 1.3 mg/ml of ZDV). Sections showed disruption of tissue architecture and disorganization of

the spermatogenic cells with intratubular vacuolation (H and E,  $\times 100$ ).

#### **Micrograph 4**

Group 4 (excess, 2.3 mg/ml). Sections of testes also showed marked distorted tissue architecture with seminiferous tubules of various sizes coalescing in most cases and separated by fibro connective tissue with marked desmoplasia (H and E,  $\times 40$ ).

#### **Micrograph 5**

Group 4 (excess, 2.3 mg/ml). Sections showed distortion of tissue architecture and wide lumens with few germ cells (H and E,  $\times 100$ ).

#### **Micrograph 6**

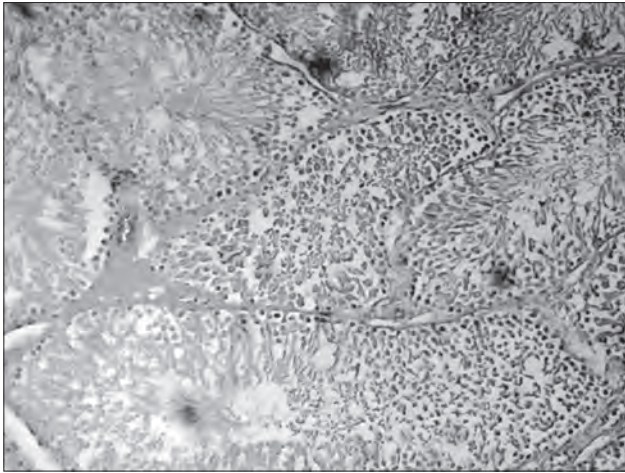
Group 4 (excess, 2.3 mg/ml). Sections showed distortion of tissue architecture with few germ cells, sparse interstitial cells and absent spermatids (H and E,  $\times 400$ ).

## DISCUSSION

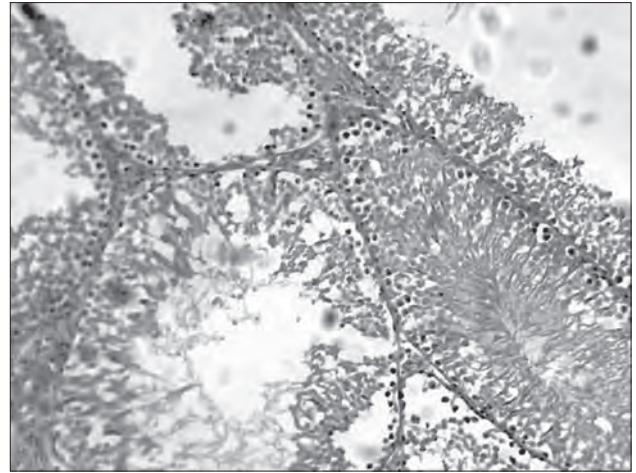
In this study, testicular histology of Group 1 [Figure 1] (control group) (administered water only) was normal as they showed normal arrangement of spermatogenic cells. The testicular histology of Group 2 [Figure 2] (subnormal dose) (administered 0.3 mg/ml of AZT daily) showed desquamation of tubular architecture and a disorganized arrangement of spermatogenic cells (spermatids and spermatogonia). Testicular histology in Group 3 [Figure 3] (normal dose, administered 1.3 mg/ml of AZT daily), also followed the same pattern seen in Group 2 but was accompanied with intratubular vacuolation (vacuoles were honey-comb in appearance). While testicular histology in Group 4 [Figures 4-6] (excess dose) (administered 2.3 mg/ml of AZT daily) also showed desquamation of tubular architecture, absent spermatids and few spermatogenic (germ) cells at early phases of maturation.

The observed testicular histologic changes seen in the treated groups are in keeping with dose dependent testicular atrophy with hypospermatogenesis, resulting in fertility problems as was implied by Clayton.<sup>[10]</sup> He stated that some antiretrovirals, particularly ZDV and other older nucleoside reverse transcriptase inhibitors may affect fertility in people with HIV. The histological pattern has been responsible for the reduced sperm motility obtained by Osonuga *et al.*<sup>[8]</sup>

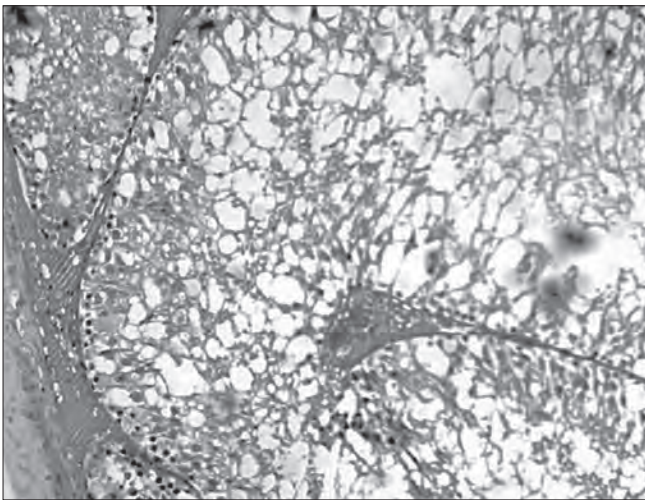
This result is at variance with the work by Shevchuk *et al.*<sup>[11]</sup> while working with one hundred and forty specimens from AIDS autopsies, though observed in one group that hypospermatogenesis seen in the pre-AZT period (1981-1987) remained constant during



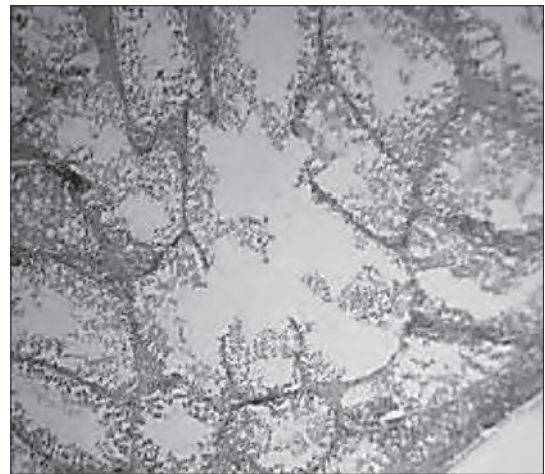
**Figure 1:** Group 1 (control, distilled water). Normal testes. Sections of the testes showed normal histoarchitecture with typically organized layers of spermatogenic cells at different stages of maturation (H and E,  $\times 100$ )



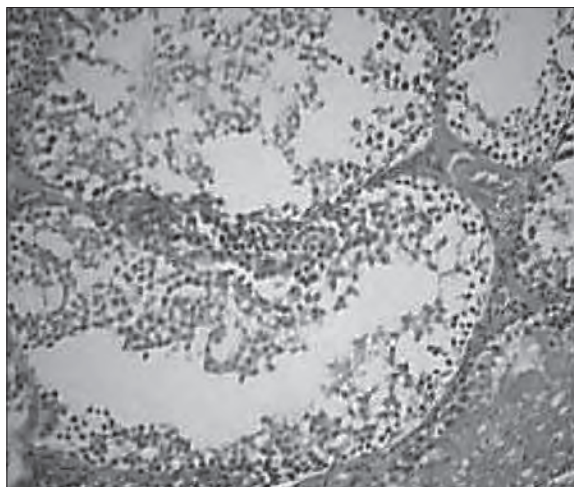
**Figure 2:** Group 2 (subnormal, 0.3 mg/ml of zidovudine). Sections in this group showed distortion of the tubular architecture and disorganization of the spermatogenic cells in seminiferous tubules (H and E,  $\times 100$ )



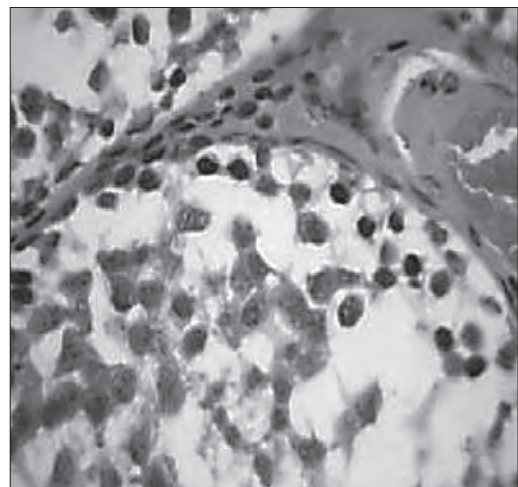
**Figure 3:** Group 3 (normal, 1.3 mg/ml of zidovudine). Sections in this group showed disruption of tissue architecture and disorganization of the spermatogenic cells with intratubular vacuolation (H and E,  $\times 100$ )



**Figure 4:** Group 4 (excess, 2.3 mg/ml). Sections of testes also show marked distorted tissue architecture with seminiferous tubules of various sizes coalescing in most cases and separated by fibro connective tissue with marked desmoplasia (H and E,  $\times 40$ )



**Figure 5:** Group 4 (excess, 2.3 mg/ml). Sections in this group showed distortion of tissue architecture and wide lumens with few germ cells (H and E,  $\times 100$ )



**Figure 6:** Group 4 (excess, 2.3 mg/ml). Sections in this group showed distortion of tissue architecture with few germ cells, sparse interstitial cells and absent spermatids (H and E,  $\times 400$ )

the post-AZT period (1988-1998) and also observed a reduction in spermatogenic arrest between the two periods they also noted that heterosexual intercourse as the commonest means of transmission of HIV is associated with promiscuity and thus increased chances of sexually transmitted disease (STI) Furthermore, STIs, e.g., *Chlamydia trachomatis*, *Neisseria gonorrhoeae* on their own causes epididymo-orchitis and male factor infertility. They concluded that reduction in arrest in spermatogenesis seen in their study may be partly due to STIs already in the system, which the use of ZDV helped to ameliorate by improving immunity. Compared with the deliberate use of ZDV on HIV uninfected Wistar rats in our study, the effects seen on the testis undoubtedly reflects the effects of ZDV on mammalian testis and rules out the possible contribution of STIs including HIV.

At best we can only conclude, like Sikka *et al.* that the effect of ZDV on the reproductive system in the male rats is subtle and complex,<sup>[9]</sup> but never to be ruled out. Indeed some authors have suggested that the deleterious effects of antiretroviral drugs to the male reproductive system may not be unrelated to the production of highly reactive oxygen radicals, and subsequent induction of oxidative stress.<sup>[12]</sup>

In view of the above findings, precautionary measures should be taken with administration of ZDV, especially in men who are yet to complete their families considering the high premium placed on fertility and child bearing in our unique socio-cultural environment.<sup>[13]</sup>

The authors have been able to demonstrate that some antiretroviral drugs are deleterious to the male reproductive system of rats. However, the study did not determine the STI statuses of rats and also was not able to determine the concise mechanism of these effects. Further, studies are needed while controlling for this confounding variable, to include also, the analysis of semen, and male reproductive hormone levels.

In conclusion, ZDV may have a destructive effect on the

histoarchitecture of the testis. This will most likely affect the function of spermatozoa and invariably lead to male factor infertility.

## REFERENCES

1. Barr SD, Smiley JR, Bushman FD. The interferon response inhibits HIV particle production by induction of TRIM22. *PLoS Pathog* 2008;4:e1000007.
2. Weiss RA. How does HIV cause AIDS? *Science* 1993;260:1273-9.
3. Douek DC, Roederer M, Koup RA. Emerging concepts in the immunopathogenesis of AIDS. *Annu Rev Med* 2009;60:471-84.
4. Levy JA. HIV pathogenesis and long-term survival. *AIDS* 1993;7:1401-10.
5. Gilbert PB, McKeague IW, Eisen G, Mullins C, Guéye-NDiaye A, Mboup S, *et al.* Comparison of HIV-1 and HIV-2 infectivity from a prospective cohort study in Senegal. *Stat Med* 2003;22:573-93.
6. Reeves JD, Doms RW. Human immunodeficiency virus type 2. *J Gen Virol* 2002;83:1253-65.
7. Duong Van Huyen JP, Landau A, Piketty C, Bélair MF, Batisse D, Gonzalez-Canali G, *et al.* Toxic effects of nucleoside reverse transcriptase inhibitors on the liver. Value of electron microscopy analysis for the diagnosis of mitochondrial cytopathy. *Am J Clin Pathol* 2003;119:546-55.
8. Osonuga IO, Osonuga OA, Osonuga AA. Gonadotoxicity evaluation of oral administration of zidovudine in male albino rats. *Maced J Med Sci* 2010;3:378-82.
9. Sikka SC, Gogu SR, Agrawal KC. Effect of zidovudine (AZT) on reproductive and hematopoietic systems in the male rat. *Biochem Pharmacol* 1991;42:1293-7.
10. Clayton A. HIV and antiretroviral therapy may affect fertility. The AIDS Beacon, 2011. Available from: <http://www.aidsbeacon.com/news/2011/07/14hiv-aids-and-antiretroviral-therapy-may-affect-fertility/>. [Last accessed on 2013 Sep 1].
11. Shevchuk MM, Pigato JB, Khalife G, Armenakas NA, Fracchia JA. Changing testicular histology in AIDS: Its implication for sexual transmission of HIV. *Urology* 1999;53:203-8.
12. Azu OO. The male genital tract in the era of highly active antiretroviral therapy (HAART): Implication for antioxidant therapy. *J AIDS Clin Res* 2012;3:169.
13. Oladokun A, Arulogun O, Oladokun R, Adenike Bello F, Morhassan-Bello IO, Bambgoye EA, *et al.* Attitude of infertile women to child adoption in Nigeria. *Niger J Physiol Sci* 2010;25:47-9.

**How to cite this article:** Chris-Ozoko LE, Charity AA, Ekundina VO. Histomorphological effect of zidovudine on the testes of adult male wistar rats (*rattus norvegicus*). *J Basic Clin Reprod Sci* 2013;2:73-6.

**Source of Support:** Nil, **Conflict of Interest:** None declared

## Announcement

### Android App



A free application to browse and search the journal's content is now available for Android based mobiles and devices. The application provides "Table of Contents" of the latest issues, which are stored on the device for future offline browsing. Internet connection is required to access the back issues and search facility. The application is compatible with all the versions of Android. The application can be downloaded from <https://market.android.com/details?id=comm.app.medknow>. For suggestions and comments do write back to us.