

Cotyledonoid Leiomyoma

Akanksha A Bothale, Kalpana A Bothale, Sadhana D Mahore, Anne R Wilkinson

Department of Pathology, NKP Salve Institute of Medical Sciences and Research Centre, Nagpur, India

ABSTRACT

Cotyledonoid leiomyoma is a very rare tumor among the ever expanding repertoire of growth variants described in benign uterine leiomyoma. We report a case of cotyledonoid leiomyoma in a 39-year-old (unmarried) women presented with lump in abdomen. On laparotomy, a large multinodular, tan colored, exophytic, fungating tumor mass adherent to the posterolateral aspect of fundus of the uterus and extending to broad ligament and pelvic cavity was seen. Microscopic examination revealed nodules of smooth muscle cells arranged in fascicles with perinodular hydropic change diagnosed as cotyledonoid leiomyoma. We report it because of rarity and potential misinterpretation as a leiomyosarcoma.

KEY WORDS: Africa, cotyledonoid leiomyoma, leiomyoma, sarcoma, sternberg tumor, uterus

INTRODUCTION

Cotyledonoid leiomyoma is a very rare variant of uterine smooth muscle tumor with an unusual and alarming gross appearance.^[1] Because of the striking resemblance to the placenta, the term cotyledonoid leiomyoma was coined for this peculiar benign variant of leiomyoma. This type of leiomyoma has previously been reported under the designation grape-like leiomyoma. It is also known as 'Sternberg tumor'.^[2]

Here we report a rare case of cotyledonoid leiomyoma.

CASE REPORT

A 39-year-old unmarried female presented with distension of abdomen during 2 years. There were no urinary complaints. Previous menstrual cycles were regular. Last menstrual period (LMP) was 1 month back. Palpation of abdomen revealed a mass size of 36 weeks pregnant uterus size, firm with restricted mobility. It appeared to be arising from fundus of the uterus. Blood tests showed no abnormalities. Computed tomography (CT) showed encapsulated (well-defined), lobulated tumor mass measuring 20:20:28 cm in anteroposterior, craniocaudal,

and transverse diameter, respectively. There were few cystic and necrotic areas. Increased vascularity was also noted. Ultrasonography (USG) showed huge degenerated fibroid, extending into pelvic cavity and broad ligament. Considering the CT findings, clinical diagnosis was sarcoma.

Laparotomy was performed. Intraoperatively there was a large multinodular, tan colored, exophytic, fungating tumor mass adherent posterolaterally to the fundus of the uterus and extending to broad ligament and pelvic cavity. Total abdominal hysterectomy with excision of tumor mass was done. There was no intrauterine component of tumor mass. The specimen was sent to the department of pathology for histopathological examination.

Pathological findings

Macroscopic: The uterus with cervix measured 9×5×3.5 cm. A large exophytic, firm, multinodular, grayish white to tan colored tumor mass, measuring 18 × 16 × 15 cm. Cut surface showed homogeneous, grayish white tumor mass with many irregular grape-like tan colored friable nodules attached to it in the periphery [Figure 1].

Microscopic examination of multinodular tumor mass revealed nodules of uniform smooth muscle cells, arranged in interlacing and whorling fascicles [Figure 2]. Many thick- and thin-walled blood vessels were prominent. The cellularity was increased in some areas. However, less than one mitosis per 10 high-power fields was seen. Perinodular hydropic degeneration was prominent. Nuclear

Access this article online

Quick Response Code



Website:
www.jbcrs.org

DOI:
10.4103/2278-960X.112599

Address for correspondence

Dr. Kalpana A Bothale,
28 Shastri lay out, Khamla, Nagpur - 440 025, Maharashtra, India.
E-mail: kalpana_bothale@yahoo.co.in

atypia or necrosis was not seen [Figure 3]. No intrauterine or dissecting component was evident. The endometrium showed proliferative phase and the cervix showed mild chronic cervicitis. A diagnosis of cellular leiomyoma was made. After reviewing the literature, and taking into consideration the gross appearance, a diagnosis of cotyledonoid leiomyoma was established.

DISCUSSION

Uterine smooth muscle tumors are known to exhibit a wide variety of growth patterns. One unusual variant is the cotyledonoid leiomyoma of the uterus or 'Sternberg tumor' first described by Roth *et al.*^[3-5] A variety of unusual patterns can occur in uterine leiomyoma, parasitic leiomyoma, intravascular leiomyomatosis, dissecting leiomyoma, leiomyoma with perinodular hydropic degeneration.^[2] No malignant behavior or recurrence has been described in these lesions with the longest follow-up period amounting to 41 years.^[3]

The tumor grossly resembles placenta. The median age of patients at presentation is 40 years (23-65 years). Because of lack of familiarity with the alarming fungating appearance of cotyledonoid leiomyoma, the large size of the tumor and the apparent widespread infiltrative growth with extension into the pelvic cavity and broad ligament and even into the retroperitoneal space, grossly mimics malignancy.^[5]

Gurbuz *et al.*, described a case of cotyledonoid leiomyoma which had no intrauterine portion, but had extrauterine extensions. The bizarre and unusual shape was in favor of malignancy, the frozen section examination revealed a benign histology. Although the cotyledonoid leiomyoma is a benign entity, it may suggest a malignant disease owing to its unusual sarcomatoid appearance and its rarity.^[6]

Microscopic examination reveals nodules of interlacing fascicles of uniform smooth muscle cells with no atypia or necrosis. Perinodular hydropic change is prominent.

In the reviewed literature, most common presenting symptoms were abnormal bleeding and pelvic mass. The tumor can vary from 10 to 25 cm. Microscopically, the tumor shows fascicles of uniform smooth muscle cells with no atypia, mitotic activity, or necrosis. The nodules of smooth muscle fascicles are separated by marked hydropic change and highly vascular stroma. It is believed that the poor mechanical support in the exophytic part of the tumor may lead to breakdown of hydropic stroma, exposing the neoplastic smooth muscle nodules to produce exophytic nodules. These nodules along with the stromal blood vessels give the characteristic red-brown color to the tumor.^[7]

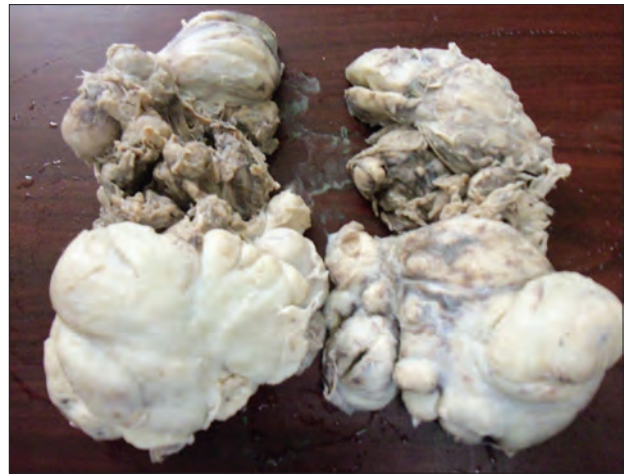

Figure 1: Gross photograph showing multinodular tan colored tumor mass with many nodules in the periphery and dilated blood vessels

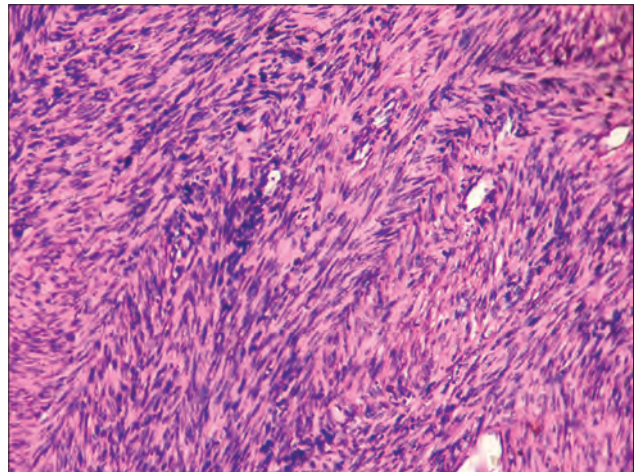


Figure 2: Photomicrograph showing interlacing and intersecting bundles of smooth muscle cells (H and E, x100)

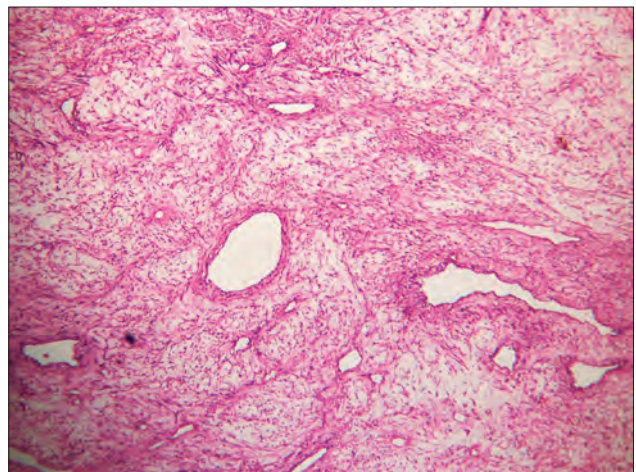


Figure 3: Hydropic change in the tumor mass with thick- and thin-walled blood vessels (H and E, x100)

Awareness of obstetricians and gynecologist regarding this entity will prevent unnecessary interventions or

inappropriate treatment. Intraoperative frozen section is a mandatory and helpful procedure to avoid overtreatment of such cases.

REFERENCES

1. Saeed AS, Hanaa B, Faisal AS, Najla AM. Cotyledonoid dissecting leiomyoma of the uterus: A case report of a benign uterine tumor with sarcoma-like gross appearance and review of literature. *Int J Gynecol Pathol* 2006;25:262-7.
2. Cheuk W, Chan JK, Liu JY. Cotyledonoid leiomyoma: A benign uterine tumor with alarming gross appearance. *Arch Pathol Lab Med* 2002;126:210-3.
3. Roth LM, Reed RJ, Sternberg WH. Cotyledonoid dissecting leiomyoma of the uterus: The tumor. *Am J Surg Pathol* 1996;20:1455-61.
4. Weissferdt A, Maheshwari MB, Downey GP, Rollason TP, Ganesan R. Cotyledonoid dissecting leiomyoma of the uterus: A case report. *Diagn Pathol* 2007;2:18.
5. Aggarwal S, Arora VK. An unusual variant of leiomyoma masquerading preoperatively as sarcoma. *Indian J Cancer* 2011;48:120-1.
6. Gurbuz A, Karateke A, Kabaca C, Arik H, Bilgic R. A case of cotyledonoid leiomyoma and review of the literature. *Int J Gynecol Cancer* 2005;15:1218-21.
7. Maimoon SA, Wilkinson AR, Mahore SD, Bothale KA, Patrikar AD. Cotyledonoid leiomyoma of the uterus. *Indian J Pathol Microbiol* 2006;49:289-91.

How to cite this article: Bothale AA, Bothale KA, Mahore SD, Wilkinson AR. Cotyledonoid leiomyoma. *J Basic Clin Reprod Sci* 2013;2:63-5.
Source of Support: Nil, **Conflict of Interest:** None declared

Announcement

iPhone App



Download
**iPhone, iPad
application**

FREE

A free application to browse and search the journal's content is now available for iPhone/iPad. The application provides "Table of Contents" of the latest issues, which are stored on the device for future offline browsing. Internet connection is required to access the back issues and search facility. The application is Compatible with iPhone, iPod touch, and iPad and Requires iOS 3.1 or later. The application can be downloaded from <http://itunes.apple.com/us/app/medknow-journals/id458064375?ls=1&mt=8>. For suggestions and comments do write back to us.