

Primary Ovarian Leiomyoma: An Uncommon Entity - Case Report and a Brief Review of Literature

Amitabh Jena, Rashmi Patnayak¹, Bodagala Vijaylaxmi², Amancharla Yadagiri Lakshmi²

Departments of Surgical Oncology, ¹Pathology and ²Radiology, Sri Venkateshwar Institute of Medical Sciences, Tirupati, Andhra Pradesh, India

ABSTRACT

Among all benign primary ovarian smooth muscle tumors, ovarian leiomyoma, is uncommon, accounting for 0.5-1% of all tumors. Most of these tumors are unilateral, small in size, and generally occur in premenopausal women. This paper presents a case report of primary ovarian leiomyoma, which is a rare entity, in a postmenopausal female with complaints of abdominal pain. The left ovarian mass was histopathologically and immunohistochemically diagnosed as ovarian leiomyoma. Unlike smooth muscle tumors of uterine origin, there are no definite histological criteria to categorize smooth muscle tumors of ovary. This is an additional case of ovarian leiomyoma with brief review of literature, especially highlighting differential diagnosis of ovarian spindle cell lesions.

KEY WORDS: Histopathology, immunohistochemistry, ovarian leiomyoma

INTRODUCTION

Among all benign primary ovarian smooth muscle tumors, ovarian leiomyoma, is uncommon, accounting for 0.5-1% of all tumors.^[1] Most of these tumors are unilateral, small in size, and generally occur in premenopausal women.^[2] The most likely theory is that they take their origin from the smooth muscle of the ovarian ligaments where they enter the ovary or from the smooth muscle of the ovarian blood vessels.^[1,3] We present a case of primary ovarian leiomyoma in a postmenopausal female.

CASE REPORT

A 47-year-old postmenopausal woman presented with a complaint of abdominal pain for past 1 month. There was no history of vomiting. Examination of the abdomen revealed presence of tenderness at the right iliac region. A hard mass was palpable on vaginal examination. Contrast computed tomography scan of the abdomen showed ovarian mass lesion [Figures 1 and 2]. The patient's CA-125 level was 17.4 IU/ml. A staging laparotomy was performed. There was

a large ovarian mass of the size 15 × 12 cm with an irregular surface. The right ovary was adherent to the appendix. Cecum, omentum, and small bowel were likewise adhered to the whole tubo-ovarian mass. A fundal fibroid of 5 × 4 cm was noted on the anterior surface. There were no pelvic or peritoneal deposits. The rest of the bowel and bladder appeared to be normal; minimal ascitic fluid was present. Total abdominal hysterectomy with bilateral salpingo-oophorectomy, adhesiolysis, and appendectomy was done.

On gross examination, the left ovarian mass was measuring 16 × 12 × 6 cm, cut section of which revealed compressed normal ovarian architecture replaced by a solid/cystic lesional mass of 15 × 12 cm. Microscopically, it showed rim of normal ovarian stroma along with a lesional component comprising of criss-cross and whorly spindle cell fasciculi with minimal pleomorphism. The spindle cells had blunt-ended nuclei and moderate amount of eosinophilic cytoplasm [Figure 3]. There were extensive areas of edema and hyaline degeneration. Mitotic activity was sparse, 0-1/10 high-power field. Necrosis was not observed. Based on these features, the tumor was diagnosed as benign ovarian leiomyoma. Immunohistochemically, the tumor showed intense positivity for smooth muscle actin and positivity for desmin [Figure 4]. The final histopathological diagnosis was ovarian leiomyoma. Unlike uterine smooth muscle tumors,

Access this article online

Quick Response Code



Website:

www.jbcrcs.org

DOI:

10.4103/2278-960X.112596

Address for correspondence

Dr. Amitabh Jena,
Department of Surgical Oncology, Sri Venkateshwar Institute of
Medical Sciences, Tirupati, Andhra Pradesh, India.
E-mail: dramitabh2004@yahoo.co.in

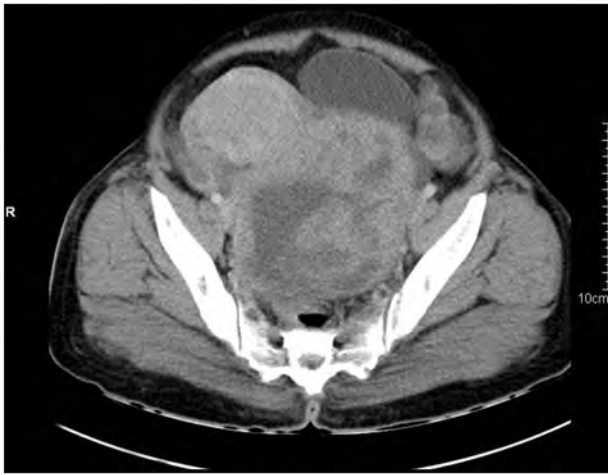

Figure 1: Contrast CT axial image showing heterogeneous enhancement of pelvic mass

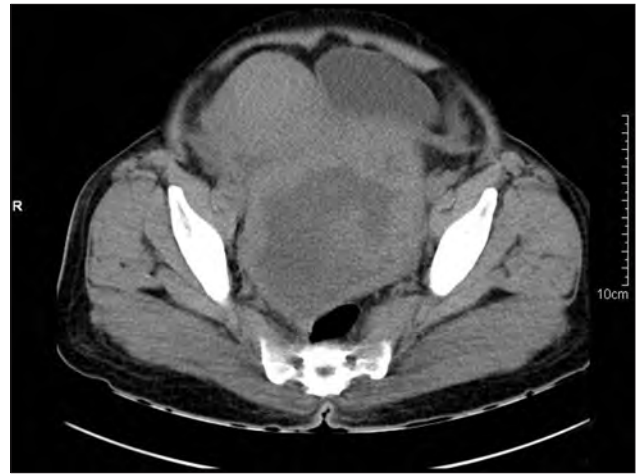


Figure 2: Plain CT axial image showing mixed density lesion in the pelvis displacing the uterus and bladder anteriorly and rectum posteriorly, suggesting ovarian origin

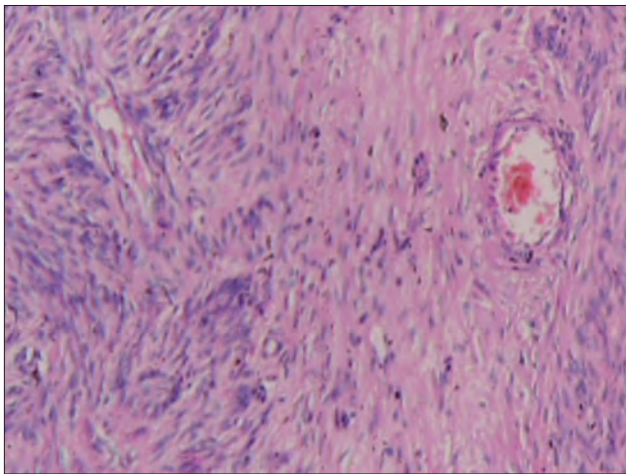


Figure 3: Microscopy of tumor showing spindle cells with blunt-ended nuclei and moderate amount of eosinophilic cytoplasm (H and E, x20)

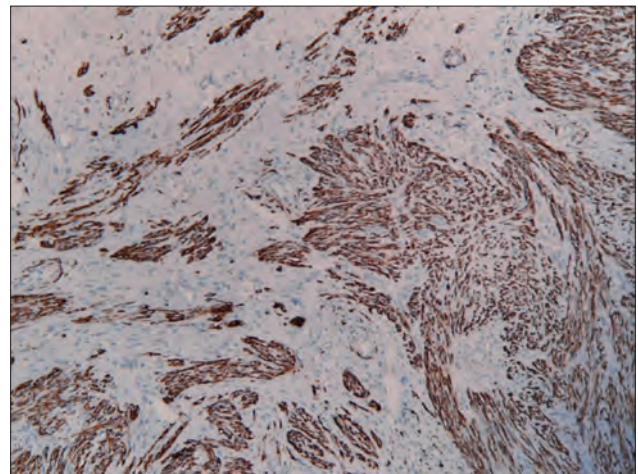


Figure 4: Tumor cells showing positivity for smooth muscle actin (IHC, x40)

there are no definite criteria to evaluate ovarian ones. Since the present tumor was cytologically bland with minimal mitotic activity and without necrosis, we preferred to label it as ovarian leiomyoma. In addition, the uterus revealed small intramural leiomyomas.

DISCUSSION

This is a case of ovarian leiomyoma in a postmenopausal woman who presented with a complaint of abdominal pain. Most ovarian leiomyoma described in literature are asymptomatic and were discovered incidentally.^[1,4] In symptomatic cases, clinical presentations are variable like abdominal pain, a palpable mass, hydronephrosis, elevated CA-125, hydrothorax, and ascites.^[1,2,5,6] Our patient had only complaint of abdominal pain. The age of presentation of ovarian leiomyoma varies between 20 and 65 years and postmenopausal cases account for approximately 16%.^[4]

Most ovarian leiomyoma are usually unilateral and small in size, and mostly with a diameter of <3 cm.^[4] In the present case, the ovarian leiomyoma was large in size. The uterus also revealed the presence of intramural leiomyomas. Similar cases of simultaneous occurrence of both ovarian and uterine leiomyomas have been described in literature.^[3,7]

Primary ovarian leiomyoma should also be distinguished from tumors arising from the broad ligament and extending into the hilum of ovary or wandering leiomyoma.^[3,4] The present tumor showed a rim of normal compressed ovarian tissue, thereby establishing the primary nature of the lesion, the smooth muscle origin of which was noted both histopathologically and immunohistochemically.

The differential diagnoses for ovarian leiomyoma include other spindle cell lesions like ovarian fibroma/thecoma, cellular fibroma/thecoma, and sclerosing stromal tumor. Immunohistochemically desmin shows diffuse positivity

in leiomyoma. However, in fibromatous tumors, it is typically negative or only focally positive. Smooth muscle actin is often positive in both leiomyoma and fibromatous tumors.^[1,8] Cellular thecoma does not express smooth muscle actin and instead expresses α -inhibin and calretinin.^[1,8,9]

Leiomyosarcoma, spindle cell carcinoma, and metastatic gastrointestinal stromal tumors also should be excluded in case of large tumors.^[4,7,10] Lerwill *et al.*, described smooth muscle tumors of ovary exhibiting the same varied histological spectrum as their uterine counterparts. However, unlike the case with uterine leiomyomas, the histological features of malignancy for ovarian smooth muscle tumors have not been well defined.^[7,9]

Usually ovarian leiomyoma have a benign course. Complete surgical resection is the preferred treatment. Our patient is doing well 2.5 years after the surgery.

Ovarian leiomyoma is a very rare tumor of unknown histogenesis. It should be considered in the differential diagnosis of ovarian spindle cell tumors. Appropriate immunohistochemical analysis helps in correct diagnosis. This is an additional case of ovarian leiomyoma in a postmenopausal woman.

ACKNOWLEDGMENTS

The authors wish to thank Dr. Suresh and senior technicians Mrs. Ushanandini and Mr. Ramana for their help.

REFERENCES

1. Tomas D, Lenicek T, Tucker N, Puljiz Z, Ledinsky M, Kruslin B. Primary ovarian leiomyoma associated with endometriotic cyst presenting with symptoms of acute appendicitis: A case report. *Diagn Pathol* 2009;4:25.
2. Wei C, Lilic N, Shorter N, Garrow E. Primary ovarian leiomyoma: A rare cause of ovarian tumor in adolescence. *J Pediatr Adolesc Gynecol* 2008;21:33-6.
3. Tsalacopoulos G, Tiltman AJ. Leiomyoma of the ovary: A report of 3 cases. *S Afr Med J* 1991;11:574-6.
4. Ramalakshmi Pullela VB, Das S, Chunduru B, Dua S. A case of ovarian leiomyoma with cystic degeneration. *Indian J Pathol Microbiol* 2009;52:592-4.
5. Khaffaf N, Khaffaf H, Wuketich S. Giant ovarian leiomyoma as a rare cause of acute abdomen and hydronephrosis. *Obstet Gynecol* 1996;87:872-3.
6. Nicoll JJ, Cox PJ. Leiomyoma of the ovary with ascites and hydrothorax. *Am J Obstet Gynecol* 1989;161:177-8.
7. Lerwill MF, Sung R, Oliva E, Prat J, Young RH. Smooth muscle tumors of the ovary: A clinicopathologic study of 54 cases emphasizing prognostic criteria, histologic variants, and differential diagnosis. *Am J Surg Pathol* 2004;28:1436-51.
8. Deavers MT, Malpica A, Liu J, Broaddus R, Silva EG. Ovarian sex cord-stromal tumors: An immunohistochemical study including a comparison of calretinin and inhibin. *Mod Pathol* 2003;16:584-90.
9. Murakami M, Uehara H, Nishimura M, Iwasa T, Ikawa H. A huge ovarian smooth muscle tumor: A case report. *J Med Invest* 2010;57:158-62.
10. Costa MJ, Morris R, DeRose PB, Cohen C. Histologic and immunohistochemical evidence for considering ovarian myxoma as a variant of the thecoma-fibroma group of ovarian stromal tumors. *Arch Pathol Lab Med* 1993;117:802-8.

How to cite this article: Jena A, Patnayak R, Vijaylaxmi B, Lakshmi AY. Primary ovarian leiomyoma: An uncommon entity - Case report and a brief review of literature. *J Basic Clin Reprod Sci* 2013;2:54-6.
Source of Support: Nil, **Conflict of Interest:** None declared