

A Rare Presentation of Aggressive Angiomyxoma as a Cervical Polyp

Kalpna A Bothale, Sadhana D Mahore, Archana M Joshi

Department of Pathology, NKP SIMS, Wanadongri, Nagpur, Maharashtra, India

ABSTRACT

A rare case of aggressive angiomyxoma (AAM) is reported here for its unusual presentation as a cervical polyp, in a 45-year-old woman. It is a soft tissue tumor. Preoperative diagnosis was uterine cervical polyp. Surgical excision was done. Histopathology examination revealed vascular, poorly circumscribed tumor mass composed of spindle cells embedded in myxoid stroma. In the reviewed literature, a single case of AAM mimicking cervical polyp has been reported. Our case may be the second rare case of AAM presenting as a cervical polyp.

KEY WORDS: Aggressive angiomyxoma, angiomyofibroblastoma, cervical polyp, superficial angiomyxoma

INTRODUCTION

Aggressive angiomyxoma (AAM) was first described in 1983 by Steeper and Rosai.^[1] This mesenchymal tumor arises from connective tissue of lower pelvis or perineum and has a locally aggressive course.^[2] The neoplasm predominantly affects reproductive age females with peak incidence during the third decade of life. The female to male ratio is 6:1. In women, vulvar region is the most common site of involvement.^[3]

CASE REPORT

A 45-year-old female presented to Gynecology Out-patient-Department with complaints of something coming out of vagina since 2 months and yellowish discharge from the vagina since 15 days. Her menstrual cycles were regular. There was no pallor and icterus.

Systemic examination

P/A – Soft, nontender, no organomegaly was present. Per speculum examination showed 6 × 6 cm, polypoid, pedunculated, nontender mass arising from the posterior lip of cervix. Vaginal examination showed normal sized uterus. Hemogram was within normal limits. Patient was negative for human immunodeficiency virus (HIV) and hepatitis B surface antigen (HBsAg). Considering the clinical diagnosis

of cervical polyp, excision was performed. Tumor mass was sent to pathology department for histopathological examination.

Gross pathology

On gross examination, the mass was polypoid, grayish-white, and soft to firm, measuring 6.5 × 5.5 × 4 cm [Figure 1]. The cut surface was slimy, gelatinous, and mostly solid with some cystic areas.

Microscopy

Sections revealed poorly circumscribed tumor mass, partly covered by ectocervical stratified squamous epithelium. The tumor mass was composed of spindle and stellate shaped cells with ill-defined cytoplasmic borders, numerous, variable sized thick muscular and thin walled blood vessels, embedded in the abundant myxoid stroma [Figures 2 and 3]. Occasional endocervical gland was also present, in the tumor mass. Cellular atypia was not seen. No cellular pleomorphism, anisonucleosis, increased mitotic activity, or necrosis were seen. No lipoblasts or nerve sheath elements were present. Histological diagnosis of AAM of cervix was given.

DISCUSSION

AAM is a slowly growing myxoid neoplasm that occurs chiefly in the genital, perineal, and pelvic regions of adult women. The neoplasm predominantly affects reproductive

Access this article online

Quick Response Code



Website:
www.jbcrs.org

DOI:
10.4103/2278-960X.104301

Address for correspondence

Dr. Kalpana A Bothale,
Department of Pathology, NKP SIMS, Wanadongri,
28, Shastri Layout, Khamla, Nagpur, Maharashtra, India.
E-mail: kalpana_bothale@yahoo.co.in



Figure 1: Gross specimen showing polypoid, pedunculated, glistening, grayish-white tumor mass

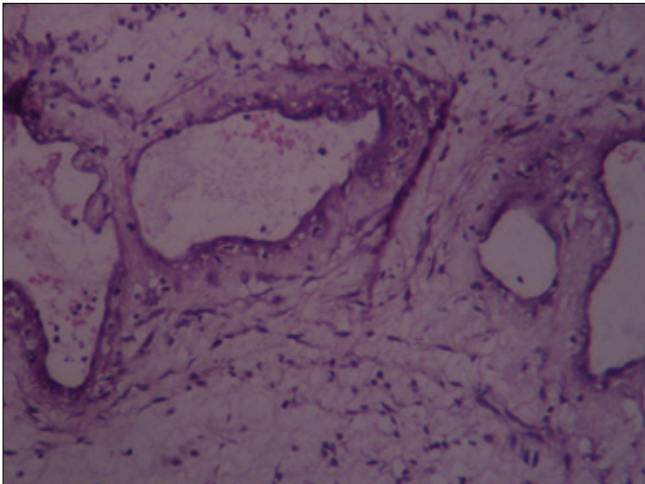


Figure 2: Photomicrograph showing blood vessels of variable caliber, in a myxoid stroma (H and E, $\times 100$)

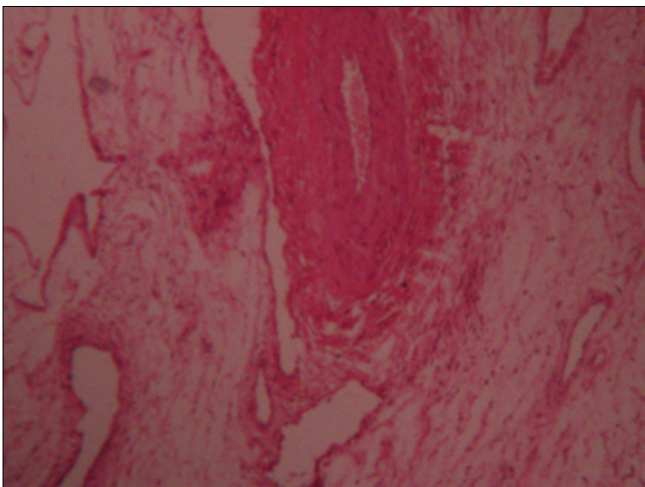


Figure 3: Photomicrograph showing thick and thin walled blood vessels, in a myxoid stroma (H and E, $\times 100$)

age females with peak incidence during the third decade of life. The female to male ratio is 6:1. In women vulvar region is the most common site of involvement.^[3] In the reviewed literature, a rare case of AAM mimicking cervical polyp has been reported by Paplomata *et al.*^[4] Our case may be the second such rare case of AAM presenting as a cervical polyp. Our patient was a 45-year-old female. Size of the tumor was more than 6 cm in diameter. The tumor presented as slowly growing, painless, polypoid, pedunculated mass. Microscopic examination showed poorly circumscribed tumor mass composed of variable sized thick and thin walled blood vessels, abundant myxoid stroma, and uniform bland spindle and stellate cells. Considering all these findings, histopathological diagnosis of aggressive angiomyxoma of cervix was given.

AAM must be distinguished from the more common benign and malignant myxoid tumors including myxoma, myxoid liposarcoma, myxoid neurofibroma, myxoid leiomyoma, leiomyosarcoma, myxoid liposarcoma, myxoid malignant fibrous histiocytoma, and botryoides rhabdomyosarcoma. AAM may also be clinically misdiagnosed as polyps, myxoma, lipoma, and Bartholin's cyst of vagina. The diagnosis of angiomyxoma may be difficult to establish. The distinctively striking vascular component in AAM helps to rule out the above mentioned neoplasm as differential.^[5]

In our tumor, histologically presence of striking vascular component and absence of nests of small basophilic cells (stromal cells) as well as absence of smooth muscle bundles helped to rule out myxoid variant of stromal tumor and myxoid leiomyoma, respectively.

In our case, considering the location of lesion, two close differential diagnoses were superficial angiomyxoma and angiomyofibroblastoma of cervix, which were ruled out histologically. Superficial angiomyxomas arise most often in the head and neck region and occasionally in the vulvovaginal region. They are slowly growing and circumscribed nodules. They are usually less than 3-4 cm in diameter. Histologically multilobulated, poorly delimited myxoid mass composed of plump spindle cells, numerous thin walled blood vessels, and inflammatory cells. Thick walled blood vessels are not seen in superficial angiomyxoma. These tumors have potential for local nondestructive recurrence in approximately 30% cases.^[6]

Angiomyofibroblastomas are well circumscribed, round, ovoid, or lobulated, usually less than 3 cm in diameter. Majority of them measure 2-8 cm. The cut surface is gray-pink to yellowish-brown to tan. There are hyper and hypocellular areas. Perivascular hypercellularity is present. Epithelioid plump spindle cells, multinucleate cells, and many thin walled blood vessels are present.

Recurrence is rare.^[3,6] Babala *et al.* reported a case of angiofibrosarcoma of the cervix uteri. Recognition of this entity is important to avoid misdiagnosis of the other angiofibrosarcomatous neoplasms.^[7]

Van Roggen *et al.* reported a clinicopathological and immunohistochemical study of 11 cases of AAM. All cases arising in females were positive for desmin, while three of the six cases arising in males were negative for desmin. Strong diffuse positivity for CDK4 was observed in all six cases. Six of eleven cases were positive for alpha smooth muscle antigen. Five of eleven were CD34 positive.^[8] Skalova *et al.* described a rare case of AAM presenting as an endometrial uterine polyp. This was the first case of AAM within the uterine cavity.^[9] Complete surgical excision is the gold standard for AAM because of its tendency to recur locally. The recurrence rate varies from 36% to 70%. Surgery causes significant morbidity due to its frequent occurrence in lower pelvis and perineum with proximity to genitourinary and anorectal structures. Most surgeons aim at complete resection (wide excision with tumor free margin), incomplete or partial resection is acceptable when high operative morbidity is anticipated and fertility is an issue. Treatment options include use of hormonal manipulation such as tamoxifen, raloxifen or GnRH analogs, radiotherapy, and arterial embolization.^[4,10]

It is typically a benign, nonmetastatic neoplasm. In two cases, however, multiple metastasis have been reported.^[11,12] Hence, long-term follow-up of patient is necessary. Our patient is followed up for 6 months after surgery. There is no evidence of recurrence till date.

REFERENCES

1. Steeper TA, Rosai J. Aggressive angiofibrosarcoma of female pelvis and perineum. Report of nine cases of a distinct type of gynecologic soft tissue neoplasm. *Am J Surg Pathol* 1983;7:463-75.
2. Behrnwala KA, Thomas JM. Aggressive angiofibrosarcoma: A distinct clinical entity. *Eur J Surg Oncol* 2003;29:559-63.
3. Abdul-Karim KW, Chang AE, Fletcher JA, Folpe AL, Geisinger KR, Gown AM, *et al.* Benign soft tissue tumors and pseudotumors of miscellaneous type. In: Weiss SW, Goldblum JR, editors. *Enzinger and Weiss's Soft tissue tumors*, 4th ed. St Louis: Mosby; 2001. p. 1419-81.
4. Paplomata E, Fotas A, Balaxis D, Filindris T, Charalambous S, Rombis V. Aggressive angiofibrosarcoma mimicking cervical polyp. *Pelviparoneology* 2010;29:30-1.
5. Akbulut M, Demircan NC, Colakoglu N, Duzcan E. Aggressive angiofibrosarcoma of the vulva: A case report and review of literature. *Aegean Pathol J* 2006;3:1-4.
6. Fletcher CD. Soft tissue tumors. In: Fletcher CD, editor. *Diagnostic Histopathology of tumors*. 3rd ed. Philadelphia: Churchill Livingstone, Elsevier; 2007. p. 1527-92.
7. Babala P, Biro C, Klacko M, Miklos P, Ondrus D. Angiofibrosarcoma of the cervix uteri: A case report. *Klin Onkol* 2011;24:133-6.
8. van Roggen JF, van Unnik JA, Briaire-de Bruijn IH, Hogendoorn PC. Aggressive angiofibrosarcoma: A clinicopathological and immunohistochemical study of 11 cases with long-term follow-up. *Virchows Arch* 2005;446:157-63.
9. Skalova A, Zamecnik M, Michal M, Opatrny V. Aggressive angiofibrosarcoma presenting as polyp of uterine cavity. *Pathol Res Pract* 2000;196:719-25.
10. Rudra S, Banerji RN, Mani NS. Case report – aggressive angiofibrosarcoma. *MJAFI* 2007;63:386-7.
11. Siassi RM, Papadopoulos T, Matzel KE. Metastasizing aggressive angiofibrosarcoma. *N Eng J Med* 1999;341:1772.
12. Blandamura S, Cruz J, Faure Vergara L, Machad Puerto I, Ninfo V. Aggressive angiofibrosarcoma: A second case of metastasis with patient's death. *Hum Pathol* 2003;34:1072-4.

How to cite this article: Bothale KA, Mahore SD, Joshi AM. A rare presentation of aggressive Angiofibrosarcoma as a cervical Polyp. *J Basic Clin Reprod Sci* 2012;1:65-7.

Source of Support: Nil, **Conflict of Interest:** None declared

Announcement

iPhone App



Download
iPhone, iPad
application



A free application to browse and search the journal's content is now available for iPhone/iPad. The application provides "Table of Contents" of the latest issues, which are stored on the device for future offline browsing. Internet connection is required to access the back issues and search facility. The application is Compatible with iPhone, iPod touch, and iPad and Requires iOS 3.1 or later. The application can be downloaded from <http://itunes.apple.com/us/app/medknow-journals/id458064375?ls=1&mt=8>. For suggestions and comments do write back to us.