

Abdominal Pregnancy in Usmanu Dan-Fodiyo University Teaching Hospital, Sokoto: A 10-year Review

Daniel Nnadi, Emmanuel Nwobodo, Bisallah Ekele

Department of Obstetrics and Gynecology, Usmanu Dan-fodiyo University Teaching Hospital, Sokoto, Nigeria

ABSTRACT

Background: Abdominal pregnancy, a rare condition with high maternal mortality (up to 50%), and even higher perinatal mortality (40 – 95%), is often associated with diagnostic difficulties. **Objectives:** To determine the mode of presentation and management of abdominal pregnancy, from cases in the Usmanu Dan-Fodiyo University Teaching Hospital (UDUTH), Sokoto. **Materials and Methods:** A retrospective review of the case records of all abdominal pregnancies managed in UDUTH, Sokoto, between January 2000 and December 2010. **Results:** During the 10-year study period, there were eight cases of abdominal pregnancies, 285 extrauterine pregnancies, and 25,506 total deliveries. All the patients were not booked for antenatal care and their ages ranged between 20 and 39 years (mean=28.1±3.4 years). The majority (88%) were grand multipara. The main presenting symptoms were persistent abdominal pain, vaginal bleeding, and prolonged pregnancy. Seven cases (87.5%) were diagnosed accurately by an ultrasound scan. There were seven perinatal deaths (87.5%) and one live birth. There was one maternal death (12.5%), which occurred in the patient whose placenta was left *in-situ*. **Conclusion:** Presence of persistent lower abdominal pain, vaginal bleeding, and prolonged pregnancy should raise the suspicion of abdominal pregnancy. Removal of the placenta, where feasible, improves the outcome of maternal health.

KEY WORDS: Ectopic pregnancy, Africa, diagnostic difficulties, maternal mortality

INTRODUCTION

Abdominal pregnancy is one in which the conceptus implants in the abdominal cavity.^[1] It is a rare variety of ectopic pregnancy. It is a potentially life-threatening condition, especially in developing countries, where the diagnosis may be delayed. The incidence is a reflection of the degree of pelvic inflammatory disease and ectopic pregnancy in particular communities. The highest incidence in the world is in the South African Bantu tribes, where it is stated that 2.2% of the ectopic pregnancies are of the abdominal variety.^[2] In Papua New Guinea, it has an incidence of one abdominal pregnancy per 62 cases of ectopic pregnancies, giving a rate of 1.6%,^[2] whereas, in the United States of America, an incidence of 1.09 per 10,000 births^[3] or 9.2 abdominal pregnancies per 1000 ectopic gestations have been recorded. It accounts for 1 – 4% of all ectopic pregnancies.^[4] The incidence of abdominal

pregnancy appears to be increasing in both developed and developing countries.^[4] In the former, an increase in the use of assisted reproductive technology, with embryo transfer, has been associated with increasing numbers of heterotopic pregnancies.^[3,4]

Maternal mortality is caused by severe intra-abdominal hemorrhage as well as infection. In the USA, Atrash *et al.*, reported that the risk of dying from an abdominal pregnancy is eight times greater than the risk of dying from a tubal pregnancy, and 90 times greater than that from an intrauterine pregnancy.^[5]

Perinatal mortality associated with abdominal pregnancy is also very high, ranging between 40 and 95%.^[5] This is largely related to the friability and vascularity of the placental implantation site, with fetal growth retardation and fetal abnormalities, both being major problems.

The clinical presentation depends on the gestational age. In the first trimester, symptoms are similar to those of tubal pregnancy. In the second or third trimester, the diagnosis

Access this article online

Quick Response Code



Website:

www.jbcrs.org

DOI:

10.4103/2278-960X.104294

Address for correspondence

Dr. Daniel Nnadi,
Department of Obstetrics and Gynecology,
Usmanu Dan-fodiyo University Teaching Hospital, Sokoto, Nigeria.
E-mail: dc_nnadi@yahoo.uk.com

may be suspected because of abnormal fetal presentation, displaced uterine cervix, or easily palpable fetal parts. The key to the successful management of advanced abdominal pregnancy is early diagnosis, to avert massive placental hemorrhage secondary to placental disruption and separation. Suggestive clinical findings are recurrent lower abdominal pain, an unstable lie, and the detection of a separate mass from the amniotic sac containing the fetus. Evidence of poor fetal growth may also be present. On vaginal examination, the finding of a radically displaced anterior and uneffaced cervix should raise the suspicion of abdominal pregnancy.^[6]

The management of abdominal pregnancy depends on the stage at which it is diagnosed. If the condition is diagnosed before 28 weeks of gestation, it is strongly advised that an immediate laparotomy be performed.^[7] Procrastination is dangerous and undesirable because of the danger of placental hemorrhage^[8] and poor prognosis for the fetus.

If abdominal pregnancy with a structurally normal fetus is diagnosed after the 28 weeks of gestation, immediate laparotomy and surgical removal of the pregnancy is recommended.^[8,9] It is important to have at least six units of blood cross-matched, and to have in attendance an experienced obstetric surgeon and pediatrician.^[10] Some clinicians may be tempted to adopt an individualized approach, especially when the benefits to the fetus are weighed against the potential risk to the mother, such as, the sudden onset of life-threatening hemorrhage.

When an abdominal pregnancy is complicated by fetal demise, immediate delivery should be instituted, to minimize the risk of disseminated intravascular coagulopathy.^[11]

There is continuing controversy with regard to the management of the placenta. Removal of the placenta must be undertaken if it is safe, depending on the accessibility to the ligation of the maternal vessels supplying the placental bed.^[7] This reduces hospital stay and maternal morbidity.^[7] Whether the abdominal pregnancy is early or advanced, if the placenta is to be left *in-situ*, it is recommended that the umbilical cord be ligated as close to the placenta as possible.^[9] A drain site must be established down the placental bed.^[7,9] It has been reported that leaving the placenta *in-situ* does not increase the risk of subsequent paralytic ileus and intra-abdominal sepsis.^[7,8] However, these risks are lesser than the likelihood of severe hemorrhage associated with attempted placental removal. Ombelet *et al.*,^[7] in a large series of advanced abdominal pregnancies, recently reported that the placenta was completely removed in 58% of the cases and left *in-situ* in the remaining 42%. Where the placenta is left *in-situ*, it may continue functioning for a number of weeks, and

even as long as five-and-a-half years.^[8] Both serial β -hCG levels and magnetic resonance imaging (MRI) can be used to follow-up placental involution. Methotrexate may be used to hasten placental involution. Some complications that may arise when the placenta is left *in-situ* include, infection, abscess formation, intestinal obstruction, and wound dehiscence.^[8]

After an abdominal pregnancy, the prognosis for future fertility depends essentially on whether the fallopian tubes and ovaries are normal and conserved at the time of laparotomy.^[9,10]

MATERIALS AND METHODS

The Usmanu Dan-fodio University Teaching hospital (UDUTH) is a tertiary institution situated in the North-western region of Nigeria. It provides tertiary as well as secondary healthcare services for the Sokoto, Kebbi, Zamfara, and Niger states. It also receives referral from the Niger Republic, a neighboring country, where the hospital runs a residency training program in the various subspecialties. It has the highest patient load among the health institutions in the region.

The records of all cases of ectopic pregnancies at UDUTH, between 1 January 2000 and 31 December 2010, were extracted from the operating theater register. Of these cases, those that were diagnosed as abdominal pregnancy were isolated and their folders were retrieved from the central library. Relevant data were extracted from the folders using a proforma, which included the demographic and biosocial particulars of the patients, the clinical features, and the treatment offered. Some of these data included age, occupation, place of residence, tribe, educational status, parity, and the last menstrual period (LMP). Data on the total number of admissions and deliveries during the study period were also collated. The data were analyzed via SPSS Version 10.5 and the results were presented in simple percentages. Prolonged pregnancy was defined as that exceeding 42 weeks of gestation. Ethical approval to conduct the study was obtained from the UDUTH Ethical Committee.

RESULTS

During the study period, there were 25,506 deliveries and 285 of these were ectopic pregnancies. There were eight cases of abdominal pregnancies and 278 cases of tubal pregnancies. Abdominal pregnancy accounted for 2.8% of the ectopic pregnancies and had a frequency of 3.1 \ 10,000 deliveries. All the patients were not booked for antenatal care. The age and parity distribution are illustrated in Figures 1 and 2.

The patients' ages ranged between 20 and 39 years, with a mean of 28.1 ± 3.4 years. The parity ranged from 1 to 9. Most of the patients (88%), were grand multiparas. The maternal mortality was 12.5%.

All the patients were married women. The average gestational age at presentation was 33 weeks (50%) and the most common presenting symptoms were bleeding per vaginam (50%), lower abdominal pain (100%), prolonged pregnancy (37.5%), and weight loss (25%) as shown in the Table 1.

Seven cases (87.5%) were diagnosed accurately by ultrasound scan.

Implantation sites in two (25%) of the cases were at the ileocecal junction, omentum, and anterior abdominal wall, and also over a uterine defect, respectively. The other sites were the right iliac fossa in one (12.5%), and the site of placental attachment was not stated in one case.

All the seven babies were delivered as macerated stillbirths. One case of a live birth was seen in a 30-year-old primigravida, with 15 years of primary infertility. At laparotomy, a live male fetus was seen floating in the abdominal cavity. The baby was grossly normal and weighed 3.2 kg, with Apgar scores of 7 and 8, in the first and fifth minutes, respectively. The placenta was removed in seven of the eight cases. The intraoperative blood loss ranged between 800 and 1,200 ml, with an average of 870 ± 65 ml. Seven patients were transfused with two units each, whereas, one had three units. The only patient who had the placenta *in-situ* developed overwhelming sepsis and disseminated intravascular coagulation (DIC) postoperatively, and died on the third postoperative day from both complications. This

was the only maternal mortality encountered. The direct cause of death was hemorrhage.

DISCUSSION

Not much study has been conducted on the prevalence of abdominal pregnancy in Nigeria, although Adesukunmi in Ile-Ife and Ifenne in Zaria, have reported single cases of advanced abdominal pregnancy.^[7,8] The incidence of 1: 3200 recorded in this study is quite high when compared to the reports from other countries.^[2-5] It may be partly because it is an institutional-based study. The proportion of abdominal pregnancies (2.8%), with respect to all the ectopic pregnancies in this study, is also much higher than the review reports.

Most of the patients were within the age range of 20 – 39 years, a reflection of the age of 'active' reproduction. This is similar to the findings in other reports.^[5] Ectopic pregnancy is found to be more in women over 35 years of age.^[6]

All our cases were married women. The most common presenting symptoms in this and other studies were, lower abdominal pain (100% of cases)^[1-7] and bleeding per vaginam (50%).

The key to the successful management of abdominal pregnancy is early diagnosis, in order to avert complications.^[7] The ability to make the correct diagnosis depends on the level of skill of the medical care provider and a high index of suspicion in patients with recurrent abdominal pain during pregnancy. The lack of antenatal care seen in all the cases in this study may have contributed to the delayed diagnosis. In one case of advanced abdominal pregnancy reported from this center, the ultrasound diagnosis was aided by the balloon of a Foley catheter that was passed transcervically.^[12]

The absence of magnetic resonance imaging, which is an excellent modality to assess the definitive area of placental

Table 1: Presenting symptoms

	No.	%
Lower abdominal pain	8	100
Bleeding per vaginam	4	50
Post-term pregnancy	3	37.5
Weight loss	2	25

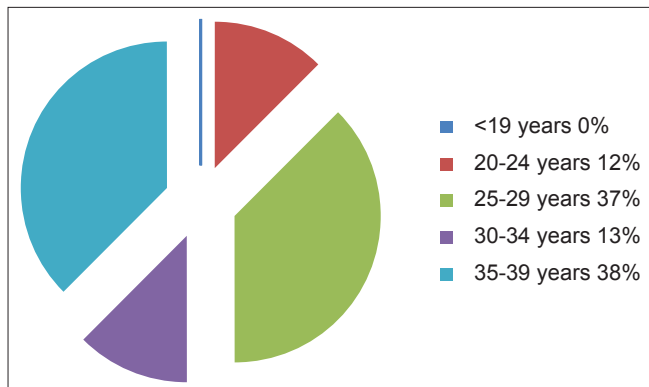


Figure 1: Age distribution of the patients

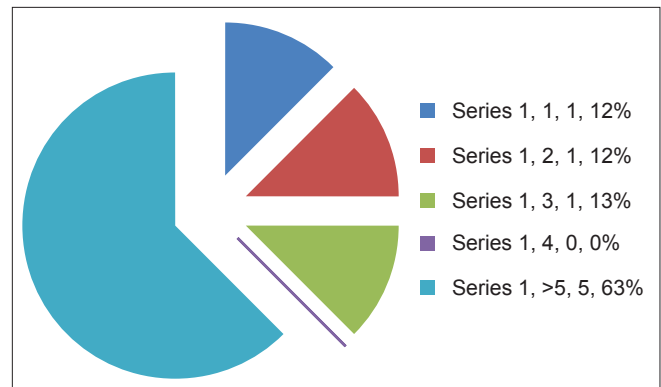


Figure 2: Parity distribution of the study population

implantation, may have also contributed to the delayed diagnosis.

In all cases, immediate laparotomy and excision of the gestational sac was performed as soon as the diagnosis was confirmed, to reduce the risk of disseminated intravascular coagulopathy.^[11] There was only one case where the fetus was alive, apparently because most of our cases present late, long after fetal demise.^[13] Sapuri in Papua New Guinea,^[2,6,14] Ifenne in Zaria,^[8] and Ludwig in Germany,^[15] have each reported successful fetal outcomes in cases of advanced abdominal pregnancy. In Benin City, Nigeria, a similar report of term abdominal pregnancy, with a live baby, has been reported.^[16] Similarly, in a 10-year review of abdominal pregnancy in the University College Hospital (UCH), Ibadan, there were two live births recorded.^[17]

The common sites of implantation in this study were, the ileocecal junction, anterior and posterior walls of the uterus, and the omentum and anterior abdominal wall. Other sites of placental attachment, such as the leaves of the broad ligament, the sigmoid colon, and pouch of Douglas, have been reported.^[11-15] The one maternal death recorded was due to DIC. In this patient, the placenta was left *in-situ*. Several reports have shown that maternal survival is better when the placenta is removed than when left *in-situ*.^[18] Maternal mortality in abdominal pregnancy is from severe hemorrhage as well as infection. In such situations, where the placental blood supply is extensive, Sapuri *et al.* has warned that it is too risky to attempt a removal.^[6] The umbilical cord must be ligated as close to the placenta as possible.^[18] Removal of the placenta should be undertaken if it is considered safe, depending on the accessibility of the ligation of the maternal vessels supplying the placenta.^[18] This reduces the hospital stay and maternal morbidity.^[18]

CONCLUSION

The incidence of abdominal pregnancy in our center (3.1 / 10,000 deliveries) is relatively high. The presence of a triad of persistent lower abdominal pain, vaginal bleeding, and prolonged pregnancy should raise the suspicion. Removal of the placenta, where feasible, improves the maternal outcome.

REFERENCES

1. Motazedin SH. Term asymptomatic abdominal pregnancy with good maternal and perinatal outcome. *Iran J Med Sci*2001;25:76-80.
2. Ombelet W, Vandermerwe JV, van Assche FA. Advanced extrauterine pregnancy: Description of 38 cases with literature survey. *Obstet Gynecol Surv* 1988;43:386-97.
3. Martin JN Jr, Sessums JK, Martin RW, Pryor JA, Morrison JC. Abdominal pregnancy: Current concepts of management. *Obstet Gynecol* 1988;71:549-57.
4. Crabtree KE, Collet B, Kilpatrick SJ. Puerperal presentation of a living abdominal pregnancy. *Obstet Gynecol* 1994;84:646-8.
5. Atrash HK, Friede A, Hogue CJ. Abdominal pregnancy in the United States: Frequency and maternal mortality. *Obstet Gynecol* 1987;69:333-7.
6. Sapuri M, Klufio C. A case of advanced viable extrauterine pregnancy. *P N G Med J* 1997;40:44-7.
7. Adesunkanmi AR, Fasubaa OB, Adeosun O, Orji CO. Undiagnosed abdominal pregnancy masquerading as faecal fistula in a simultaneous intra uterine and abdominal pregnancies—a case report. *West Afr J Med* 2000;19:156-7.
8. Ifenne DI, Shittu SO, Mandara MU. Advanced abdominal pregnancy with a live baby. *Trop J Obstet Gynaecol* 1999;16:63-5.
9. Ubels R. Advanced abdominal pregnancy: Diagnosis and management. *Trop Doct* 1989;19:77-80.
10. Eneli AG, Kuku SB. Advanced abdominal pregnancy. *Niger Med J* 1975;51:170-1.
11. Uguru VE, Shuaibu SD, Sagay AS. Conservative management of early abdominal pregnancy and elective delivery of a live baby at term. *Niger Postgraduate Med J* 1997;4:93-5.
12. Ekele BA, Ahmed Y, Nnadi D, Ishaku K. Abdominal pregnancy: Ultrasound diagnosis aided by the balloon of a Foley catheter. *Acta Obstet Gynecol Scand* 2005;84:701-2.
13. Isah AY, Ahmed Y, Nwobodo EI, Ekele BA. Abdominal pregnancy with a full term live fetus: Case report. *Ann Afr Med* 2008;7:198-9.
14. Dukut RK, Soemardi A, Rakun E. Obstructed bowel due to abdominal pregnancy. *J Indones Med Assoc*2002;3:407-12.
15. Ludwig M, Kaisi M, Bauer O, Diedrich K. The forgotten child—a case of heterotopic, intra-abdominal and intrauterine pregnancy carried to term. *Hum Reprod* 1999;14:1372-4.
16. Okonkwo CA, Ande AB. Term abdominal pregnancy mis-diagnosed as placenta praevia. *Sahel Med J* 2006;9:147-8.
17. Ayinde OA, Aimakhu CO, Adeyanju OA, Omigbodun AO. Abdominal pregnancy at the University College Hospital, Ibadan: A ten-year review. *Afr J Reprod Health* 2005;9:123-7.
18. Babić D, Colić G, Mrden D. [Complications after surgery for abdominal pregnancy due to a retained placenta]. *Jugosl Ginekol Opstet* 1983;23:93-4.

How to cite this article: Nnadi D, Nwobodo E, Ekele B. Abdominal pregnancy in Usmanu Dan-Fodiyo university teaching hospital, Sokoto: A 10-year review. *J Basic Clin Reprod Sci* 2012;1:34-7.

Source of Support: Nil, **Conflict of Interest:** None declared