

Management of Anesthesia in a Pregnant Patient with an Unmodified Congenital Heart Disease

Katayoun Haryalchi, Mandana Mansour Ghanaie¹, Neda Habibi Arejan², Leila Farhadytoli³

Departments of Anesthesia, ¹Gynecology, Reproductive Health Research Center, Guilan University of Medical Sciences, Guilan, ²Department of internal Medicine, Metabolic Disease Research Center, Qazvin University of Medical Science, Qazvin, ³Department of Microbiology, Cardiogenetics Research Center, Tehran University of Medical Science, Tehran, Iran

ABSTRACT

Congenital heart diseases (CHDs) affect approximately 0.8% of all the newborns with malformed structured heart or large vessels. Nowadays, due to the progress in medical methods and management, most women with CHD are expected to reach childbearing age. Noticeable improvement in anesthesia management is important for successful outcome and survival in pregnant patients with CHDs, even with the most complex disease. A multiparous patient, who had two components of cyanotic CHDs, which includes transposition of the great arteries (TGA) and single ventricle (atrioventricular connection) in childhood, got pregnant at the age of 39 years. She had a normal pregnancy course without any specific symptoms. She did not experience functional deterioration during her pregnancy. Termination of pregnancy was decided when intrauterine growth restriction (IUGR), was diagnosed by ultrasonography at 37 weeks, and a normal 1250-g baby was delivered by cesarean section. This case report, records the anesthetic care of the 39-year-old female who underwent cesarean section due to IUGR. General anesthesia was successfully administered, with precise attention to maintenance of systemic vascular resistance (to minimize shunting), better oxygenation, administration of pre procedural antibiotics, and judicious replacement of intravenous fluids via air-filtered tubing.

KEY WORDS: Africa, anesthesia, cesarean, congenital heart disease, pregnancy, transposition of the great arteries

INTRODUCTION

Population of adults with congenital heart disease (CHD) has increased over the years, due to improvement in pediatric cardiology, and improved surgical and anesthetic techniques.^[1-4] More than 1 million adults with CHD currently reside in the USA, approximately half of them are women of childbearing ages.^[5] Approximately 20% of these produce life-threatening symptoms, including; arrhythmia, syncope, myocardial infarction, and sudden death.^[6] The coincidence of these two rare congenital heart anomalies with pregnancy is very unique and presents a potential anesthetic risk. Additionally, management is quite complex and the anesthetist needs to make an individualized anesthetic plan.^[7] The effects of anesthetic drugs on the heart and shunt, fluid management, respiratory changes on shunts and how

to avoid pulmonary hypertension are important factors during cesarean section. In this report, we review the general anesthesia during cesarean section in a term pregnant patient with congenital heart disorder.

CASE REPORT

A 39-year-old female, Gravida 5 Para 4 Abortion 1 who weighed 70 kg, underwent cesarean operation due to intrauterine growth restriction (IUGR), detected by ultrasonography at 37 weeks gestation. All her previous pregnancies were normal. She was informed about her condition when she was examined for the first time during a medical examination of the first pregnancy.

She had a history of functional restrictions and dyspnea before pregnancy. She had taken medications that included: (i) Amiodarone 200 mg, twice a day; (ii) Digoxin 0.125 mg, five times a week; (iii) Enalapril 5 mg, every day; (iv) Ferrous sulfate 325 mg, every day; (v) Levothyroxine

Access this article online

Quick Response Code	Website: www.jbcrcs.org
	DOI: ***

Address for correspondence

Dr. Mandana Mansour Ghanaie,
Reproductive Health Research Center, Alzahra Hospital,
Guilan University of Medical Sciences, Namjo Street,
Rasht, Guilan, Iran.
E-mail: k_haryalchi@yahoo.com

12.5 µg/day; and (vi) Acetylsalicylic acid 81 mg/day. She was not regular to her physician follow-up, and was not taking her drugs regularly. She did not have any prior heart surgery such as Fontan surgery and balloon atrial septostomy. She also had no history of other congenital diseases.

At admission, she had clubbing of the fingers and cyanosis under nail beds. There was no respiratory distress, and lung sounds were clear. The auscultation of the precordium was remarkable with a loud holo-systolic murmur (grade V) that was heard in whole cardiac points.

There was no endocarditis, pulmonary infection upper respiratory tract (URT) infections. She had hyperglycemia, which was under control by diet during the pregnancy.

Preoperatively, she was reviewed by, the cardiologist, obstetrician, and the anesthesiologist, and a decision to perform cesarean section (at 37 weeks) under general anesthesia was taken. Hence, the patient was first admitted to the intensive care unit (ICU) to closely monitor heart rate and rhythm, arterial blood pressure (BP), oxygen saturation, and fluid balance during initial drug administration.

At admission, the vital signs were: Oxygen saturation was between 85% and 90%; BP between 138/85 and 140/95 mmHg; pulse rate between 80 and 87 bpm; respiratory rate (RR) between 16 and 19/min; and temperature 37°C. Preoperative electrocardiography (ECG) showed sinus rhythm and right axis deviation.

Laboratory findings included: Hemoglobin = 13.9, hematocrit = 44.9%, red blood cells (RBC) = 5.15/µl, total white blood cells count of (WBC) = 18500/µl, platelet count = 214,000/µl, BUN = 17.3, creatinine = 0.8 mg/dl, blood sugar 111 g/dl, sodium = 139 µmol/l, potassium = 5 Eq/l, calcium = 8.8 mg/dl, phosphate = 3.4 mg/dl, magnesium = 14 mg/dl, albumin = 3.3 g/dl, bilirubin direct = -0.2 mg/dl and indirect = -1.1 mg/dl, SGOT = 21 (IU/l), SGPT = 10 (IU/l), alkaline phosphatase = 238 (IU/l)

Preoperative echocardiography

Echocardiogram was done as it will help to assess ventricular function, atrioventricular valve function, and status of fenestration.^[6,8] In our case, this showed obvious single ventricle with good diastolic function, hypoplastic right ventricle, malposition of great arteries and pulmonary stenosis [Figures 1-3]. The patient was admitted for 10 days in the ICU. Packed cell (10 units) and fresh frozen plasma (10 units) were reserved. Preoperative prescriptions included: Aspirin as an anticoagulant (80 mg/daily), which was prescribed 7 days before the surgery, methyl dopa as

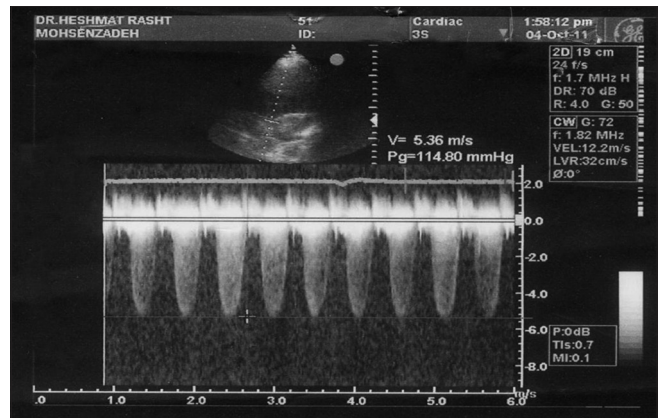


Figure 1: Chocardiography of the pregnant patient with uncorrected transposition of the great arteries and single ventricle with good diastolic function

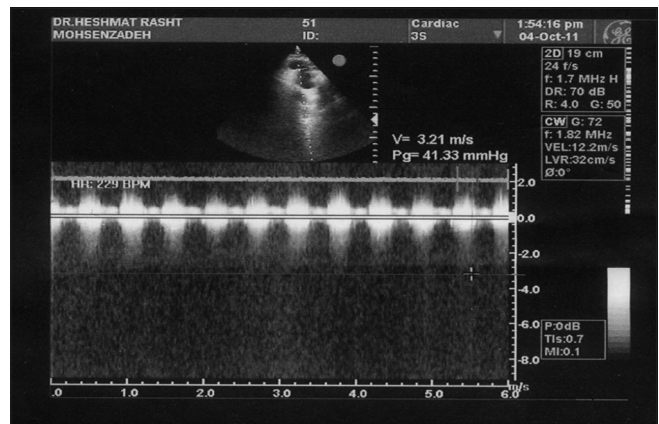


Figure 2: Chocardiography of the pregnant patient with uncorrected transposition of the great arteries and single ventricle with good diastolic function

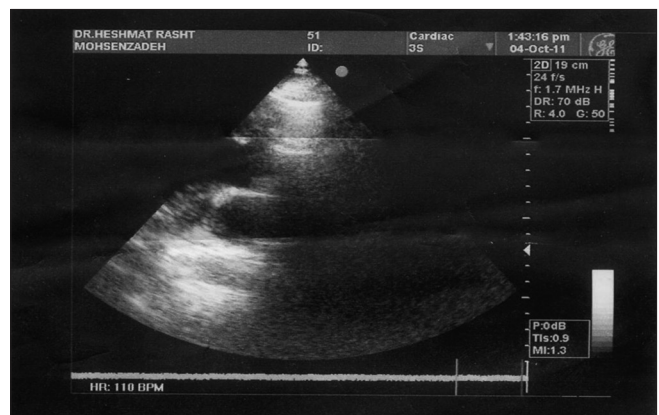


Figure 3: Chocardiography of the pregnant patient with uncorrected transposition of the great arteries and single ventricle with good diastolic function

an antihypertensive drug (250 mg/three times a day (tid)). After premedication with IV midazolam, a radial arterial catheter was placed under local anesthesia. Prophylactic antibiotics, ampicillin (2 g) and gentamicin (80 mg) was also administered by slow IV rate for an hour before the

surgery. This is to prevent infective endocarditis as well as post operative wound infection. In patients with ventricular dysfunction and reduced cardiac output, induction should be accomplished intravenously with drugs that have minimal myocardial depressant effects.^[6,8]

Intraoperatively, Anesthesia was thus induced by using oxygen (100%) 6 min before cesarean, sodium thiopental (5 mg/kg), and succinylcholine (1 mg/kg). Patient was intubated with 6.5 ID tube. Throughout the operation, general principles were performed to maintain adequate preload, sinus rhythm, and ventricular contractility to preserve low pulmonary vascular resistance (PVR), and to reduce after load. These were achieved by concentrations of smaller amounts of isoflurane, infusion of propofol and atracurium.

It was significant that there was no hypertensive response at the time of intubation. Anesthesia was maintained with a small concentration of isoflurane plus oxygen, and the patient was normo-ventilated. After 3 min, baby was delivered with Apgar score of 7 (1st min) and 8 (5th min). Fentanyl (1 µg/kg) was used as an opioid; atracurium (0.5 mg/kg) was used as a muscle relaxant, and propofol infusion was prescribed for better hypnotic effect and minimal hemodynamic changes. Intra-operative monitoring included: Pulse-oximetry, ECG, and DC shock player Low dose trinitroglycerin were infused to minimize fluctuations in BP. For more fluid restriction, 2 l Ringer Lactate was used throughout the surgery. Operation lasted for 40 min, and there were no adverse alterations in vital signs during the surgery. In the end, extubation was performed after suctioning, and postoperative analgesia was maintained with pethidine. The patient was transferred to the ICU and was discharged 1 week later in relative good condition. She was advised for further follow-up. Both mother and baby were stable at the time of discharge from hospital.

DISCUSSION

The term “single ventricle” is used to describe the situation in which complete mixing of pulmonary venous and systemic venous blood occurs at the arterial or ventricular level, and the ventricles then distribute output to both the systemic and pulmonary beds.^[9,10] Transposition of the great arteries (TGA), also referred to as complete transposition, is a congenital cardiac malformation characterized by atrioventricular concordance and ventriculoarterial (VA) discordance. The incidence is estimated at 1 in 3500–5000 live births.^[11]

Its onset and severity depends on anatomical and functional variants, which could influence the degree of mixing between two circulations.^[8,11,12] These two rare anomalies

during pregnancy portend grave danger to the mother and the fetus. Nowadays, due to progress in medical methods and management, most women with CHD are expected to reach childbearing age.^[9,10,13] As described earlier, an increasing in the CHD population, management of anesthesia in CHD's pregnant patient will become an important health care issue. The physiological changes accompanied with pregnancy will be an additional load for mothers with this problem.^[6]

Noticeable progress in anesthetic management is important for successful outcome and survival in pregnant patients with CHDs, even with the most complex diseases.^[1,2] Anesthetists may encounter such patients earlier than their due dates, because of the high incidence of premature labor and delivery, which has been observed in this population.^[6] The choice of anesthesia is a crucial issue during cesarean surgery in patients with CHD; therefore having a wide knowledge about etiology, pathophysiology and clinical presentation of CHD is critical for every anesthetist.

Management of anesthesia in TGA and single ventricle needs special considerations. Anesthetic preoperative management in patients with TGA and single ventricle has been described in literature,^[8,11,14] which also includes prophylaxis against infectious endocarditis.^[8,12]

For general anesthesia, recent illness should be addressed, especially respiratory tract infections, because changes in airway or PVR are detrimental, and may pose an unacceptable risk for elective surgery in those patients. Cardiac output will be decreased if respiratory complications (laryngospasm or bronchospasm) occur. In contrast, arterial oxygen saturation should be higher than 90% without fenestration, and higher than 80% with fenestration. It must be noticed that arterial oxygen saturation will not be 100%, because the coronary sinus typically is incorporated into the systemic side.^[6] Our patient's saturation was lower than 90% when she was admitted in the hospital.

Preload and after load were preserved by adequate hydration and liquid replacement. Not per oral (NPO) must be well coordinated to minimize the risk of dehydration, therefore it is important to avoid preoperative dehydration.^[6,8] Aggressive volume expansion is not advised in CHD patients. Fortunately the patient had a good diastolic function in echocardiography, so there was more choice for liquid consumption. Dopamine or vasoconstrictors are helpful in cases of volume depletion and shock.^[6,8] In our case, there was no volume deterioration. During the surgery, it is necessary to minimize PVR, maintain adequate ventilation, and reduce mean airway pressure. In positive ventilation, moderately elevated tidal volume (10-15 ml/kg), low rate and avoiding excessive positive end-expiratory pressure(PEEP)

should be considered too.^[6,8] In these cases end-diastolic ventricular pressure should be maintained in low range.^[6]

Therefore, maintaining sinus rhythm and contractility is important.^[6] Decrease in after load could improve contractility and diminish atrioventricular regurgitation.^[6,8] We tried to have the least amount of alteration in vital signs, and the main goals were achieved by stabilizing the rate pressure (which were produced by perfect hydration and analgesia). It is important to be aware of possible intraoperative bleeding. Bleeding can be caused by increased venous pressure; hence residual anticoagulants may play an important role. Anticoagulants should be stopped before elective surgeries.^[6,8] We were prepared for bleeding by reserving 10 units of packed cells, 10 units of fresh frozen plasma, and anticoagulants were administered for 7 days prior to surgery. The control of postoperative pain is also important splinting from pain could possibly increase PVR, however, hypoventilation due to overdose of pain medication could also increase that.^[1, 15] In our case, we had the time of deterioration in oxygen saturation, therefore, opioids were prescribed carefully with restriction dose; 1 µg/kg dose of fentanyl was prescribed.

In these patients, the separation of systemic and pulmonary circulation is important. Dose of IV anesthetics or the speed of injections should be decreased. The onset of effect in volatile anesthetics could be retarded; therefore, dehydration should be avoided. The risk of atrial dysrhythmias or conductive disturbances is indeed considerable.^[8,12]

In this case, we used general anesthesia since she was a CHD patient who was not taking medicine regularly and no prior cardiac surgery. Anesthesia was induced by using oxygen (100%) 6 min before cesarean, sodium thiopental (5 mg/kg), and succinylcholine (1 mg/kg). Patient was intubated with 6.5 ID tube. Throughout the operation, general principles were performed to maintain adequate preload, sinus rhythm, and ventricular contractility, to preserve low PVR and to reduce after load. These were achieved by concentrations of smaller amounts of isoflurane, infusion of propofol and atracurium.

Our goal was to maintain SVR and decrease PVR 15. Anesthesia was maintained with small concentrations of isoflurane plus oxygen, and the patient was normo-ventilated. After 3 min, the baby was pulled out with Apgar score of 7 (1st min) and 8 (5th min). Fentanyl (1 µg/kg) was used as an opioid; atracurium (0.5 mg/kg) was used as a muscle relaxant, and propofol infusion was prescribed for better hypnotic effect and minimal hemodynamic changes.

We successfully performed caesarean section under general anesthesia, in this case a CHD patient without

any previous cardiac surgery, despite its complexity. The patient was discharged after 1 week with a self-relative good condition.

CONCLUSION

CHD can complicate pregnancy; hence accurate pre anesthetic evaluation seems necessary, implying that a correct plan of anesthesia with adequate preparations, such as precise titration of drugs and maintaining hemodynamic stability, would lead to better outcomes and assembling a safe anesthesia procedure.

REFERENCES

- Harris IS. Management of pregnancy in patients with congenital heart disease. *Prog Cardiovasc Dis* 2011;53:305-11.
- Mohindra R, Beebe DS, Belani KG. Anesthetic management of patients with congenital heart disease presenting for non-cardiac surgery. *Ann Card Anaesth* 2002;5:15-24.
- Marelli AJ, Mackie AS, Ionescu-Iltu R, Rahme E, Pilote L. Congenital heart disease in the general population: Changing prevalence and age distribution. *Circulation* 2007;115:163-72.
- Cannesson M, Collange V, Lehot JJ. Anesthesia in adult patients with congenital heart disease. *Curr Opin Anaesthesiol* 2009;22:88-94.
- Fernandes SM, Arendt KW, Landzberg MJ, Economy KE, Khairy P. Pregnant women with congenital heart disease: Cardiac, anesthetic and obstetrical implications. *Expert Rev Cardiovasc Ther* 2010;8:439-48.
- Yuki K, Casta A, Uezono S. Anesthetic management of noncardiac surgery for patients with single ventricle physiology. *J Anesth* 2011;25:247-56.
- DiNardo JA. Grown-up congenital heart (GUCh) disease: An evolving global challenge. *Ann Card Anaesth* 2008;11:3-5.
- Nussmeier NA, Hauser MC, Sarwar MF, Grigor AM, Searles BE. Anesthesia for cardiac surgical procedures. In: Miller RD, editor. *Miller's Anesthesia*. 7th ed. Philadelphia: Churchill Livingstone; 2010. p. 1889-976.
- DiNardo JA. Physiology of single ventricle, birth and beyond. *Rev Mex Anest* 2010;33:275-7.
- Hsu DT, Zak V, Mahony L, Sleeper LA, Atz AM, Levine JC, et al. Enalapril in infants with single ventricle: Results of a multicenter, randomized trial. *Circulation* 2010;122:333-40.
- Martins P, Castela E. Transposition of the great arteries. *Orphanet J Rare Dis* 2008;3:27.
- Hines RL. Congenital heart disease. In Stoelting RK, editor. *Stoelting's Anesthesia and Coexisting Disease*. 5th ed. London: Churchill Livingstone; 2008. p. 45-66.8.
- Akutsu Y, Kaneko K, Kodama Y, Li HL, Suyama J, Gokan T, et al. Sympathetic dysfunction of systemic right ventricle in congenitally corrected transposition of the great arteries. *Int J Cardiovasc Imaging* 2010;26:483-4.
- Sparks JW, Seefelder C, Shamberger RC, McGowan FX. The perioperative management of a patient with complex single ventricle physiology and pheochromocytoma. *Anesth Analg* 2005;100:972-5.
- DiNardo JA. Physiology of single ventricle, birth and beyond. *Anesthesiology* 2010;33:S275-7.

How to cite this article:***

Source of Support: Nil, **Conflict of Interest:** None declared