

# Primary Carcinosarcoma of Ovary an Unusual Tumor Case Report with Review of Literature

Rashmi Patnayak, Amitabh Jena<sup>1</sup>, Jaya Prakash<sup>1</sup>, Raja Sundaram<sup>1</sup>, Bodagala Vijaylaxmi<sup>2</sup>, Amarchala Yadagiri Lakhmi<sup>2</sup>

Departments of Pathology, <sup>1</sup>Surgical Oncology and <sup>2</sup>Radiology, Sri Venkateswara Institute of Medical Sciences, Tirupati, Andhra Pradesh, India

## ABSTRACT

Primary ovarian carcinosarcoma is a rare biphasic tumor. There is variable admixture of both malignant epithelial and stromal component seen in this tumor. We report a case of a primary carcinosarcoma of ovary in a 72-year-old post-menopausal female presenting with the complaint of abdominal distension. Staging laparotomy was done for this patient, and final histopathology was reported as the carcinosarcoma of ovary. The epithelial and sarcomatous components showed immunohistochemical positivity for their respective markers.

**KEY WORDS:** Malignant mixed Mullerian tumor, ovary, primary carcinosarcoma

## INTRODUCTION

Primary ovarian carcinosarcoma is a rare tumor. It accounts for 1-3% of ovarian malignancies. By definition, in this tumor, both epithelial and stromal components are malignant. It is also known as malignant mixed mesodermal tumor or malignant mixed Mullerian tumor. They are further sub-classified as “heterologous” or “homologous.” This categorization is based on the presence or absence of a stromal component containing mesenchymal tissue not normally found at the primary tumor site.<sup>[1]</sup> Usually, there is the extra-ovarian intra-abdominal spread at the time of diagnosis in the majority of the cases. The primary treatment has traditionally been surgical cytoreduction, followed by radiotherapy and chemotherapy or chemotherapy alone.<sup>[2]</sup> These tumors are aggressive in nature with poor prognosis.<sup>[1]</sup>

Hereby, we present a case of a primary carcinosarcoma of ovary in a 72-year-old female highlighting the histopathological and immunohistochemical findings.

## CASE REPORT

A 72-year-old post-menopausal female presented with distension of abdomen of 2 months duration. She also had a

complaint of pain in the lower abdomen since 1 month. She had no history of bleeding or white discharge per vaginum. There was a history of loss of weight and appetite. She did not give any previous history of surgery. She was a known hypertensive patient on irregular treatment. She was not a known diabetic.

Her abdomen was distended. She had a vague lump of size about 15 × 12 cm present in the lower abdomen. The lump was extending up to the epigastrium and was mobile. The lower part of the lump could not be palpated.

Cervix was atrophic as revealed by per vaginal examination. Per rectal examination did not reveal any abnormality.

The ultrasound examination of the abdomen showed left abdomino-pelvic mass. The contrast-enhanced computed tomography (CT) of the abdomen showed a large, hypodense, rim enhancing, multilobulated lower abdominal mass of 15 × 19 × 17 cm with enhancing mural component, arising from the left ovary. The right ovary appeared to be normal [Figures 1 and 2]. The uterus was atrophic. There was no significant abdominal lymphadenopathy. The ascites was moderate. The cytological examination of the ascitic fluid did not reveal any malignant cell.

The level of cancer antigen (CA)-125 was elevated (160.30 IU/ml, normal <35 IU/ml). The routine hematological

### Access this article online

#### Quick Response Code

**Website:**  
www.jbcrs.org

**DOI:**  
\*\*\*

### Address for correspondence

Dr. Rashmi Patnayak,  
Department of Pathology, Sri Venkateswara Institute of Medical Sciences,  
Tirupati, Andhra Pradesh - 517 507, India.  
E-mail: rashmpatnayak2002@yahoo.co.in

and biochemical investigations were within the normal limit.

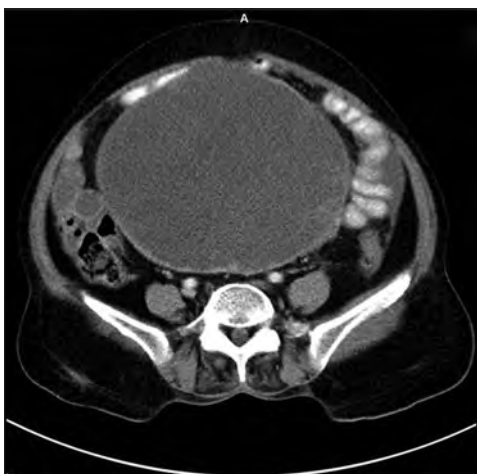
A staging laparotomy was planned. The intra-operative findings showed a complex ovarian cyst measuring 20 × 15 × 12 cm arising from the left ovary and adherent to mesentery and part of the small bowel. The tumor tissue was protruding out of the capsule and was adherent to the small bowel loops. There were no significant para-aortic or pelvic lymph nodes. The omentum was thickened without any distinct nodular deposits. Peritoneal deposits were also not noted. There was the presence of about 2000 ml of free fluid. Bilateral pelvic lymph node dissection and para-aortic lymph nodal sampling were done. Peritoneal biopsies were taken from five quadrants. Total omentectomy was done.

Cut section of a large irregular mass showed both solid and cystic areas [Figure 3]. Microscopically there were micropapillae with pleomorphic cells and hyperchromatic

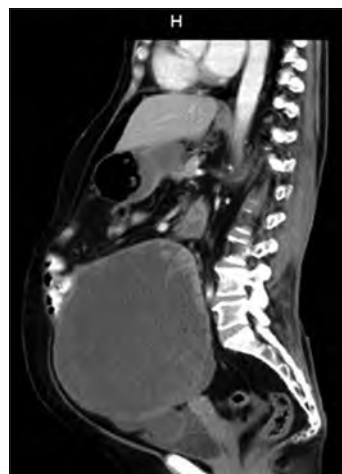nuclei. The stroma showed presence of oval to spindle-shaped cells with pleomorphic hyperchromatic nuclei and moderate amount of eosinophilic cytoplasm giving the rhabdoid appearance. Mitotic activity was frequent (8-9/10 high power field). There was also the presence of tumor necrosis and lymphatic emboli [Figures 4 and 5].

Immunohistochemistry showed cytokeratin and epithelial membrane antigen positivity in the epithelial component and the rhabdoid looking cells were positive for desmin [Figures 6 and 7]. Lymph nodes were reactive in nature. Based on the histopathological and immunohistochemical findings, the final diagnosis was given as the carcinosarcoma of ovary.

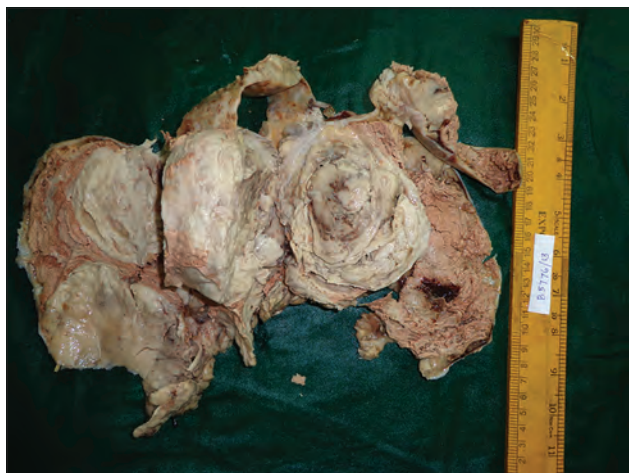
The patient had an uneventful post-operative period. She was advised medical oncology consultation following surgery. However, even after 6 months of surgery, she failed to turn up for further management.



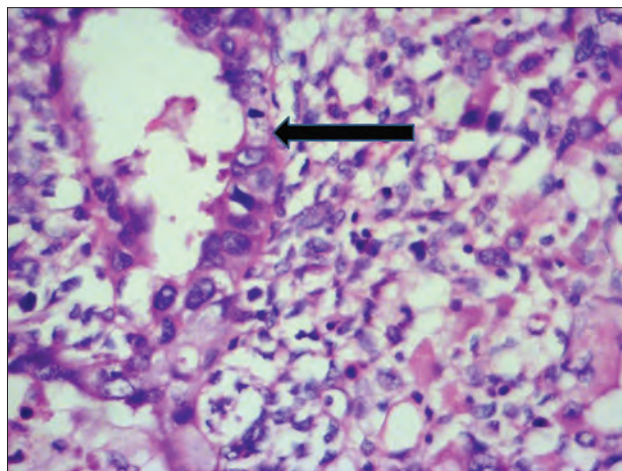
**Figure 1:** Contrast enhanced CT axial images showing large hypodense lesion with enhancing solid component peripherally and few septations within in the lower abdomen



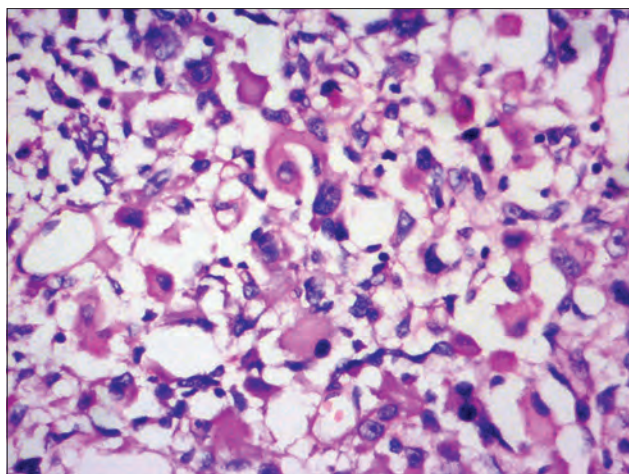
**Figure 2:** Contrast enhanced CT sagittal reconstruction images showing large hypodense lesion suggestive of malignant ovarian tumor



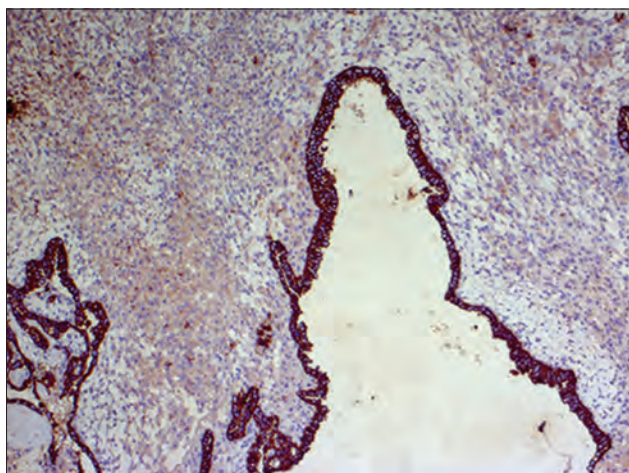
**Figure 3:** Cut section of resected ovarian mass with areas of necrosis



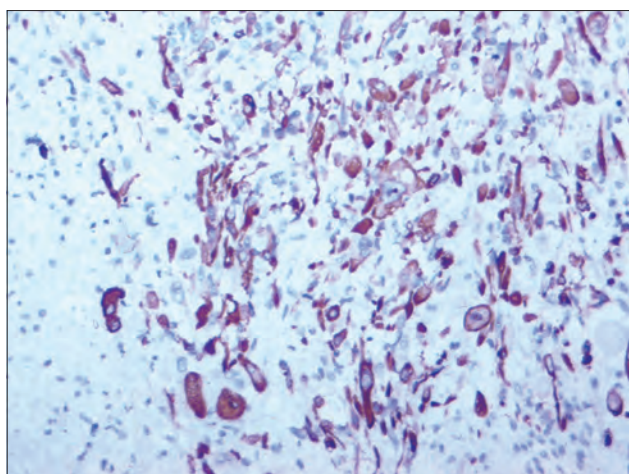
**Figure 4:** Microscopically the ovarian tumor showing presence of both epithelial (arrow) and stromal component (Hematoxylin and eosin, ×40)



**Figure 5:** Rhabdoid looking cells with vesicular nuclei eosinophilic cytoplasm (Hematoxylin and eosin, ×20)



**Figure 6:** Cyokeratin positivity for the epithelial component (Immunohistochemistry, ×20)



**Figure 7:** Desmin positivity in the rhabdoid cells (Immunohistochemistry, ×20)

## DISCUSSION

The synonyms of carcinosarcoma of ovary include

malignant mixed tumor, malignant mixed mesodermal tumors or malignant mixed Mullerian tumor. However, unlike its uterine counterpart, the incidence of ovarian carcinosarcoma is quite low. Therefore, the literature regarding primary ovarian carcinosarcoma is sparse. These biphasic tumors are defined by the histological presence of intermixed malignant epithelial and stromal elements. Recent studies suggest a monoclonal theory of histogenesis for ovarian carcinosarcomas. These studies have proposed that because of metaplastic transformation of the epithelial component, tumorigenesis results in giving rise to the sarcomatous component.<sup>[1]</sup>

These tumors tend to occur in older women and follow an aggressive clinical course when compared to that in the epithelial ovarian tumors.<sup>[3]</sup>

Our patient was a post-menopausal female of 72 years of age.

Pre-operative suspicion or confirmation of the diagnosis of primary ovarian carcinosarcoma remains quite challenging. The clinical and radiological findings are practically indistinguishable from other ovarian surface epithelial tumors. Tumor markers like CA-125 may not be elevated in all the cases. Even cytological analysis of ascitic fluid may not always reveal malignant component.

In our patient, there was the presence of a large abdominal lump and associated pain. The CT findings suggested an ovarian tumor. The definitive diagnosis of carcinosarcoma was made by histopathological examination of the resected specimen. The biphasic component was further highlighted by the immunohistochemical analysis.

In a study by Menon *et al.*, preoperative raise of CA-125 was noted in 9 out of the 12 cases of ovarian carcinosarcoma. The hemorrhagic ascitic fluid revealed adenocarcinomatous component in four of their cases.<sup>[1]</sup>

In our case, CA-125 was elevated. However, the ascitic fluid cytology did not show any malignancy.

In ovarian carcinosarcoma, there is the presence of both intermixed malignant epithelial and stromal component. Boucher *et al.*, in their series of ovarian carcinosarcomas, have described equal representation of the epithelial endometrioid and serous component types. The mesenchymal component was largely heterologous, of chondromatous and rhabdomyoblastic differentiation.<sup>[4]</sup> In another study, Kunkel *et al.* had an overwhelming serous carcinoma component with a predominance of heterologous chondromatous component.<sup>[5]</sup> In a recent study by

Menon *et al.* they found endometrioid carcinoma and heterologous rhabdomyosarcoma as predominant epithelial and mesenchymal component respectively.<sup>[1]</sup>

In our case, we have noted the presence of the epithelial component as serous carcinoma and stromal component as rhabdomyosarcoma. These two components were demonstrated both histopathologically as well as by means of immunohistochemistry.

Primary ovarian carcinosarcomas are very aggressive and are usually diagnosed at an advanced age and an advanced stage of disease.<sup>[6]</sup>

The adverse prognostic factors as enumerated by various studies include advanced age, advanced stage, suboptimal cytoreduction, stromal predominant tumors and tumors with serous epithelial component.<sup>[1,7]</sup> Few studies consider the initial stage of the disease at the time of diagnosis as the only prognostic factor.<sup>[8]</sup> In our case, though there was a rupture of the tumor, there were no omental or peritoneal deposits.

There is no existing consensus regarding treatment of ovarian carcinosarcoma. However, surgical treatment is regarded as the best option for the survival of patients.<sup>[8]</sup> The most effective treatment consists of optimal debulking, followed by paclitaxel and/or platinum-based chemotherapy.<sup>[9,10]</sup>

Various chemotherapeutic regimes have included cisplatin alone; a combination of doxorubicin, ifosfamide, dacarbazine, cyclophosphamide, taxol; and other combinations.<sup>[2]</sup> Response rates to chemotherapy are about 20%.<sup>[8]</sup>

The survival for both early and late stage carcinosarcoma is inferior to serous tumors of the ovary.<sup>[3]</sup> The average survival for a woman diagnosed with carcinosarcoma of the ovary is <2 years.<sup>[11]</sup>

New modalities of treatment are being explored to treat this uncommon tumor. Trop-2 is overexpressed in a proportion of uterine and ovarian carcinosarcomas, and hRS7, a humanized anti-Trop-2 antibody, may represent a novel, potentially highly effective treatment option for patients with treatment-refractory carcinosarcomas overexpressing Trop-2.<sup>[12]</sup> Human epidermal growth factor-2/neu may also represent another novel target for the immunotherapy of

a subset of human carcinosarcomas refractory to salvage chemotherapy.<sup>[13]</sup>

This case is being presented for its relative uncommon nature, emphasizing the histopathological features.

## REFERENCES

1. Menon S, Deodhar K, Rekh B, Dhake R, Gupta S, Ghosh J, *et al.* Clinico-pathological spectrum of primary ovarian malignant mixed müllerian tumors (OMMT) from a tertiary cancer institute: A series of 27 cases. *Indian J Pathol Microbiol* 2013;56:365-71.
2. Shylasree TS, Bryant A, Athavale R. Chemotherapy and/or radiotherapy in combination with surgery for ovarian carcinosarcoma. *Cochrane Database Syst Rev* 2013;2:CD006246.
3. George EM, Herzog TJ, Neugut AI, Lu YS, Burke WM, Lewin SN, *et al.* Carcinosarcoma of the ovary: Natural history, patterns of treatment, and outcome. *Gynecol Oncol* 2013;131:42-5.
4. Boucher D, Têtu B. Morphologic prognostic factors of malignant mixed müllerian tumors of the ovary: A clinicopathologic study of 15 cases. *Int J Gynecol Pathol* 1994;13:22-8.
5. Kunkel J, Peng Y, Tao Y, Krigman H, Cao D. Presence of a sarcomatous component outside the ovary is an adverse prognostic factor for primary ovarian malignant mixed mesodermal/müllerian tumors: A clinicopathologic study of 47 cases. *Am J Surg Pathol* 2012;36:831-7.
6. Loizzi V, Cormio G, Camporeale A, Falagario M, De Mitri P, Scardigno D, *et al.* Carcinosarcoma of the ovary: Analysis of 13 cases and review of the literature. *Oncology* 2011;80:102-6.
7. Athavale R, Thomakos N, Godfrey K, Kew F, Cross P, de Barros Lopes A, *et al.* The effect of epithelial and stromal tumor components on FIGO stages III and IV ovarian carcinosarcomas treated with primary surgery and chemotherapy. *Int J Gynecol Cancer* 2007;17:1025-30.
8. Muller M, Dupre PF, Lucas B, Simon H, Malhaire JP, Guillemet C, *et al.* Carcinosarcoma of the ovary. *J Gynecol Obstet Biol Reprod (Paris)* 2007;36:399-402.
9. del Carmen MG, Birrer M, Schorge JO. Carcinosarcoma of the ovary: A review of the literature. *Gynecol Oncol* 2012;125:271-7.
10. Chun KC, Kim JJ, Kim DY, Kim JH, Kim YM, Nam JH, *et al.* Optimal debulking surgery followed by paclitaxel/platinum chemotherapy is very effective in treating ovarian carcinosarcomas: A single center experience. *Gynecol Obstet Invest* 2011;72:208-14.
11. Cantrell LA, Van Le L. Carcinosarcoma of the ovary a review. *Obstet Gynecol Surv* 2009;64:673-80.
12. Raji R, Guzzo F, Carrara L, Varughese J, Cocco E, Bellone S, *et al.* Uterine and ovarian carcinosarcomas overexpressing Trop-2 are sensitive to hRS7, a humanized anti-Trop-2 antibody. *J Exp Clin Cancer Res* 2011;30:106.
13. Guzzo F, Bellone S, Buza N, Hui P, Carrara L, Varughese J, *et al.* HER2/neu as a potential target for immunotherapy in gynecologic carcinosarcomas. *Int J Gynecol Pathol* 2012;31:211-21.

**How to cite this article:\*\*\***

**Source of Support:** Nil, **Conflict of Interest:** None declared