



## Lead Acetate-induced Changes in Haematological Indices and Bone Marrow of Adult Wistar Rats: Protective Role of $\alpha$ -Tocopherol (Vitamin E)

MOMODU, OI; IDEMUDIA, OU

Department of Anatomy, School of Basic Medical Sciences, University of Benin, Edo State, Nigeria

\*Corresponding Author Email: [eghosa.idemudia@uniben.edu](mailto:eghosa.idemudia@uniben.edu)  
\*Tel: +234 802 3635 289

Co-author Email: [oghenakhogie.momodu@uniben.edu](mailto:oghenakhogie.momodu@uniben.edu); Tel: +234 703 8754 920

**ABSTRACT:** Lead exposure has been associated with several adverse health effects involving multiple body systems and organ failure. Hence, the objective of this paper was to the effects of  $\alpha$ -Tocopherol (Vitamin E) on haematological indices and bone marrow of lead acetate (LA)-exposed adult Wistar rats. Twenty (20) adult Wistar rats (n=5) were randomly assigned as follows: Control group (A) received 1ml of distilled water; Group B received 100 mg/kg body weight (BW) of LA; Group C received 50 mg/kg BW of  $\alpha$ -Tocopherol and 100 mg/kg BW of LA; Group D received 50 mg/kg BW  $\alpha$ -Tocopherol only. All administrations, via an oral gavage, lasted for twenty-eight days. Following the sacrifice of experimental rats, blood samples were collected in Ethylenediaminetetraacetic acid bottles for hematological analysis and the femur of rats were fixed in 10% neutral buffered formalin for histological evaluation. Results showed that the haematological indices in group B rats were significantly different ( $P < 0.05$ ) when compared to control. Also, the histological findings in group B rats revealed mild hypoplasia of the haematopoietic cells with severe vacuolations following comparison to control. However, in group C rats treated with  $\alpha$ -Tocopherol, the adverse effects of LA were attenuated. Rats in group D showed no significant differences ( $P > 0.05$ ) in the parameters investigated when compared to control. Conclusively, results from this study showed that  $\alpha$ -Tocopherol can mitigate the toxic effects of lead on the haematological system, and further studies are needed to corroborate these findings and investigate the mechanisms of action.

DOI: <https://dx.doi.org/10.4314/jasem.v28i6.22>

**Open Access Policy:** All articles published by **JASEM** are open-access articles and are free for anyone to download, copy, redistribute, repost, translate and read.

**Copyright Policy:** © 2024. Authors retain the copyright and grant **JASEM** the right of first publication with the work simultaneously licensed under the **Creative Commons Attribution 4.0 International (CC-BY-4.0) License**. Any part of the article may be reused without permission provided that the original article is cited.

**Cite this Article as:** MOMODU, O. I; IDEMUDIA, O. U. (2024). Lead Acetate-induced Changes in Haematological Indices and Bone Marrow of Adult Wistar Rats: Protective Role of  $\alpha$ -Tocopherol (Vitamin E). *J. Appl. Sci. Environ. Manage.* 28 (6) 1821-1826

**Dates:** Received: 01 April 2024; Revised: 28 May 2024; Accepted: 10 June 2024 Published: 12 June 2024

**Keywords:**  $\alpha$ -Tocopherol; Lead acetate; Haematology; Bone marrow; Histology; Vitamin E

Lead is a poisonous ubiquitous metal that exists in the environment and is one of the most widely studied toxic substances (Enogieru and Iyoha, 2023). It enters the body system either via the respiratory structures or gastrointestinal tracts and is taken up in large amounts by the liver which acts as a repository before being passed to the kidney where a small fraction is evacuated via urine (Wani *et al.*, 2015). Lead may also concentrate within the bone marrow, brain, and testis, with its accumulation resulting in serious damage in the respective tissues (Sanders *et al.*, 2009). Lead toxicity has also been shown to affect the erythrocyte membrane, causing a significant reduction in erythrocyte mobility and an alteration of other haematological parameters (Suwalsky *et al.*, 2003). Lead-induced oxidative stress has been attributed as

one of the leading etiologies of lead poisoning (Enogieru and Momodu, 2022; Patra *et al.*, 2011). Thus, low to high levels of lead exposure could result in different responses to oxidative stress within various target sites such as the blood vessels, liver, brain, testes, and lungs (Mandal *et al.*, 2022). In rats, the beneficial role of antioxidants has been previously reported against metal toxicity (Enogieru and Egbon, 2022; Enogieru and Momodu, 2021; Enogieru and Omoruyi, 2022).

For instance, the use of ascorbic acid as a potent antioxidant in rabbits (Rabbani *et al.*, 2003), rats (Nandi *et al.*, 2005), and other rodents (Rana *et al.*, 2008). Similarly,  $\alpha$ -Tocopherol, also known as Vitamin E is a dietary essential that acts as a first line

of defense against pro-oxidants (Rizvi *et al.*, 2014). It is a fat-soluble vitamin with powerful anti-oxidative properties that protect the cell against the oxidizing activity of free radicals and lipid peroxidation, thus preventing oxidative stress (Rizvi *et al.*, 2014).

$\alpha$ -Tocopherol has also been found to be beneficial in improving immune function, lowering the risk of vascular thromboembolism, and providing support for patients with coronary heart disease and stroke (Vardi *et al.*, 2013). Taking into consideration the above effects of  $\alpha$ -Tocopherol, hence, the objective of this paper was to investigate the effects of  $\alpha$ -Tocopherol (Vitamin E) on haematological indices and bone marrow of lead acetate (LA) - exposed adult Wistar rats.

## MATERIALS AND METHODS

**Chemicals and Reagents:** Lead acetate and  $\alpha$ -Tocopherol were procured from Loba Chemie, India. Other reagents were all of the analytical grades

**Animal Care and Management:** Twenty (20) adult Wistar rats, weighing between 180-200g, were purchased from the animal holdings of the Department of Anatomy, University of Benin, Benin City. Care and management of animals were done following the guidelines for the care and use of laboratory animals (National Research Council of the National Academics, 2011). The animals were allowed to acclimatize for a period of two weeks before the commencement of the experiment.

**Experimental Design:** The rats were randomly assigned into a control group (A) and three treatment groups B, C, and D containing n=5 rats/group. Control group (A) received 1ml of distilled water; Group B received 100 mg/kg body weight (BW) of LA; Group C received 50 mg/kg BW of  $\alpha$ -Tocopherol and 100 mg/kg BW of LA; Group D received 50 mg/kg BW  $\alpha$ -Tocopherol only. The administration was carried out daily using an oral gavage for a period of twenty-eight (28) days.

**Sacrifice of Rats:** At the end of the experimental period, the animals were sacrificed under chloroform anaesthesia, and blood samples were collected, by Cardiac puncture, in Ethylenediaminetetraacetic acid (EDTA) bottles for determination of hematological indices. The femur of the experimental rats was

dissected out and fixed in 10 % Neutral buffered formalin for tissue processing.

**Hematological Analysis:** Blood analysis, using an automatic hematological assay analyzer, was used to analyze the blood samples at the laboratory of Accident and Emergency (A & E), University of Benin Teaching Hospital, Benin City, as previously reported (Kanu *et al.*, 2016). Hematological parameters analyzed of interest include: Red Blood Cell (RBC) count, White Blood Cell (WBC) counts, differential white blood cell counts including Lymphocyte, Monocyte, and Granulocyte Counts, Hemoglobin concentration (HbC), Erythrocyte indices analyzed were Mean Corpuscular Volume (MCV), Mean Corpuscular Hemoglobin Concentration (MCHC), Mean Corpuscular Hemoglobin (MCH) and Packed cell volume (PCV).

**Histology of the Bone marrow:** The bones were fixed in 10% neutral buffered formalin for 48 hours. The bones were decalcified in 10% nitric acid for 7 days. They were then processed and stained in Hematoxylin and Eosin as previously reported (Drury and Wallington, 1980).

**Statistical Analysis:** All values are presented as mean  $\pm$  standard error of the mean for all groups. The significance of the difference in the means of all parameters was determined using a one-way analysis of variance (95% confidence interval). Least Square difference, *post-hoc* tests were carried out for all groups with control and comparison of all pairs of groups respectively. All statistical analysis was carried out using the Statistical Package for Social Sciences (SPSS) (version 16) manufactured by the International Business Machine Corporation (IBM) in Armonk, New York.

## RESULTS AND DISCUSSION

**Effects on Hematological Indices:** Results showed that the RBC, Hb concentration, PVC, MCV, MCH, and MCHC of rats in group B was significantly ( $P < 0.05$ ) decreased when compared with the control. These parameters were not significantly ( $P > 0.05$ ) different in rats treated with  $\alpha$ -Tocopherol only when compared with control. However, there was a significant increase in these parameters in group C rats ( $\alpha$ -Tocopherol + lead acetate) when compared with group B rats treated with lead acetate only (Table 1).

**Table 1:** Effects of  $\alpha$ -tocopherol and lead acetate administration on packed cell volume, red blood cell count, hemoglobin concentration, and erythrocyte indices

	A (Control)	B (Lead acetate only)	C ( $\alpha$ -Tocopherol + Lead Acetate)	D ( $\alpha$ -Tocopherol)
RBC Count ( $\times 10^3/\mu\text{l}$ )	7.70 $\pm$ 0.11	6.03 $\pm$ 0.36 <sup>#</sup>	6.90 $\pm$ 0.51 <sup>*</sup>	7.54 $\pm$ 0.26
Hb (g/dl)	13.27 $\pm$ 0.07	10.43 $\pm$ 0.52 <sup>#</sup>	13.23 $\pm$ 0.18 <sup>*</sup>	12.33 $\pm$ 0.24
PCV (%)	42.20 $\pm$ 0.20	30.58 $\pm$ 1.42 <sup>#</sup>	40.80 $\pm$ 0.76 <sup>*</sup>	38.43 $\pm$ 0.70
MCV (fl/cell)	54.77 $\pm$ 0.53	36.77 $\pm$ 3.68 <sup>#</sup>	51.03 $\pm$ 1.13 <sup>*</sup>	52.20 $\pm$ 1.13
MCH (pg/dl)	17.50 $\pm$ 0.20	15.13 $\pm$ 0.07 <sup>#</sup>	16.97 $\pm$ 0.69 <sup>*</sup>	16.47 $\pm$ 0.03
MCHC (g/dl)	31.40 $\pm$ 0.00	26.73 $\pm$ 0.75 <sup>#</sup>	32.43 $\pm$ 0.32 <sup>*</sup>	32.07 $\pm$ 0.03

Data is represented as Mean  $\pm$  SEM; <sup>#</sup> and <sup>\*</sup> represent  $P < 0.05$  when compared with control and Lead acetate groups respectively.

It was also observed that the Lymphocyte, Granulocyte, Monocyte counts, and the WBC of rats in group B were significantly ( $P < 0.05$ ) increased when compared with the control. These parameters were not significantly ( $P > 0.05$ ) different in rats treated with  $\alpha$ -Tocopherol only when compared with control.

However, there was a significant decrease in these parameters in group C rats ( $\alpha$ -Tocopherol + lead acetate) when compared with group B rats treated with lead acetate only (Table 2). In addition, there were no significant ( $P > 0.05$ ) differences in the Platelet count of rats across experimental groups.

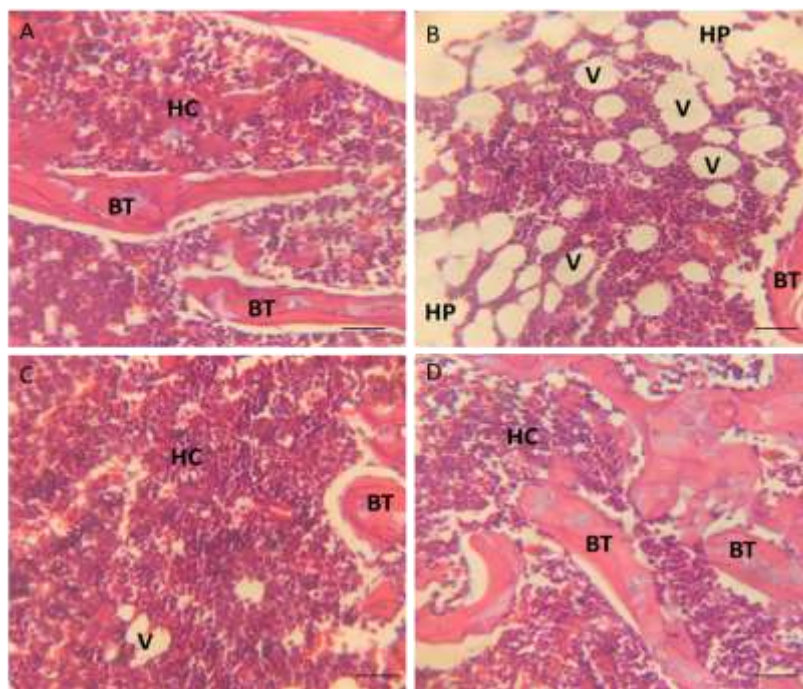
**Table 2:** Effect of  $\alpha$ -tocopherol and lead acetate administration leucocyte count and leucocyte indices.

	A (Control)	B (Lead acetate only)	C ( $\alpha$ -Tocopherol + Lead Acetate)	D ( $\alpha$ -Tocopherol)
WBC Count $\times 10^3/\mu\text{l}$	9.13 $\pm$ 0.47	14.57 $\pm$ 0.52 #	10.17 $\pm$ 0.62 *	9.87 $\pm$ 0.20
Lymphocyte Count ( $\times 10^3/\mu\text{l}$ )	4.53 $\pm$ 0.44	8.70 $\pm$ 0.66 #	6.17 $\pm$ 0.15 *	5.83 $\pm$ 0.59
Granulocyte Count ( $\times 10^3/\mu\text{l}$ )	4.10 $\pm$ 0.10	5.13 $\pm$ 0.24 #	4.07 $\pm$ 0.44 *	3.90 $\pm$ 0.17
Monocyte Count ( $\times 10^3/\mu\text{l}$ )	1.02 $\pm$ 0.06	1.34 $\pm$ 0.19 #	1.18 $\pm$ 0.20 *	1.22 $\pm$ 0.18
Platelet Count ( $\times 10^3/\mu\text{l}$ )	612.00 $\pm$ 21.00	550.00 $\pm$ 18.00	608.00 $\pm$ 29.46	528.33 $\pm$ 52.454

Data is represented as Mean  $\pm$  SEM; # and \* represent  $P < 0.05$  when compared with control and Lead acetate groups respectively.

**Effects on Bone Marrow Histology:** The photomicrographs of control group A showed normal meshwork of bone trabeculae (BT) with the intertrabecular spaces containing hemopoietic cells with adequate cellularity (HC). Group B rats treated with lead acetate showed mild hypoplasia of haematopoietic cells (HP) and severe vacuolation (V).

Group C rats treated with  $\alpha$ -tocopherol and lead acetate showed relatively normal features of the bone marrow with few vacuolations. Group D rats treated with  $\alpha$ -tocopherol showed normal meshwork of bone trabeculae with the intertrabecular spaces containing hemopoietic cells with adequate cellularity (Figure 1).



**Fig 1:** Histology of the bone marrow across experimental groups. (A). Control rats (B). Rats treated with lead acetate only (C). Rats treated with  $\alpha$ -tocopherol and lead acetate (D). Rats treated with  $\alpha$ -tocopherol only. H&E 100x. Scale bar 100  $\mu\text{m}$ .

The major important target of lead is the hematological system and induces changes in the composition of red blood cell membrane protein, and lipids and inhibits the synthesis of hemoglobin (Collin *et al.*, 2022). This present investigation revealed that PCV, Hb concentration, MCV, MCH, MCHC, and RBC of rats treated with lead acetate were significantly decreased compared with control, in agreement with previous studies (El-Bahr *et al.*, 2021; Suradkar *et al.*, 2009). Reduction in Hb concentration has been attributed to the ability of lead to convert co-protoporphyrinogen III

to protoporphyrin IX (Sachar *et al.*, 2016). A reduction in RBC count, haemoglobin, and packed cell volume has been linked to decreased rate of erythrocyte production or an increased rate of erythrocyte loss (Sutton and Sellon, 2013). Reports show that lead may inhibit the body’s ability to make hemoglobin via interference with several enzymatic steps in the heme pathway. Precisely, lead reduces heme biosynthesis by impeding aminolaevulinic acid dehydratase and ferro chelatase activity (El-shater *et al.*, 2022). Lead affects the loss of Hb molecule stability and erythrocyte

morphology and survival (El-shater *et al.*, 2022). In this study, treatment with  $\alpha$ -tocopherol significantly increased PCV, Hb concentration, MCH, MCV, and MCHC when compared with rats treated with lead acetate alone. The mechanism by which  $\alpha$ -tocopherol ameliorates lead-induced hematological changes is not clear but reports have linked this effect to its potent antioxidant properties (Antosik *et al.*, 2018; Das *et al.*, 2012). In agreement with previous studies, the WBC count, Lymphocyte count, and Platelet count of rats treated with lead acetate were significantly increased when compared with control (Andjelkovic *et al.*, 2019; El-shater *et al.*, 2022). White blood cells, also known as Leucocytes, play a vital role in protecting the body against foreign invaders. They are produced by multipotent cells in the bone marrow and circulate in the blood and the lymphatic system (El-shater *et al.*, 2022). Elevated WBCs could be a result of inflammation induced by lead. Increased Pb concentration in the blood induced an increase in leukogram including lymphocytes, neutrophils, eosinophils, and monocytes (Abubakar *et al.*, 2019). Leukocytosis with lymphocytosis, indicative of bone marrow toxicity and implicated in the development of a lymphoproliferative neoplasm has been linked to lead toxicity (Aprioku and Obianime, 2014; El-shater *et al.*, 2022). This study demonstrated that the values of WBC count, Lymphocyte count, and Platelet count were significantly restored to near normal following treatment with  $\alpha$ -tocopherol. This effect against lead acetate may be due to its anti-inflammatory and immunomodulatory effects, as previously reported (Lewis *et al.*, 2019; Nazrun *et al.*, 2012).

The histology of the bone marrow of rats treated with lead acetate showed mild hypoplasia of haematopoietic cells with severe vacuolation. These observations are in agreement with other studies showing lead acetate-induced toxic damage to the normal functioning of bone and bone marrow (Haleagrahara *et al.*, 2010; Othman *et al.*, 2004). In some studies, lead toxicity was reported to cause a weak clastogenic effect on rat bone marrow cells which was attributed to excessive ROS generation or failure of the cellular antioxidant system (Haleagrahara *et al.*, 2010; Hamadouche, 2009). However, in lead acetate-exposed rats treated with  $\alpha$ -tocopherol, there were relatively normal features of the bone marrow with few vacuolations, thus indicating that  $\alpha$ -tocopherol treatment may have a bone marrow growth stimulating effect.

**Conclusion:** Findings from this study demonstrated that  $\alpha$ -tocopherol protected the haematological system and bone marrow of experimental rats from the toxic effects of lead acetate and highlighted its usefulness as a possible therapeutic agent against disorders linked to lead exposure. Further studies are recommended to investigate its mechanisms of action in other models of lead toxicity.

## REFERENCES

- Abubakar, K; Muhammad Mailafiya, M; Danmaigoro, A; Musa Chiroma, S; Abdul Rahim, EB; Abu Bakar Zakaria, MZ (2019). Curcumin attenuates lead-induced cerebellar toxicity in rats via chelating activity and inhibition of oxidative stress. *Biomolecules*. 9(9): 453. DOI: 10.3390/biom9090453
- Andjelkovic, M; Buha Djordjevic, A; Antonijevic, E; Antonijevic, B; Stanic, M; Kotur-Stevuljevic, J; Spasojevic-Kalimanovska, V; Jovanovic, M; Boricic, N; Wallace, D (2019). Toxic effect of acute cadmium and lead exposure in rat blood, liver, and kidney. *Int. J. Environ. Res. Public Health*. 16(2): 274. DOI: 10.3390/ijerph16020274
- Antosik, A; Czubak, K; Cichon, N; Nowak, P; Zbikowska, H (2018). Vitamin E analogue protects red blood cells against storage-induced oxidative damage. *Transfus. Med. Hemother.* 45(5): 347-354. DOI: 10.1159/000486605
- Aprioku, J; Obianime, A (2014). Evaluation of the effects of Citrus aurantifolia (Lime) juice in lead-induced hematological and testicular toxicity in rats. *Pharmacologia*. 5(1): 36-41. DOI: 10.5567/pharmacologia.2014.36.41
- Collin, MS; Venkatraman, SK; Vijayakumar, N; Kanimozhi, V; Arbaaz, SM; Stacey, RS; Anusha, J; Choudhary, R; Lvov, V; Tovar, GI (2022). Bioaccumulation of lead (Pb) and its effects on human: A review. *J. Hazard. Mater. Adv.* 7: 100094. DOI: 10.1016/j.hazl.2022.100064
- Das, TK; Mani, V; Kaur, H; Kewalramani, N; Agarwal, A (2012). Effect of vitamin E supplementation on hematological and plasma biochemical parameters during long term exposure of arsenic in goats. *Asian-Australas. J. Anim. Sci.* 25(9): 1262. DOI: 10.5713/ajas.2012.12043
- Drury, R; Wallington, E (1980). Carleton's histological technique 5th ed. New York: Churchill Livingstone.
- El-Bahr, SM; Elbakery, AM; El-Gazzar, N; Amin, AA; Al-Sultan, S; Alfattah, MA; Shousha, S; Alhojaily, S; Shathele, M; Sabeq, II (2021). Biosynthesized iron oxide nanoparticles from *Petroselinum crispum* leaf extract mitigate lead-acetate-induced anemia in male albino rats: hematological, biochemical and histopathological features. *Toxics*. 9(6): 123. DOI: 10.3390/toxics9060123
- El-shater, A-R; Ali, R; Fawy, MA (2022). Study on toxic effects of lead acetate on haematological parameters of adult albino rats and the role of

- mesenchymal stem cells and flax seeds oil as therapeutic agents. *Egypt. Acad. J. Biol. Sci.* 14(2): 123-136. DOI: 10.21608/EAJBSZ.2022.253274
- Enogieru, A; Egbon, F (2022). Neurobehavioural and Histological Alterations in Lead Acetate-Exposed Rats Pretreated with Aqueous Leaf Extract of *Vernonia amygdalina*. *Afr. J. Biomed. Res.* 25(2): 205-213. DOI: 10.4314/ajbr.v25i2.14
- Enogieru, A; Momodu, O (2021). The Developing Cerebellum as a Target for Toxic Substances: Protective Role of Antioxidants. *The Cerebellum.* 20(4): 614-630. DOI: 10.1007/s12311-021-01231-0
- Enogieru, A; Momodu, O (2022). Neuroprotective effects of *Zingiber officinale* against lead-induced toxicity in Wistar rats. *Nutrire.* 48(1): 2. DOI: 10.1186/s41110-022-00184-6
- Enogieru, A; Omoruyi, S (2022). Exploration of Aqueous *Phyllanthus amarus* Leaf Extract as a Protective Agent in Mercury Chloride-Exposed Wistar Rats: A Neurobehavioural Study. *J. Appl. Sci. Environ. Manage.* 26(4): 629-637. DOI: 10.4314/jasem.v26i4.10
- Enogieru, AB; Iyoha, EN (2023). Role of Nitric Oxide, TNF- $\alpha$  and Caspase-3 in Lead Acetate-Exposed Rats Pretreated with Aqueous *Rosmarinus officinalis* Leaf Extract. *Biol. Trace Elem. Res.* 1-11. DOI: 10.1007/s12011-023-03974-9
- Haleagrahara, N; Jackie, T; Chakravarthi, S; Rao, M; Pasupathi, T (2010). Protective effects of *Etlingera elatior* extract on lead acetate-induced changes in oxidative biomarkers in bone marrow of rats. *Food. Chem. Toxicol.* 48(10): 2688-2694. DOI: 10.1016/j.fct.2010.06.041
- Hamadouche, NA (2009). Reproductive toxicity of lead acetate in adult male rats. *Am. J. Sci. Res.* 3: 38-50.
- Kanu, KC; Ijioma, SN; Atiata, O (2016). Haematological, biochemical and antioxidant changes in Wistar rats exposed to dichlorvos based insecticide formulation used in Southeast Nigeria. *Toxics.* 4(4): 28. DOI: 10.3390/toxics4040028
- Lewis, ED; Meydani, SN; Wu, D (2019). Regulatory role of vitamin E in the immune system and inflammation. *IUBMB life.* 71(4): 487-494. DOI: 10.1002/iub.1976
- Mandal, GC; Mandal, A; Chakraborty, A (2022). The toxic effect of lead on human health: A review. *Hum. Biol. Public Health.* 3: 1-11. DOI: 10.52905/hbph2022.3.45
- Nandi, D; Patra, R; Swarup, D (2005). Effect of cysteine, methionine, ascorbic acid and thiamine on arsenic-induced oxidative stress and biochemical alterations in rats. *Toxicology.* 211(1-2): 26-35. DOI: 10.1016/j.tox.2005.02.013
- National Research Council of the National Academics, N (2011). Guide for the Care and Use of Laboratory Animals (Washington, DC: The National Academies Press).
- Nazrun, A; Norazlina, M; Norliza, M; Nirwana, SI (2012). The anti-inflammatory role of vitamin E in prevention of osteoporosis. *Adv. Pharmacol. Pharm. Sci.* 2012. DOI: 10.1155/2012/142702
- Othman, A; Al Sharawy, S; El-Missiry, M (2004). Role of melatonin in ameliorating lead induced haematotoxicity. *Pharmacol. Res.* 50(3): 301-307. DOI: 10.1016/j.phrs.2004.01.013
- Patra, R; Rautray, AK; Swarup, D (2011). Oxidative stress in lead and cadmium toxicity and its amelioration. *Vet. Med. Int.* 2011. DOI: 10.4061/2011/457327
- Rabbani, GH; Saha, SK; Akhtar, M; Marni, F; Mitra, AK; Ahmed, S; Alauddin, M; Bhattacharjee, M; Sultana, S; Chowdhury, AA (2003). Antioxidants in detoxification of arsenic-induced oxidative injury in rabbits: preliminary results. *J. Environ. Sci. Health.* 38(1): 273-287. DOI: 10.1081/ese-120016894
- Rana, T; Sarkar, S; Mandal, T; Batabyal, S (2008). Haematobiochemical profiles of affected cattle at arsenic prone zone in Haringhata block of Nadia District of West Bengal in India. *Inter. J. Hematol.* 4(2).
- Rizvi, S; Raza, ST; Ahmed, F; Ahmad, A; Abbas, S; Mahdi, F (2014). The role of vitamin E in human health and some diseases. *Sultan Qaboos Univ. Med. J.* 14(2): e157.
- Sachar, M; Anderson, KE; Ma, X (2016). Protoporphyrin IX: the good, the bad, and the ugly. *J. Pharmacol. Exp. Ther.* 356(2): 267-275. DOI: 10.1124/jpet.115.228130
- Sanders, T; Liu, Y; Buchner, V; Tchounwou, PB (2009). Neurotoxic effects and biomarkers of lead exposure: a review. *Rev. Environ. Health.* 24(1): 15-46. DOI: 10.1515/REVEH.2009.24.1.15
- Suradkar, S; Ghodasara, D; Vihol, P; Patel, J; Jaiswal, V; Prajapati, K (2009). Haemato-Biochemical Alterations induced by lead acetate toxicity in Wistar Rats. *Vet. World.* 2(11): 429-431.

- Sutton, DG; Sellon, DC (2013). Haematopoietic and immune systems. *Equine medicine, surgery and reproduction*. 195-210. DOI: 10.1016/B978-0-7020-2801-4.00010-9
- Suwalsky, M; Villena, F; Norris, B; Cuevas, Y; Sotomayor, C; Zatta, P (2003). Effects of lead on the human erythrocyte membrane and molecular models. *J. Inorg. Biochem.* 97(3): 308-313. DOI: 10.1016/s0162-0134(03)00292-7
- Vardi, M; Levy, NS; Levy, AP (2013). Vitamin E in the prevention of cardiovascular disease: the importance of proper patient selection. *J. Lipid Res.* 54(9): 2307-2314. DOI: 10.1194/jlr.R026641
- Wani, AL; Ara, A; Usmani, JA (2015). Lead toxicity: a review. *Interdiscip. Toxicol.* 8(2): 55. DOI: 10.1515/intox-2015-0009