



## Assessment of Protective Effect of Turmeric on Aspirin Induced Gastric Injury on Wistar Rats

\*<sup>1</sup>AKEREDOLU, FF; <sup>2</sup>OLADELE, AA; <sup>2</sup>EKUNDINA, VO

<sup>1</sup>Ekiti State Hospital Management Board Ado- Ekiti, Ekiti State Nigeria,

<sup>2</sup>College of Medicine and Health Science, Department of Medical Laboratory Science, Afe Babalola University Ado Ekiti, Ekiti State, Nigeria

\*Corresponding Authors Email: [florry.akeredolu@gmail.com](mailto:florry.akeredolu@gmail.com); [akeredoluff@pg.abuad.edu.ng](mailto:akeredoluff@pg.abuad.edu.ng)  
Co-Authors Email: [oladele@abuad.edu.ng](mailto:oladele@abuad.edu.ng); [kemvic30@gmail.com](mailto:kemvic30@gmail.com)

**ABSTRACT:** Turmeric (from *Zingiberaceae* family) is highly regarded as a universal panacea in the herbal medicine with a wide spectrum of pharmacological activities. Forty eight adult rats (150g-200g body weight) were randomly divided into six (control, treatment, 3 post treatment and recovery) groups of eight rats each. Gastric injury were induced with the administration of different concentration of Aspirin and co treated with different concentration of Turmeric for a period of 14-28 days. It was histologically revealed that Aspirin can induced gastric injury and Turmeric protect gastric layers. There is need for more research work on the protective effect of Turmeric on gastric layers against gastric injury.

DOI: <https://dx.doi.org/10.4314/jasem.v26i10.3>

**Open Access Policy:** All articles published by **JASEM** are open access articles under **PKP** powered by **AJOL**. The articles are made immediately available worldwide after publication. No special permission is required to reuse all or part of the article published by **JASEM**, including plates, figures and tables.

**Copyright Policy:** © 2022 by the Authors. This article is an open access article distributed under the terms and conditions of the **Creative Commons Attribution 4.0 International (CC-BY- 4.0)** license. Any part of the article may be reused without permission provided that the original article is clearly cited.

**Cite this paper as:** AKEREDOLU, F. F; OLADELE, A. A; EKUNDINA, V. O. (2022). Assessment of Protective Effect of Turmeric on Aspirin Induced Gastric Injury on Wistar Rats. *J. Appl. Sci. Environ. Manage.* 26 (10) 1637-1639

**Keyword:** Turmeric; Aspirin; Stomach; Histology; Histochemistry

Turmeric (from *Zingiberaceae* family) is highly regarded as a universal panacea in the herbal medicine with a wide spectrum of pharmacological activities, such as antioxidant activity, cardiovascular and anti-diabetic effects, inflammatory and edematous disorders, gastrointestinal effects, anti-cancer effect, antimicrobial activity, hepatoprotective and renoprotective (Verma, 2018). Due to its ability to interact with various molecular targets, turmeric inhibits inflammatory cell proliferation and angiogenesis, as well as acts chemopreventively. These properties are associated with the regulation of proinflammatory cytokines, nitric oxide synthase (iNOS) enzymes, cyclooxygenase-2 (COX-2), lipoxygenase, xanthine oxidase, and reduction in malondialdehyde (MDA) (Adibian *et al.*, 2019). Aspirin is part of a group of medications called nonsteroidal anti-inflammatory drugs (NSAIDs), but differs from them in the mechanism of action. Due to physico-chemical characteristics, aspirin may cause injury to mucosal lining and development of peptic

ulcer disease and, if complicated, it can perforate and cause local hemorrhage (Cryer and Mahaffe, 2014).

### MATERIALS AND METHOD

**Experimental rats and chemicals:** The Wistar rats weighing 180-200g were purchased and were housed in a temperature controlled room at 25°C ± 1°C under standard condition of hanging cages and were acclimatized for a week prior to the experiment (Smith *et al.*, 2018). **Histological procedure:** The stomach of rats were removed and wash to remove blood and fixed in 10% formal saline for 48 hours. They were dehydrated through graded series of ethanol and embedded in paraffin wax. Blocks were prepared and sectioned at a thickness of 6-7 micron using microtome the sections were deparaffinised in xylene and stained with haematoxylin-eosine and Alcian Blue for the demonstration of Mucins (Ali *et al.*, 2012). Changes induced by Aspirin administered and protective effects of Turmeric were analysed and photographed under photomicroscope along the control group.

\*Corresponding Authors Email: [florry.akeredolu@gmail.com](mailto:florry.akeredolu@gmail.com); [akeredoluff@pg.abuad.edu.ng](mailto:akeredoluff@pg.abuad.edu.ng)

**Table 1:** Research protocol

Group	No. of Rats	Duration (days)	Dosage
Control	8	14	1.5ml d/w
Aspirin	8	14	Aspirin 300mg/kg
Aspirin-Turmeric	8	14	Aspirin 300mg/kg and Turmeric 100mg/kg
Aspirin-Turmeric	8	14	Aspirin 300mg/kg and Turmeric 150mg/kg
Aspirin - Omeprazole	8	14	Aspirin 300mg/kg and Omeprazole 30mg/kg
Aspirin Withdrawal	8	28	-

## RESULTS AND DISCUSSION

The layers of the stomach were well arranged and visible as mucosa layer, sub mucosa layer and muscularis propria layer.

The mucosa layer of the stomach of the control rats showed normal histology with intact epithelial lining and gastric pits. The histological alteration in the stomach of wistar rats administered with 300mg/kg Aspirin, sections of the stomach showed many changes represented by distortions in the lining epithelial layer, the appearance of congestion in the muscular layer, with the occurrence of vasodilation compared with control group.

Furthermore, histological findings showed enlargement of the submucosa and muscularis propria layers in the aspirin treated group. Aspirin administration also resulted in erosion of the epithelia lining compared to control group. Gastric mucosal integrity is normally maintained by defense mechanisms. Several studies have reported a strong association between gastric mucosal damage and aspirin intake. Gastrointestinal ulceration and localized mucosal inflammation are among the most serious gastrointestinal complications (Goldstein and Cryer, 2015).

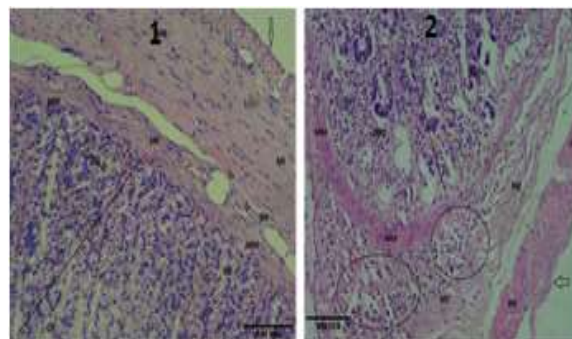
Histopathological examination of gastric mucosa treated with Turmeric and omeprazole revealed a normal glandular pattern with mild submucosal edema and low leukocyte infiltration. The regeneration of gastric mucosa following the administration of Turmeric and omeprazole may be associated with the inhibition of oxidative stress.

The layers of the stomach were well arranged and visible as mucosa layer, submucosa layer and muscularis propria layer. The mucosa layer of the stomach of the control rats showed normal histology with intact epithelial lining and gastric pits (plate 1). Inflammation was observed in the mucosa and

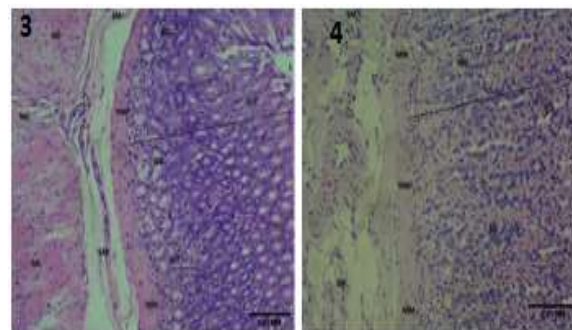
submucosa layers of both aspirin treated group as well as ulceration of epithelia lining and mucosa layer in this group (plate 2). There was moderate erosion of the epithelial extending to the submucosa with hemorrhage at the sub mucosal layer; there was moderate infiltration of inflammatory cells in Aspirin 300mg/kg +Turmeric 100mg/kg treated group (plate 3). There was mild erosion with infiltration of inflammatory cells of Aspirin 300mg/kg +Turmeric 150mg/kg treated group (plate 4).

There was moderate mucosal erosion with infiltration of inflammatory cells at the submucosa level of Aspirin 300mg/kg+ Omeprazole 30mg/kg treated group (plate 5). The gastric glands (GG) and gastric pit appear unremarkable in Micrograph of stomach of Recovery group (plate 6).

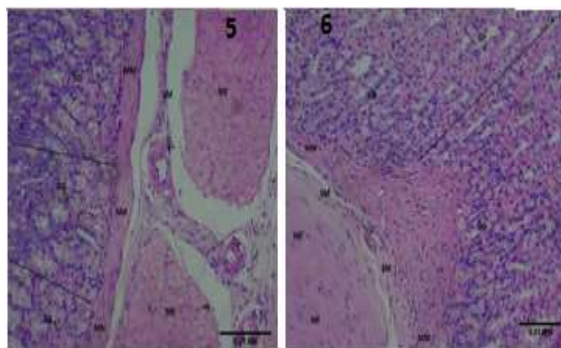
Alcian blue Section shows moderately positive (++) of Alcian blue (plate 7). Section shows weakly positive (+) of Alcian blue (Plate 8), Section shows moderately positive (++) of Alcian blue (plate 9), Section shows moderately positive (++) of Alcian blue (Plate 10), Section shows moderately positive (++) of Alcian blue (11) and Plate 12 Section shows weakly positive (++) of Alcian blue (pH2.5) expression on the mucous secreting cells within the gastric mucosa.



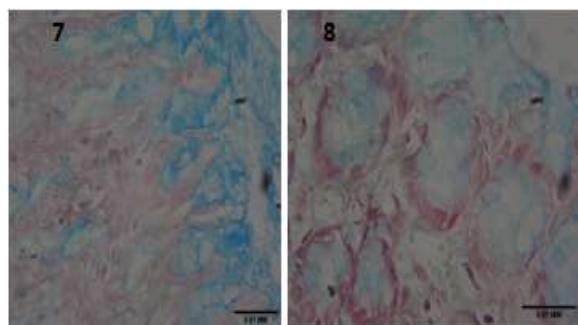
**Plate 1:** Micrograph of stomach of control group (H & E Stain X100). **Plate 2:** Micrograph of stomach of Aspirin treated group (H & E Stain X100).



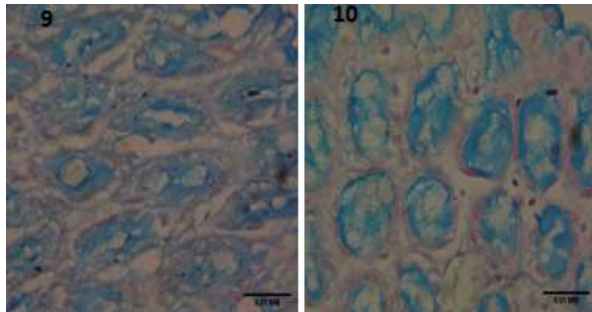
**Plate 3:** Micrograph of stomach of Aspirin 300mg/kg +Turmeric 100mg/kg treated group (H & E Stain X100). **Plate 4:** Micrograph of stomach of Aspirin 300mg/kg +Turmeric 150mg/kg treated group.



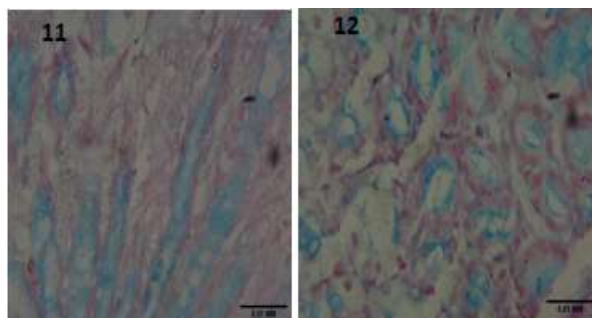
**Plate 5:** Micrograph of stomach of Aspirin 300mg/kg+ Omeprazole 30mg/kg treated group (H & E Stain X100). **Plate 6:** Micrograph of stomach of Recovery group (H & E Stain X100).



**Plate 7:** Micrograph of stomach of control group. (Alcian Blue Stain X400). **Plate 8:** Micrograph of stomach of Aspirin 300mg/kg treated group (Alcian Blue Stain X400)



**Plate 9:** Micrograph of stomach of Aspirin 300mg/kg+ Turmeric 100mg/kg treated group (Alcian Blue Stain X400). **Plate 10:** Micrograph of stomach of Aspirin 300mg/kg + Turmeric 150mg/kg treated (Alcian Blue Stain X400)



**Plate 11:** Micrograph of stomach of Aspirin 300mg/kg + Omeprazole 30mg/kg treated group (Alcian Blue Stain X400). **Plate 12:** Micrograph of stomach of Recovery group (Alcian Blue Stain X400)

**Conclusion:** In conclusion, the present study further confirms that oral aspirin administration causes ulcerative changes. These findings suggest that oral administration of aspirin reduces the mucosa surface area of stomach and duodenum. Hence, it is recommended that aspirin be administered with caution and if daily intake becomes a necessity, it will be prudent to accompany such administration with drugs that could prevent injuries to the gastrointestinal mucosa. The results of the present study suggest that turmeric can be used as a dietary supplement in order to prevent negative effects of aspirin to some extent.

**Acknowledgements:** I really appreciate God, my sufficiency who assisted me to complete this research. This achievement would have been a mirage if not for Him. To my supervisors, Professor Oladele, AA and Dr. Ekundina, VO thanks for your kindness, advice and encouragement.

## REFERENCES

- Adibian, M; Hodaei, H; Nikpayam, O; Sohrab, G; Hekmatdoost, A; Hedayati, M (2019). The effects of curcumin supplementation on high-sensitivity C-reactive protein, serum adiponectin, and lipid profile in patients with type 2 diabetes: A randomized, double blind, placebo-controlled trial. *Phyto. R.* 33, 13741383.
- Ali, U; Nagi, AH; Naseem, N; Ullah, U; Nagi, AH; Naseem, N; Ullah, E; Ali, U; Nagi, AH; Naseem, N; Ullah, E (2012). Mucin histochemistry in tumours of colon. *J. Cytol. Histol. H;* 3(7):163.
- Cryer, B; Mahaffey, K (2014). Gastrointestinal ulcers, role of aspirin, and clinical outcomes: pathobiology, diagnosis, and treatment. *J. Multidisc. Health.* 7:137.2.
- Goldstein, L; Cryer, B (2015). Gastrointestinal injury associated with NSAID use: A case study and review of risk factors and preventative strategies. *Drug, Healthcare and Patient Safety,* 7, 31–41.
- Smith, A; Clutton, R; Lilley, E., Hansen, K., Brattelid, T. (2018). PREPARE: Guidelines for planning animal research and testing. *Lab. Ani.* 52, 135-141.
- Verma, R (2018). Medicinal properties of turmeric (*Curcuma longa* L.): A review. *Intern. J. of Chem. Stud.* 6:1354-1357.