



Toxic Effect of *Abrus Precatorius* Seed Aqueous Extract in the Liver of Wistar Rats

SUNDAY, RM

Medical Biotechnology Department, National Biotechnology Development Agency, Abuja, Nigeria
*Email: reetersun@gmail.com; Tel: +234 7038571077

ABSTRACT: *Abrus precatorius* seed is used in traditional medicine for the treatment of numerous diseases which include hepatitis, fever and asthma. The effect of *Abrus precatorius* seeds aqueous extract in the liver of Wistar rats was investigated in this study. The median lethal dose (LD₅₀) of *Abrus precatorius* seeds aqueous extract was determined via intraperitoneal (i.p.) route of administration before screening the effect of the extract on the liver. In this study, age matched Wistar rats (180-190 g) were grouped into four with five rats per group. The treatment groups were administered 0.025 mg/kg, 0.05 mg/kg and 0.10 mg/kg aqueous extract of *A. precatorius* seeds (i.p) while the control group was administered 10 ml/kg distilled water (i.p) daily for fourteen days. At the end of the study, the activity of enzymes (alanine transaminase [ALT], aspartate transaminase [AST] and alkaline phosphatase [ALP]) present in the serum and liver homogenate was evaluated. The relative organ (liver) weight (ROW) and the effect of the extract on the histology of the liver were also determined. The results showed that the LD₅₀ of *A. precatorius* seed was 0.35 mg/kg (i.p). *A. precatorius* seed extract caused an increase in ROW and in the activity of enzymes (ALT, AST and ALP) at 0.05 and 0.10 mg/kg when compared with the control. Pathological changes were observed in rat liver of treatment groups. In conclusion, the aqueous extract of *A. precatorius* seeds could be toxic to the liver and caution should be exercised in its use in traditional medicine.

DOI: <https://dx.doi.org/10.4314/jasem.v26i2.23>

Open Access Article: (<https://pkp.sfu.ca/ojs/>) This an open access article distributed under the Creative Commons Attribution License (CCL), which permits unrestricted use, distribution, and reproduction in any medium, provided the original work is properly cited.

Impact factor: <http://sjifactor.com/passport.php?id=21082>

Google Analytics: <https://www.ajol.info/stats/bdf07303d34706088ffffbc8a92c9c1491b12470>

Copyright: © 2022 Sunday

Keywords: *Abrus precatorius*, seeds, liver, enzymes, toxic

There is a wide spread increase in the use of medicinal plants as herbs for the management and treatment of diseases in recent years without considering their side effects. This has led to the increase in studies that have to do with the effects and safety of medicinal plants used for the treatment of various diseases. Many of these studies were carried out preferably on mammals over long-term or short-term period involving detailed biochemical and organ system analyses (Ekor *et al.*, 2010; Zhou *et al.*, 2013). Toxic compounds are often concentrated in specific parts of the plant (Roberts and Smith, 2004; Ekor, 2013). In some plants, the toxins are located in the fruits or seeds, in others, the toxin may be contained in the leaves or roots (Roberts and Smith, 2004). Medicinal plants used mostly in traditional medicine have strong scientific evidence as regards their biological activities. However, most of these plants with medicinal properties lack clinical data in support of the efficacy and safety of the plant after use for treatment of diseases (Ekor *et al.*, 2010; Kasilo and Trapsida, 2011; Raynor *et al.*, 2011). There are reports from literature that ingestion of a toxic

plant substance can cause a variety of symptoms including, gastrointestinal disturbances (vomiting, diarrhea and constipation), headache, insomnia, liver or kidney damage (Edgar *et al.*, 2011; Dunnick and Nyska, 2013; Ekor, 2013). Studies have also shown that the dose and route of administration are some of the important criteria for determining the toxicity of a particular substance (Bernard and Clovis, 2014; Dunnick and Nyska, 2013; Ekor, 2013). Thus, it is important to carry out toxicity studies on medicinal plants in order to ascertain its safety after ingestion. *Abrus precatorius* Linn (Fabaceae) is a slender, annual climbing shrub. It grows in tropical climates such as West Africa, India, Sri Lanka, Thailand, the Philippine Islands, South China and North America. The seeds are scarlet-red in color and it has a peculiar, dark spot at the hilum. The seeds are commonly known as Rosary pea, crab's eye and Oju ologbo in south-western Nigeria (Sunday *et al.*, 2013a). The leaves and roots have sweet taste and they are traditionally used to cure fever, stomatitis, asthma and bronchitis (Kirtikar *et al.*, 1987). Gallic acid, glycyrrhizin and

*Email: reetersun@gmail.com; Tel: +234 7038571077

trigonelline are potent antioxidants present in the plant (Lakshmi *et al.*, 2006). In China the herb of *A. precatorius* is used as a folk-medicine for the treatment of bronchitis, laryngitis and hepatitis because of their platelet inhibiting activity (Kuo *et al.*, 1995). *Abrus precatorius* have been reported to have anti-arthritis effect (Georgewill and Georgewill, 2010), anti-diabetic property (Monago and Alumanah, 2005) and antimicrobial activity (Adelowotan, 2008). In this study, the potential hepatotoxic effect of aqueous extract of *Abrus precatorius* seeds in the liver of Wistar rats was investigated due to its use in traditional medicine.

MATERIALS AND METHODS

The animal experiments were performed according to the approved guidelines of Obafemi Awolowo University research ethics committee.

Plant collection and extraction: Dry seeds of *A. precatorius* plant, were obtained from a local market in Ile-Ife (Osun state) and identity of the plant was confirmed by Mr. G. Ibhanebhor of the Department of Botany, Faculty of Biological Sciences, Obafemi Awolowo University, Nigeria. A specimen (voucher number 16282) was subsequently deposited at the Herbarium, Obafemi Awolowo University, Ile-Ife, Nigeria. Dried seeds of *A. precatorius* were powdered, macerated in distilled water overnight and then filtered using muslin cloth and cotton wool in funnel. The filtrate was then concentrated into a solid paste *in vacuo* at 45°C using a rotary evaporator (Sunday *et al.*, 2013a). The solid paste was then freeze dried and stored in a desiccator until it was needed for use.

Animals: Twenty age matched Wistar rats of both sexes weighing between 150-200g were obtained from Animal House, Department of Pharmacology, Faculty of Pharmacy, Obafemi Awolowo University, Ile-Ife, Nigeria. They were kept in well ventilated polypropylene cages with steel grid floors and were given standard feed (produced by Ola Dokun, Ibadan, Nigeria) and water *ad libitum*. They were acclimatized with the environment at ambient temperature under natural day light/night conditions for two weeks before the start of the experiment.

Acute toxicity studies (Median Lethal Dose Determination): The study was carried out using the method of Lorke (1983). In the first phase, nine Wistar rats were randomly divided into three groups of three rats each. Each group (1-3) was administered 10, 100 and 1000 mg extract/kg body weight via intraperitoneal (i.p.) route. The rats were kept under laboratory ambient conditions and observed for signs of toxicity which include but not limited to respiratory

distress, change in body weight and mortality for the first critical four hours and there after daily for fourteen days. In the second phase of the study, lower doses were administered to another fresh set of three groups of three rats each because 10 mg/kg caused 100% mortality. The animals were examined for gross behavioural changes and mortality. At the end of the study the median lethal dose (LD₅₀) was calculated (Lorke, 1983).

Determination of biochemical parameters in Wistar rat serum and liver homogenate: The rats were randomly sorted into four groups of five rats per group. The treatment groups were administered 0.025 mg/kg, 0.05 mg/kg and 0.10 mg/kg aqueous extract of *A. precatorius* seeds via intraperitoneal (i.p) route while the control group was administered 10 ml/kg distilled water (i.p) daily for fourteen days. On the 15th day of the experiment, the rats one at a time were sacrificed under diethyl ether anaesthesia. Blood was collected by cardiac puncture into plain bottles and the liver of rats was immediately harvested. A section of the liver was taken and used for histological analysis while the remaining section was homogenized with sucrose solution [1g of liver/10ml of sucrose solution] (Alabi *et al.*, 2013; Sunday *et al.*, 2019). The blood collected in plain bottles was allowed to stand for 5 minutes. Thereafter, centrifuged at 2500 rpm for 25 minutes and the serum were collected and used for analysis of biochemical parameters which include alanine transaminase [ALT] (Reitman and Frankel, 1957), aspartate transaminase [AST] (Schmidt and Schmidt, 1963) and alkaline phosphatase [ALP] (Englehardt, 1970) levels. The homogenized liver was centrifuged and the supernatant fraction was collected and used for evaluation of enzyme activity (ALT, AST and ALP).

Histology: The sections of the liver was placed in a tissue cassette and fixed in 10% buffered formalin. The tissues were then processed routinely and were embedded in paraffin wax. Histological sections were cut at 5-6 µm and stained with routine Haematoxylin and Eosin for microscopic assessment (Desmet, 2003). The relative organ to body weight ratio (ROW) of each rat was calculated as follows:

$$ROW = \frac{AOW}{BWS} \times 100$$

Where AOW = absolute organ weight; BWS = Body weight of rat on sacrifice day

Statistical analysis: All quantitative data were expressed as the mean ± standard error of mean (SEM). Statistical analysis was carried out using one way analysis of variance (ANOVA) and significant

difference between means was assessed by Bonferroni t-test at 95% level of significance using Primer (version 3.01).

RESULTS AND DISCUSSION

Median Lethal Dose (LD₅₀): The median lethal dose for *Abrus precatorius* seeds aqueous extract in Wistar rats was 0.35 mg (i.p.)

Effect of *Abrus precatorius* aqueous seed extract on liver enzyme activity: The extract caused a significant ($P < 0.05$) increase in aspartate transaminase, alanine transaminase and alkaline phosphatase enzymes activity in the serum and liver homogenate of Wistar rats at 0.05 mg/kg and 0.10 mg/kg when compared with the control (Figure 1 and Figure 2).

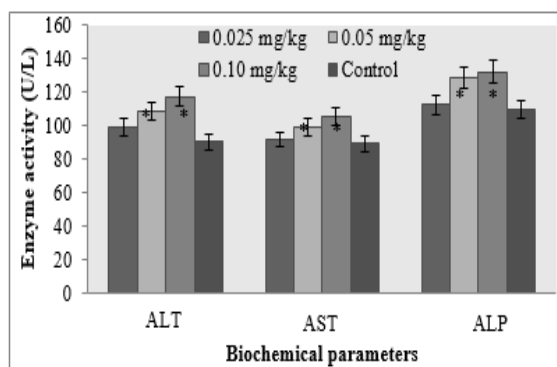


Fig 1: Effect of *A. precatorius* seed extract on some enzymes in Wistar rat liver homogenate. Values are mean \pm SEM; n = 5; Alanine transaminase (ALT), aspartate transaminase (AST) and alkaline phosphatase (ALP); *Significantly different from control at $P < 0.05$

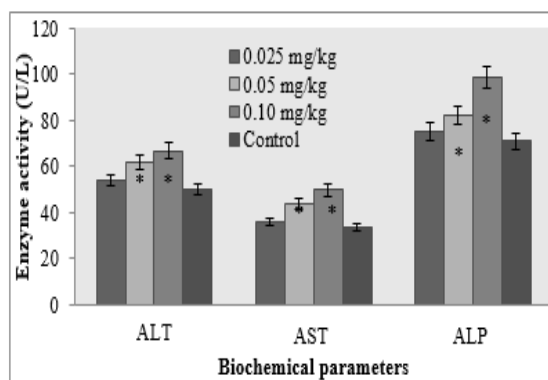


Fig 2:Effect of *A. precatorius* seed extract on enzymes present in Wistar rats serum. Values are mean \pm SEM; n = 5; Alanine transaminase (ALT), aspartate transaminase (AST) and alkaline phosphatase (ALP); *Significantly different from control at $P < 0.05$

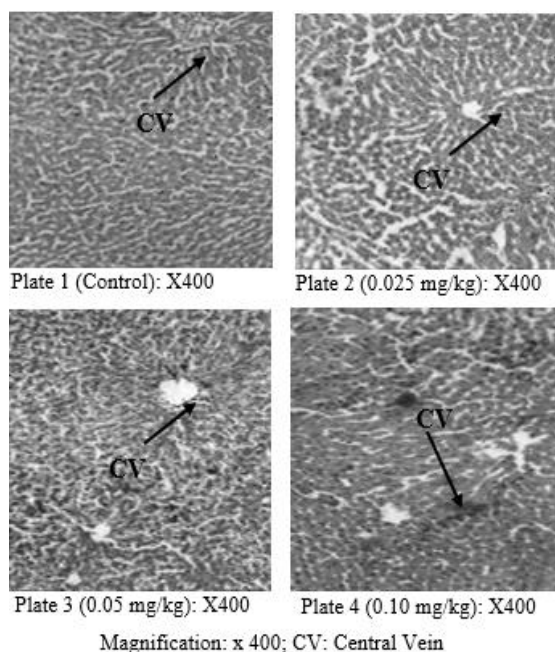
Effect of *Abrus precatorius* aqueous seed extract on relative organ weight: The aqueous extract of *A. precatorius* seed caused a significant ($P < 0.05$) increase in relative organ weight at 0.05 mg/kg and 0.10 mg/kg when compared with the control (Table 1).

Table 1: Relative Organ weight

Groups	Control	0.025 mg/kg	0.05 mg/kg	0.10 mg/kg
Liver	2.25 \pm 0.18	2.20 \pm 0.14	3.39 \pm 0.16*	3.50 \pm 0.23*

Values are mean \pm SEM; n = 5 *Significantly different from control at $P < 0.05$

Effect of *Abrus precatorius* aqueous seed extract on the histology of Wistar rats liver: The untreated group (control) showed well outlined liver histoarchitecture (Plate 1) around the central vein while that of the treatment groups were distorted. *Abrus precatorius* seeds extract at 0.025 mg/kg the hepatocytes appear laden (plate 2) and 0.05 mg/kg, the histoarchitectural disruption of the liver is pronounced, sinusoids appear to be collapsing and necrotic cell regimes are identifiable (plate 3). At 0.10 mg/kg *A. precatorius* seeds extract the sinusoids of the liver are almost completely collapsed, the whole hepatic tissue appears to have undergone necrosis and there is total disruption of the histoarchitecture of the liver (plate 4).



Toxicological studies have to do with the symptoms and detection of poisoning, especially by chemical substances found in plants (Ekor, 2013; Zhou *et al.*, 2013). Toxicity can result into adverse cellular, biochemical or macromolecular changes which include skin irritation, impaired motor coordination, organ structure changes or death (Zhou *et al.*, 2013; Ekor, 2013, Bernard and Clovis, 2014). The median lethal dose (LD₅₀) obtained was 0.35 mg (i.p.) and this indicates that *Abrus precatorius* seed extract is toxic in rodent model. This confirms previous reports that seeds of *A. precatorius* are toxic and causes cell death due to the presence of a compound known as abrin

(Anam, 2001). In this study, *A. prectorius* seed extract caused a dose dependent significant ($P < 0.05$) increase in serum and liver homogenate levels of alanine transaminase (ALT), aspartate transaminase (AST) and alkaline phosphatase (ALP) enzymes at 0.05 mg/kg and 0.10 mg/kg when compared with the control (Figure 1 and Figure 2). Significant increases in the level of these enzymes in the serum signify that there might be a leakage of these enzymes from the liver due to liver damage (Nyblom *et al.*, 2004). Previous toxicological studies carried out on the aqueous extract of *Abrus precatorius* seeds (Sunday *et al.*, 2013a) and leaves (Adedapo *et al.*, 2007) reported that the extract caused an increase in levels of some biochemical and haematological parameters. Toxicity studies carried out *Abrus precatorius* seeds aqueous extract also reported that it caused a decrease in body weight, feed intake and water intake (Sunday *et al.*, 2013a). There was no pathological change in the liver of rats in the group that was not treated with the extract (Plate 1) but progressive and dose dependent changes were observed in the liver of animals that were administered aqueous extract of *A. precatorius* seed (Plate 2, 3 and 4). There are reports from literature that *A. precatorius* seeds aqueous extract caused degenerative changes in the histo-architecture of the kidney, lungs and intestine of Wistar rats (Sunday *et al.*, 2013b). Aqueous extract of *A. precatorius* leaves have been reported to cause testicular degeneration and sperm cell reduction in Albino rats (Adedapo *et al.*, 2007). There are reports from literature that *A. precatorius* seeds aqueous extract caused degenerative changes in the histo-architecture of the kidney, lungs and intestine of Wistar rats (Sunday *et al.*, 2013b). Aqueous extract of *A. precatorius* leaves have been reported to cause testicular degeneration and sperm cell reduction in Albino rats (Adedapo *et al.*, 2007).

Conclusion: In conclusion, these results indicate that intraperitoneal administration of aqueous seed extract of *A. precatorius* could be toxic to the liver hence; caution needs to be taken in its use in traditional medicine.

REFERENCES

- Adedapo, AA; Omoloye, OA; Ohore, OG (2007). Studies on the toxicity of an aqueous extract of the leaves of *Abrus precatorius* in rats. *Onderst. J. Vet. Res.* 74:31-36.
- Adelowotan, O (2008). The in-vitro antimicrobial activity of *Abrus precatorius* (L) fabaceae extract on some clinical pathogens. *Niger. Postgrad. Med. J.* 15 (1): 32-37.
- Alabi, MA; Sunday, RM; Olowokere, T; Kareem, FA; Osanaiye, F (2012). Effect of bitters on the body weight, lipid profile, catalase and lipid peroxidation in experimental animals. *J. Med. Sci.* 13(1): 62-66.
- Anam, EM (2001). Antiinflammatory activity of compounds isolated from the aerial parts of *Abrus precatorius* (Fabaceae). *Phytomed.* 8 (1): 24-27.
- Bernard, KF; Clovis, F (2014). Adverse drug reactions in some African herbal medicine: Literature review and stakeholders' interview. *Integrat. Med. Res.* 3(3): 126-132.
- Desmet, VJ (2003). Liver tissue examination. *J. Hepa.* 39(1): 43-49.
- Dunnick, JK; Nyska, A (2013). The toxicity and pathology of selected dietary herbal medicines. *Toxicol. Pathol.* 41: 374 – 386.
- Edgar, JA; Colegate, SM; Boppre, M; Molyneux, RJ (2011). Pyrrolizidine alkaloids in food: a spectrum of potential health consequences. *Food Addit. Contam. Part A Chem. Anal. Control Expo. Risk Asses.* 28: 308 – 324.
- Ekor, M; Osonuga, OA; Odewabi, AO; Bakre, AG; Oritogun, KS (2010). Toxicity evaluation of Yoyo 'Cleanser' bitters and fields Swedish bitters herbal preparations following sub-chronic administration in rats. *Am. J. Pharmacol. Toxicol.* 5: 159-166.
- Ekor, M (2013). Growing use of herbal medicines: issues relating to adverse reactions and challenges in monitoring safety. *Front. Pharmacol.* 4: 177.
- Englehardt, A (1970). Assessment of Liver enzymes: plasma alkaline phosphatase. *Aerz. Lab.* 16: 42 (s).
- Georgewill, O; Georgewill, U (2010). Anti-arthritis activity of *Abrus precatorius* in albino rats. *Intern. J. Lab. Med.* 4(1): 15 – 34.
- Kasilo, OM; Trapsida, JM (2011). Decade of African traditional medicine, 2001-2010. *Afri. Health Mon. (Special Issue)* 14: 25-31.
- Kirtikar, KR; Basu BD. (1987). Indian medicinal plants. 2nd edn. Dehradun: International Book Distributor, pp. 763-767.

- Kuo, SC; Chen, SC; Chen, LH (1995). Potent antiplatelet, anti-inflammatory and anti-allergic iso-flavanquinones from the roots of *Abrus precatorius*. *Planta Med.* 61 (4):307- 312.
- Lakshmi, P; Tajdar, H; Jehangir, T; Sultana, S (2006). The effect of gallic acid on renal biochemical alterations in male rats. *Hum Toxicol.* 25: 523 – 529.
- Lorke, D (1983). A new approach to practical acute toxicity testing. *Arch. Toxicol.* 54: 275–287.
- Monago, CC; Alumanah, EO (2005). Antidiabetic Effect of Chloroform -Methanol Extract of *Abrus Precatorius* Linn Seed in Alloxan Diabetic Rabbit. *J. Appl. Sci. Environ. Manage.* 9 (1): 85 – 88.
- Nyblom, H; Berggren, U; Balldin, J; Olsson, R (2004). "High AST/ALT ratio may indicate advanced alcoholic liver disease rather than heavy drinking". *Alc. Alcohol.* 39 (4): 336–339.
- Raynor, DK; Dickinson, R; Knapp, P; Long, AF; Nicolson, DJ (2011). Buyer beware? Does the information provided with herbal products available over the counter enable safe use? *BMC Med.* 9: 94.
- Reitman, S; Frankel, S (1957). A colorimetric method for the determination of serum glutamic oxalacetic and glutamic pyruvic transaminases. *Americ. J. Clinic. Pathol.* 28: 56-63.
- Roberts, LM; Smith, DC (2004). Ricin: the endoplasmic reticulum connection. *Toxicon.* 44 (5): 469–472.
- Schmidt, E; Schmidt, FW (1963). Determination of serum GOT and GPT activities. *Biologica et Clinica.* 3: 1-52.
- Sunday, RM; Ilesanmi, OR; Obuotor, EM (2013a). Acute and Subacute Toxicity of Aqueous Extract of *Abrus Precatorius* Seeds in Wistar Rats. *Intern. J. Pharmacol.* Volume 11 Number 1.
- Sunday, RM; Ilesanmi, OR; Alabi, MA; Osanaiye, FG; Olowokere, T; Otunla, TA (2013b). The effect of *Abrus precatorius* aqueous seed extract on the histology of kidneys, lungs and intestines of Wistar rats. *J. Pharmacol. Toxicol.* 8(2): 67 – 72.
- Sunday, RM; Obuotor, EM; Anil, K (2019). Antioxidant and Antidiabetic Properties of *Mimosa pudica* Seeds in Streptozotocin-induced Diabetic Wistar rats. *Asia.J. Biotechnol.* 12 (1): 1 – 8.
- Zhou, J; Ouedraogo, M; Qu, F; Duez, P (2013). Potential genotoxicity of traditional Chinese medicinal plants and phytochemicals: an overview. *Phytother. Res.* 27 (12): 1745-1755.