

Research Article

Alterations of selected biomarkers and reproductive tissues histoarchitecture in offspring of artemether-lumefantrine treated lactating dams.

D.H. Adeyemi^{*1}, A.M. Lawal², Y.O. Akinlaja¹, O. P. Morakinyo¹, A.A. Aderanti³, I.P. Oyeyipo¹

Departments of Physiology, ¹Faculty of Basic Medical Sciences, College of Health Sciences, Osun State University, Osogbo, Osun State, Nigeria, ²Faculty of Basic Medical Sciences, Ekiti State University, Ekiti, Nigeria and ³Medical Laboratory Sciences, Faculty of Basic Medical Sciences, Ladoke Akintola University of Technology, Ogbomoso, Nigeria.

Keywords:

Artemether-lumefantrine, antioxidant, hormone, lactation, reproductive toxicity

ABSTRACT

Background: Evidence from previous studies suggests that most antimalarial agents adversely affect reproductive functions. The deleterious effects of artemether-lumefantrine on reproductive functions have also been documented but there is dearth of knowledge on the generational reproductive outcomes during lactation. Hence, we investigated the reproductive outcomes in offspring of dams treated with artemether-lumefantrine during lactation. **Methods:** Ten lactating dams were randomly assigned into two groups (n=5) and treated as follows: Group I (control) received distilled water (1 ml/kg BW, p.o.) while Group II received artemether-lumefantrine (4/24 mg/kg BW, p.o.) for seven (7) consecutive days immediately after parturition. Pups were thereafter weaned and later given rat chow with water *ad libitum* daily, before they were euthanized at postnatal day 90 (PND 90). **Results:** The results showed that although the anti-malarial drug caused a significant decrease in serum testosterone and estrogen levels in offspring of the treated group, relative to the control group; however, follicle stimulating and luteinizing hormones, sperm motility, sperm viability and sperm count were not significantly different between the two groups. Moreover, only testicular catalase activity was significantly decreased with a concomitant interstitial edema and defective histoarchitectural presentation in the testis and ovary. Nevertheless, the level of malondialdehyde was unaltered in both testes and ovarian tissues of the treated group as compared with control. **Conclusion:** Therefore, this study suggests that exposure to artemether-lumefantrine during lactation could disrupt steroidogenic functions in both testicular and ovarian tissues of offspring in adult life.

© Copyright 2021 African Association of Physiological Sciences -ISSN: 2315-9987. All rights reserved

INTRODUCTION

Till date, malaria remains one of the endemic diseases threatening human health in Africa. Epidemiological surveys have shown an astronomic increase in the numbers of new cases of malaria infection particularly in Africa (W.H.O., 2019). The high susceptibility of pregnant women and nursing mothers to malaria infection is of great concern and has pose a serious public health burden (Desai *et al.*, 2007). This could

perhaps be attributed to reduced immunological functions that accompanies pregnancy thus resulting in complications such as low birth weight, premature delivery and other maternal complications notably anaemia in pregnancy, acute lung injury, severe hypoglycemia among others (Rogerson *et al.*, 2007). Globally, scores of millions of pregnant women are prone to malaria infection yearly while in Sub-Saharan Africa maternal malaria is on the sharp increase yearly (Hartman *et al.*, 2010). Specifically, five species of the *Plasmodium* group have been identified to cause malaria infections in humans. Notably amongst them is *Plasmodium falciparum* that adversely affects humans through the bites of female Anopheles mosquito

*Address for correspondence:

Email: bobdare2013@gmail.com

Tel. +234-706-390-3339

(Greenwood *et al.*, 2008). Although, there has been significant achievement in reducing the global prevalence of malaria, particularly in Africa recently (Kakuru *et al.*, 2016), but pregnant women and nursing mothers still remain at high risk with over 50 % of women in high transmission areas having *P. falciparum* detected in peripheral blood at presentation to antenatal and postnatal care respectively (Madanitsa *et al.*, 2016). Evidence abounds that there is high prevalence rate of malaria infection among nursing mothers as compared to their other female counterparts (Ataide *et al.*, 2014). It is therefore unsurprising that those living in tropical areas as well as low- or poor-income countries like Nigeria are predisposed to malaria (Rijken *et al.*, 2012). Meanwhile, the World Health Organization recommends a combination of use of insecticide treated bed nets to prevent exposure to mosquitoes as well as the use of drugs in the prevention and treatment of malaria (W.H.O. 2018). The classes of antimalarial drugs to treat or combat malaria infection include quinolines, antifolates, hydroxynaphthaquinones and artemisinin derivatives amongst others. Based on WHO recommendation, the use of artemisinin-based combination therapy (ACT) remains the first line regimen for combating the protozoan infection (Ward *et al.*, 2007).

Owing to the prevalence of malaria cases and the rise in the use of antimalarial drugs globally, several studies have investigated the effects of some antimalarial drugs on various organ systems. Artesunate administration (25-300 mg/kg/day) have been reported to induce neurotoxicity such as selective damage to brainstem centers, gait disturbances (Nontprasert *et al.*, 2002), loss of spinal cord and pain response mechanisms in mice and rats (Genovese *et al.*, 1998), as well as other complications in the cardiovascular system (Marrelli & Brotto, 2016). The deleterious effects of these drugs on reproductive systems have also been documented (Cosentino *et al.*, 1990; Izunya *et al.*, 2010). Most antimalarial agents have been associated with reproductive toxicity. Chloroquine was reported to reduce sperm motility and consequently fertility as evidenced by reduction in the average number of fetuses of cohabited female rats (Orisakwe *et al.*, 2003). Adeeko & Dada (1998) established the adverse effects of halofantrine on sperm parameters. Pyrimethamine was reported to cause spermatogenic arrest and consequently male infertility in a dose-dependent manner (Cosentino *et al.*, 1990) while Raji *et al* (2005) revealed that artemether (2.9 mg/kg body weight) treatment caused a significant reduction in the progressive sperm motility, viability, count and serum testosterone levels in a dose-dependent manner during an acute administration of the drug in male rats. The effects of antimalarial agents on female

reproductive system have also been widely reported. Artemisinin was reported to cause hormonal imbalance and oxidative damage in erythrocyte and uterus but spared ovaries of rats (Farombi *et al.*, 2015). Artesunate was shown to significantly reduce serum progesterone concentration and degenerate the decidual cells as well as fetus of treated pregnant rats. Artemether (16 mg/kg body weight) caused a significant reduction in the placental and birth weights of the fetuses (Lou and Zhou, 2001).

Accumulating evidence has shown that Artesunate induces significant embryo-fetal toxicity thus resulting to embryo deaths and malformations (Clark, 2009; Rath *et al.*, 2010). Furthermore, plethora of studies have suggested that antimalarial drugs have different mechanisms of reproductive toxicities among which include through direct inhibition of serum and plasma reproductive hormones (Cosentino *et al.*, 1990); depletion of hormones at the target levels (Akinsomisoye and Raji, 2011); decrease in weights of reproductive organs and probably distortion from the central nervous system (Ukwenya *et al.*, 2010) among others.

Apparently, it is clear that the concept of fetal programming is simply not the effect of genes passed on through generations, howbeit it is believed to be the phenotype of offspring subjected to a variety of intrauterine and postnatal challenges that occurs during critical windows of development. Altered postnatal physiological functions have also been observed in several studies arising from maternal feeding and treatments, dietary manipulations of specific micronutrients, among others. Artemisinin and its derivatives are regularly prescribed to patients but their safety during lactation is still unknown. In spite the growing knowledge on the adverse effects of ACT during pregnancy on the mother and fetuses, little is known on its reproductive effects relating to testicular and ovarian functions in offspring sequel to maternal exposure during lactation. Therefore, this study was designed to investigate the testicular and ovarian functions in male and female offspring of dams treated with artemether-lumefantrine during lactation with a view of having insight to the programming effects of offspring of animals exposed during this critical period.

MATERIALS AND METHODS

Drugs

Artemether-lumefantrine from LONART Pharmaceuticals was freshly prepared and administered at 4/24 mg/kg BW throughout the experiment. This is in line with the therapeutic dose of 20/120 mg/5 kg BW in humans (Abolaji *et al.*, 2016). Analytical kits used for the assessment of biomarkers were purchased from Rapid Labs, UK and assays were done according to the manufacturer instructions.

Experimental design

All procedures employed in this study were carried out in accordance with the guidelines of the care and use of animals in research and teaching (N.I.H., 1996). Adult Wistar rats (170-200 g) of either sex obtained from the Animal House of College of Health Sciences, Osun State University, Osogbo were used in this study. Animals were acclimatized for two weeks and housed singly in well-ventilated plastic cages on a 12 hr day/night cycle. They were fed with pelletized feeds (Topfeeds) and water *ad libitum*. Estrous cycles of female rats were monitored and examined through vaginal smears. Proven male breeders were paired with estrous-positive female animals in 1:1 for mating. After parturition, ten dams were randomly assigned into 2 groups (n=5) and administration commenced immediately for seven (7) consecutive days during lactation. Group 1 dams received 1 ml of distilled water and served as control, while Group 2 dams received 4/24 mg/kg body weight of artemether-lumefantrine and served as the treatment group. The dosage used was obtained from previous study (Abolaji *et al.*, 2016).

Specimen collection

All pups were allowed to grow and euthanized at postnatal day 90 (PND 90). Animals were sacrificed via cervical dislocation method. Blood was collected from each animal via cardiac puncture into plain serum bottles for the determination of sex hormones. Testicular and ovarian tissues were excised, cleared of adherent tissue, and used for the determination of biochemical parameters. The right testis and ovary were fixed in Bouin's fluid for histological evaluation. The blood sample was spun at 3,000 rpm for fifteen minutes to obtain serum.

Experimental protocols

Hormonal assay

Enzyme Linked Immunoabsorbent Assay (ELISA) kits were used to determine serum levels of luteinizing hormone, follicle stimulating hormone, testosterone and estrogen (Rapid Labs, UK). The assay procedures were followed as written in the manual.

Redox status assay

The harvested ovaries and testes were homogenized in phosphate buffer saline (pH=7.4) and centrifuged at 3,000 rpm for ten minutes at 4°C. The supernatant was obtained for redox status determination.

Determination of tissue lipid peroxidation levels

Lipid peroxidation was determined by measuring the thiobarbituric acid reactive substances (TBARS) produced during lipid peroxidation. This method is

based on the reaction between 2-thiobarbituric acid (TBA) and malondialdehyde, an end product of lipid peroxide during peroxidation. On heating in acidic pH, the product is a pink complex which absorbs maximally at 532 and which is extractable into organic solvents such as butanol. The MDA level was calculated according to the method of Adam-Vizi and Seregei, (1982).

Determination of tissue catalase activity

Catalase activity was determined according to the method of Sinha *et al.* (1972). This method is based on the fact that dichromate in acetic acid is reduced to chromic acetate when heated in the presence of H₂O₂, with the formation of perchromic acid as an unstable intermediate. The chromic acetate then produced is measured at 570 nm.

Determination of tissue superoxide dismutase (SOD) activity

Determination of superoxide activity was done by measuring the inhibition of autooxidation of epinephrine (pH =10.2) according to the method of Misra and Fridovich, (1972). The activity was measured at 480 nm every 30 seconds for 150 seconds. 1 unit of SOD activity was given as the amount of SOD necessary to cause 50 % inhibition of the oxidation of adrenaline and the results were expressed as U mg⁻¹ protein.

Histological assessment

Testicular and ovarian tissues were dyed with Hematoxylin and Eosin stains. Organs were fixed in Bouin's fluid for a few hours before they were transferred into 10 % formalin for histological assessment. The tissues were processed, examined, and viewed under light microscope. Photomicrograph of the slide was then taken.

Statistical analysis

Data obtained are presented as mean ± S.E.M for each group. The test of significance between two groups was estimated by unpaired student's T-test. P<0.05 was considered significant.

RESULTS

Effects of maternal exposure to artemether-lumefantrine during lactation on reproductive organs weight of male and female offspring.

The reproductive organs weight on attainment of puberty in both male and female offspring were unchanged in the treated groups as compared with control (Table 1).

Table 1: Effects of artemether-lumefantrine on reproductive organs weight in male and female offspring from rats treated during lactation.

Groups	Testes (g)	Epididymis (g)	Seminal Vesicle (g)	Uterus (g)	Ovary (g)
Control	1.9±0.09	0.62±0.05	0.35±0.06	1.22±0.35	0.90±0.03
Treated	1.64±0.15	0.55±0.05	0.20±0.05	1.15±0.17	0.98±0.04

Values are represented in mean ± SEM, n = 5, *p < 0.05 is considered significant as compared with control.

Effects of maternal exposure to artemether-lumefantrine during lactation on reproductive hormones of male and female offspring in Wistar rats.

The results showed that artemether-lumefantrine caused a significant decrease (p<0.05) in estrogen (Table 2) in the female offspring as well as the testosterone levels of male offspring (Table 3) of treated rats compared with control, respectively. However, the serum levels of luteinizing and follicle stimulating hormones were comparable in both male (Table 3) and female (Table 2) offspring of the treated group as compared with control, respectively.

Table 2: Effects of artemether-lumefantrine on serum reproductive hormones in female offspring from rats treated during lactation.

Groups	LH (mIU/mL)	FSH (mIU/mL)	Estrogen (pg/mL)
Control	3.3±0.39	5.6±0.59	11±2.90
Treated	3.7±0.32	5.6±0.51	2.4±0.40*

Values are represented in mean ± SEM, n = 5, *p < 0.05 is considered significant as compared with control.

Table 3: Effects of artemether-lumefantrine on serum reproductive hormones in male offspring from rats treated during lactation.

Groups	LH (mIU/mL)	FSH (mIU/mL)	Testosterone (pg/mL)
Control	3.6 ± 0.53	5.7 ± 0.37	1.2 ± 0.75
Treated	3.7 ± 0.42	5.4 ± 0.31	0.24 ± 0.12*

Values are represented in mean ± SEM, n = 5, *p < 0.05 is considered significant as compared with control.

Effects of maternal exposure to artemether-lumefantrine during lactation on sperm profile of male offspring in Wistar rats.

The results showed that sperm motility, viability and count were unchanged on attainment of puberty in male offspring of treated group as compared with control (Table 4).

Table 4: Effects of artemether-lumefantrine on sperm profile in male offspring from rats treated during lactation.

Groups	Sperm motility (%)	Sperm viability (%)	Sperm count (10 ⁶ /ml)
Control	79.1±4.85	67.2±6.18	53.4±2.84
Treated	73.2±4.60	67.5±5.89	54.1±2.42

Values are represented in mean ± SEM, n = 5.

Table 5: Effects of artemether-lumefantrine on testicular and ovarian antioxidant enzyme activities in male and female offspring from rats treated during lactation.

Groups	MDA (nmol/mL)	SOD (nmol/mL)	CAT (umol/mL)	GSH (U/mL)
Control				
M	34±3.3	24±3.1	72±5.9	3.9±0.97
F	32±0.96	22±1.8	40±9.5	2.1±0.53
Treated				
M	36±2.8	28±3.8	31±4.9*	9.6±0.72*
F	34±0.68	17±2.2	29±7.6*	4.1±2.4

M, male; F, female; MDA, Malondialdehyde; SOD, Superoxide dismutase; CAT, Catalase; GSH, Reduced glutathione. Values are represented in mean ± SEM, n = 5, *p < 0.05 is considered significant as compared with control.

Effects of maternal exposure to artemether-lumefantrine during lactation on testicular and ovarian antioxidant enzyme activities of male and female offspring in Wistar rats.

The results show that both testicular and ovarian malondialdehyde (MDA) activity was unchanged in the offspring of treated group as compared with control (Table 5). However, the testicular and ovarian catalase levels were significantly reduced in the treated groups as compared with control (Table 5). More so, the testicular glutathione level was significantly increased in the offspring of the treated group (Table 5).

Effects of maternal exposure to artemeter-lumefantrine during lactation on testicular and ovarian histoarchitecture of male and female offspring in Wistar rats.

Photomicrographs are presented in Fig. 1. below:

A: Photomicrograph of a testicular section of control rat showing normal seminiferous tubules (Brown arrow). With normal lumen filled with abundant strands of spermatozoa. The Leydig cells appear normal (Black arrow).

B: Photomicrograph of a testicular section of treated rat with scanty seminiferous tubules depicting maturation

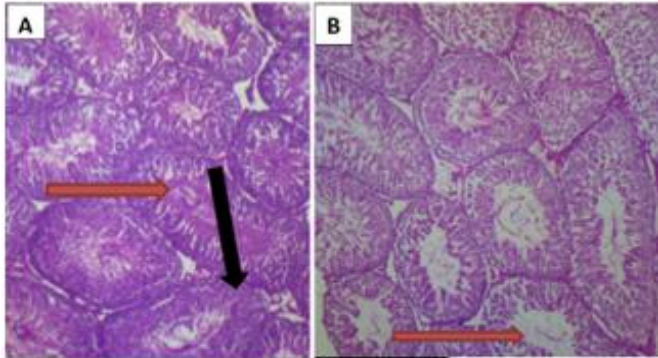


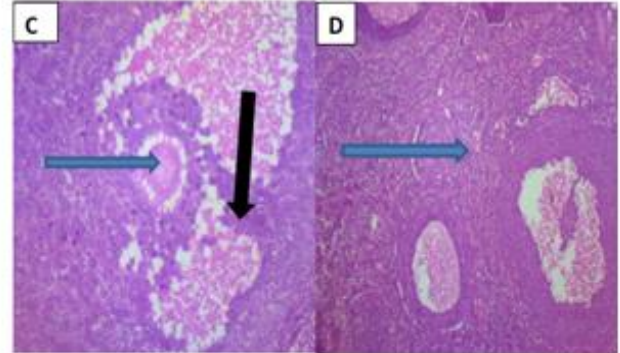
Fig.1 (Left): Effects of artemether-lumefantrine on testicular histology of offspring from rats treated during lactation (A: Control; B: Treated). Mag:X100. H&E Staining technique

Fig. 2 (Right): Effects of artemether-lumefantrine on ovarian histology of offspring from rats treated during lactation (C: Control; D: Treated). Mag:X100. H&E Staining technique.

arrest (Brown arrow) with wide lumen and few spermatozoa.

C: Photomicrograph of ovarian section of control rat showing normal stroma with normal theca cells. There is no vascular congestion while the follicles are intact with normal differential stages of maturation (Blue arrow).

D: Photomicrograph of ovarian section of control rat showing scanty stroma (Blue arrow) with sloughed theca cells. The follicles appeared scanty (Black arrow).



DISCUSSION

We investigated the probable reproductive outcomes in adult life of male and female offspring of mothers treated with Artemisinin-Based Combination Therapy (ACT) during lactation. Studies have shown that the concept of fetal programming presupposes those changes in maternal nutritional alteration or exposure to toxins can affect the normal physiological functions of offspring in adult life (Armitage *et al.*, 2004) and that any pharmacological agent depend not solely on the dose administered, but also on the time of administration in relation to body developments (Omosho *et al.*, 2013; Adeyemi *et al.*, 2018). Although, several studies have reported the direct deleterious effects of antimalarial agents on both male and female reproductive systems (Raji *et al.*, 2005; Farombi *et al.*, 2015), little is known on its reproductive effect sequel to maternal exposure during lactation. In this part of the world, artemether-lumefantrine are constantly prescribed to patients infected with malaria parasites but their safety during lactation is still obscure. Findings from this study revealed that maternal administration of this drug during lactation reduces serum testosterone levels in male offspring at PND 90. Testosterone has been

known to play crucial role in the development of male genital organs (penis, scrotum, prostate, seminal vesicle, genital ducts). Testosterone is a hormone that is produced predominantly by Leydig cells in the testes or could be obtained synthetically. This hormone is responsible for the development of primary sexual functions, which includes testicular descent, spermatogenesis, as well as the enlargement of the penis and testes, and increases libido. A significant deficient or reduction in testosterone level has been linked with reduced sexual arousal and erectile dysfunction. The reduction in testosterone level observed in this study could be substantiated with the distorted histo-architecture of the testes evidenced by sloughed interstitial cells with mild sloughing of the germinal cells thereby adversely affecting and reducing Leydig cells function to synthesize testosterone. Reduction in testicular steroidogenesis may hinder testicular development, spermatogenesis, and consequently results to male infertility in the offspring later at adult life. However, results obtained from this study showed no difference in the epididymal sperm motility, viability and counts remained intact. This could probably suggest that the drug might not have direct deleterious effects on the observed sperm quality

in this study. This is in consonance with the epididymal histological evaluation obtained in this study that revealed abundant spermatogonia cells in both treated and control groups.

Although, the deleterious effects of antimalarial drugs on female reproductive system have equally been reported but there is dearth of knowledge on the effects of artemether-lumefantrine on ovarian functions in offspring of dams treated during lactation. Results obtained from this study suggest a deleterious effect of antimalarial treatment during lactation on reproductive outcomes of offspring at adult life as there was a significant reduction in estrogen levels of offspring of dams treated with artemether-lumefantrine during this period. This may be because the ovaries are affected locally as corroborated by the changes in ovarian cyto-architecture that revealed scant follicular cells thus appearing abnormal when compared with control. Ordinarily, the ovary confers three major reproductive functions in the body which includes production of oocytes for fertilization, protection of eggs as well as production of hormones. Estrogen is not only essential for fertility in women but confers other extraneous functions in the body. Studies have however shown that any hindrance to the production and or actions of estrogen in the body would consequently results into infertility by disrupting ovulation, prevents endometrial lining of the uterus from implantation and as well reduces the potency of the cervical mucus to facilitate sperm transport (Findlay *et al.*, 2010).

It is well established that the functions of both testes and ovaries are controlled by gonadotrophin releasing hormone released from the hypothalamus which sends signals to the pituitary (anterior) gland to produce luteinizing and follicle stimulating hormones. Extensive literature search has however shown that pharmacological agents or compounds that decrease gonadal hormones production either act directly to inhibit their functions or act indirectly through the hypothalamic-pituitary-gonadal axis (Adeyemi *et al.*, 2018). Although it was observed in this study that both testosterone and estrogen were altered in the male and female offspring but both LH and FSH remained unaffected in either male or female offspring of treated dams. This however suggests that the reduction in both testosterone and estrogen levels as observed in this study is not dependent on pituitary-gonadal signaling.

To examine the implication of artemether-lumefantrine combination therapy on redox homeostasis in offspring of dams exposed to this drug during lactation, we investigated the levels of both testicular and ovarian

MDA, SOD, CAT and GSH as indices of oxidative stress. It has been documented that increased oxidative stress decreases cell viability and destroys tissues (Akindele *et al.*, 2014). Interestingly, both ovarian and testicular tissues contain poly unsaturated fatty acids that predispose them to oxidative stress (Aitken & Roman, 2008). Studies have equally shown that ACTs exert their therapeutic functions by generating free radicals. They target malaria-infected erythrocytes and destroy the parasites through production of free radicals (Little & Mullins, 2009). Under normal condition, a balance between pro-oxidants and antioxidant scavengers is expected. In this study, the malondialdehyde level being a marker of lipid peroxidation remains unchanged in both male and female offspring of treated dams. In the same manner, the antioxidant enzymes (SOD and GSH) levels were unaffected in both male and female offspring of dams exposed to artemether-lumefantrine during lactation when compared with the control group. However, the catalase activity in both testes and ovaries were significantly increased. Ordinarily, catalase is known to confer cellular antioxidant defense that functions to mop up hydrogen peroxide in the tissue. The observed increase in catalase levels could however suggest the availability of antioxidant enzymes in the tissues. This could therefore suggest that artemether-lumefantrine did not induce oxidative stress in both testes and ovaries of the offspring as evidenced in this study. This is in agreement with the study of Farombi *et al.* (2015) that reported that artemisinin cause hormonal imbalance and oxidative damage in erythrocyte and uterus but spared ovaries of rats.

In conclusion, artemether-lumefantrine causes hormonal imbalance in offspring of treated dams as evidenced by reduction in testosterone and estrogen levels of both male and female offspring. However, the testicular and ovarian redox levels were unaffected thereby suggesting that the hormonal change is independent of the redox status. Hence, further studies to determine the mechanisms which the drug causes hormonal imbalance following administration is suggested.

REFERENCES

- Abolaji, A., Adesanoye, O., Awogbindin, I., Farombi, E. (2016). Endocrine disruption and oxidative stress implications of artemether-lumefantrine combination therapy in the ovary and uterus of rats. *Human & Experimental Toxicology*, 35(11), 1173-1182.
- Adam-Vizi V. Seregi M. (1982). Receptor dependent stimulatory effect of noradrenaline on Na⁺/K⁺ ATPase in rat brain homogenate. *Role of lipid*

- peroxidation. *Biochem. Pharmacol.* 1942; 31:2231-2236.
- Adeeko A.O., Dada O.A. (1998). Chloroquine reduces fertilizing capacity of epididyma sperm in rats. *Afr J Med Med Sci*; 27:63-4
- Adeyemi D.H., Oyeyipo I.P., Akanbi K.A., Oluwole T.D. (2018). Nicotine alters progesterone and estradiol levels during the first trimester of pregnancy in Wistar rats. *JBRA Assisted Reproduction*; 22(2): 78-81.
- Aitken R.J. and Roman S.D. (2008). Antioxidant systems and oxidative stress in the testes. *Adv Exp Med Biol*; 636:154-171
- Akindele O.O., Kunle-Alabi O.T., Adeyemi D.H., Oghenetega B.O., Raji Y. (2014). Effects of vitamin E and melatonin on serum testosterone level in sleep deprived Wistar rats. *Afr.J.Med. Sci*; 43, 295-304.
- Akinsomisoye O, Raji Y, (2011). Long-Term Administration of Artesunate Induces Reproductive Toxicity in Male Rats *J Reprod Infertil*, Vol 12, No 4
- Armitage J.A., Khan I.Y., Taylor P.D., Nathaniels P.W., Poston L. (2004). Developmental programming of the metabolic syndrome by maternal nutritional imbalance: how strong is the evidence from experimental models in mammals? *J Physiol.*; 561, 355-377.
- Ataide R, Mayor A, Rogerson SJ. (2014). Malaria, primigravidae, and antibodies: knowledge gained and future perspectives. *Trends Parasitol.*;30:85-94.
- Clark RL (2009). Embryotoxicity of the artemisinin antimalarials and potential consequences for use in women in the first trimester. *Reprod Toxicol*;28(3):285-96.
- Cosentino M.J., Pakyz R.E., Fried J. (1990). Pyrimethamine: an approach to the development of a male contraceptive. *Proc Natl Acad Sci U S A*;87(4):1431-5.
- Desai M., ter Kuile F.O., Nosten F., McGready R., Asamo K., Brabin B., Newman R.D. (2007). Epidemiology and burden of malaria in pregnancy. *Lancet Infect Dis.* Feb;7(2):93-104.
- Farombi E., Abolaji A., Adedara I., Maduako I., Omodanisi I. (2015). Artemisinin induces hormonal imbalance and oxidative damage in the erythrocyte and uterus but not in the ovary of rats. *Human and experimental toxicology.* Vol 34(1). Pp 83-92.
- Findlay, J. K., Liew, S. H., Simpson, E. R., & Korach, K. S. (2010). Estrogen signaling in the regulation of female reproductive functions. *Handbook of experimental pharmacology*, (198), 29–35.
- Genovese, R.F., Newman, D.B., Li, Q., Peggins, J.O., Brewer, T.G. (1998). Dose-Dependent Brainstem Neuropathology Following Repeated Arteether Administration in Rats. *Brain Research Bulletin*, 45(2),199-202.
- Greenwood B.M., Fidock D.A., Kyle D.E., Kappe S.H., Alonso P.L., Collins F.H. (2008). Review series Malaria: progress, perils, and prospects for eradication. *J.Clin Invest.*;118:1266-76.
- Hartman T.K., Rogerson S.J., Fischer P.R. (2010). "The impact of maternal malaria on newborns". *Annals of Tropical Paediatrics.* 30 (4): 271–82.
- Izunya A.M., Nwaopara A.O., Aigbiremolen A.E., Odiike M.A., Oaikhena G.A., Bankole J.K. (2010). Histological studies of the toxicity of artesunate on the testes in Wistar rats. *Biol Med*; 2:49-56.
- Kakuru A., Jagannathan P., Muhindo M.K., Natureeba P., Awori P., Nakalembe M., Opira B., Olwoch P., Ategeka J., Nayebare P., Clark T.D., Feeney M.E., Charlebois E.D., Rizzuto G., Muehlenbachs A., Havlir D.V., Kanya M.R., Dorsey G. (2016). Dihydroartemisinin-Piperaquine for the Prevention of Malaria in Pregnancy. *N Engl J Med.* 2016 Mar 10;374(10):928-39.
- Little, S.C., and Mullins, M.C. (2009). Bone morphogenetic protein heterodimers assemble heteromeric type I receptor complexes to pattern the dorsoventral axis. *Nature cell biology.* 11(5):637-643.
- Lou X.E., Zhou H.J. (2001). Effects of artesunate on progesterone-estrogen content and decidua in rats]. *Yao Xue Xue Bao.*;36(4):254-7.
- Madanitsa M., Kalilani L., Mwapasa V., van Eijk A.M., Khairallah C., Ali D., Pace C., Smedley J., Thwai K.L., Levitt B., Wang D., Kang'ombe A., Faragher B., Taylor S.M., Meshnick S., Ter Kuile F.O. (2016). Scheduled Intermittent Screening with Rapid Diagnostic Tests and Treatment with Dihydroartemisinin-Piperaquine versus Intermittent Preventive Therapy with Sulfadoxine-Pyrimethamine for Malaria in Pregnancy in Malawi: An Open-Label Randomized Controlled Trial. *PLoS Med.* Sep 13;13(9).
- Marrelli, M.T., Brotto, M. (2016). The effect of malaria and anti-malarial drugs on skeletal and cardiac muscles. *Malar J* 15, 524 <https://doi.org/10.1186/s12936-016-1577>
- Misra H.P., Fridovich I. (1972). The role of superoxide anion in the autoxidation of epinephrine and a simple assay for superoxide dismutase. *J Biol Chem.* 1972 May 25;247(10):3170-5.
- NIH- National Institute of Health. Guide for the Care and Use of Laboratory Animals, NO.85-23. Washington: The National Academies Press; 1996.
- Nontprasert A., Pukrittayakamee S., Dondorp A.M., Clemens R., Looareesuwan S., White N.J. (2002). Neuropathologic toxicity of artemisinin

- derivatives in a mouse model. *Am J Trop Med Hyg*;67(4):423-9.
- Obianime A.W., Aprioku J.S. (2009). Comparative study of artesunate, ACTs and their combinants on the spermatc parameters of the male guinea pig. *Niger J Physiol Sci*;24(1):1-6.
- Omotoso G.O., Ibitolu J.O., Femi-Akinlosotu O.M., Akinola O.B., Enaibe B.U.(2013). Morphological and neurohistological changes in adolescent rats administered with nicotine during intra-uterine life. *Niger J Physiol Sci*.;28:147-51.
- Orisakwe O.E., Obi E., Orish V.N., Udemezue O.O. (2003).Effect of halofantrine on testicular architecture and testosterone level in guinea pigs. *Eur Bull Drug Res*;11:105-9.
- Oyeyipo I.P., Adeyemi D.H., Abe T.(2018). Testosterone and testicular changes in F1 offspring of Wistar rats maternally exposed to nicotine during gestation.*JBRA Assisted Reproduction*; 22(3): 162-166.
- Raji Y., Ifabunmi O.S., Akinsomisoye O.S., Morakinyo A.O., Oloyo A.K. (2005). Gonadal responses to antipsychotic drugs: chlorpromazine and thioridazine reversibly suppress testicular functions in male rats. *Int J Pharmacol*;1(3):287-92.
- Rath B., Jena J., Samal S., Rath B. (2010). Reproductive profile of artemisinin in albino rats. *Indian J Pharmacol*. 2010 Jun;42(3):192-3.
- Rijken M.J., McGready R., Boel M.E., Poespoprodjo R., Singh N., Syafruddin D., Rogerson S., Nosten F. (2012). Malaria in pregnancy in the Asia-Pacific region. *Lancet Infect Dis*. Jan;12(1):75-88. doi: 10.1016/S1473-3099(11)70315-2.
- Rogerson S.J., Hviid L., Duffy P.E., Leke R.F., Taylor D.W. (2007). Malaria in pregnancy: Pathogenesis and immunity. *Lancet Infect Dis*; 7 : 105-17.
- Sinha A.K. (1972). Colorimetric assay of catalase. *Anal Biochem*.;47(2):389-94. doi: 10.1016/0003-2697(72)90132-7.
- Talge, N.M., Neal, C., Glover, V. (2007). Antenatal maternal stress and long-term effects on child neurodevelopment: how and why? *Journal of Child Psychology and Psychiatry*, 48 (3-4), 245-261.
- Ukwenya V.O., Tijani A.S., Sodunke G.A., Fakunle J.B. (2010). Acute administration of co-artesiane induces oxidative stress in the testes of adult male Wistar rats. *Biosci Res Commun*, 22(5): 259-265.
- Ward S.A., Sevene E.J., Hastings I.M., Nosten F., McGready R. (2007). Antimalarial drugs and pregnancy: safety, pharmacokinetics, and pharmacovigilance. *Lancet Infect Dis*. 2007 Feb;7(2):136-44. doi: 10.1016/S1473-3099(07)70025-7
- WHO, (2018): *The World Malaria Report of 2018*.
- World Health Organization. (2019). *World Malaria Report 2019*. Switzerland: World Health Organization. pp. xii xiii, 4–10. ISBN 978-92-4-156572-1.