

Research Article

The effect of chitosan nanosilver dressing versus mesenchymal stem cells on wound healing

S.F. Ghannam, H.E. Korayem, L.M. Farghaly and S. Hosny

Department of Histology and Cell Biology, Faculty of Medicine, Suez Canal University, Ismailia, Egypt

Keywords:

Wound healing,
Nanosilver, Wound
infection,
immunofluorescence,
mesenchymal stem cells

ABSTRACT

Background: Wounds constitute a major worldwide public health problem. Infection is the most common complication of wounds. Surgical wound infection is still a major post-operative problem. New modalities for treating wound infections such as nanotechnology and stem cell therapy have been tried. The available studies investigated the effect of either mesenchymal stem cells or Chitosan nanosilver on wound-healing but they didn't compare their effects. Also, they used biochemical, vascular or immunological studies but not histological ones. **Aim:** to compare the effect of chitosan nanosilver dressing with the intradermal injection of bone marrow mesenchymal stem cells (BM-MSCs) on wound healing. **Methods:** 40 adult female albino rats were equally randomized into 4 groups: group I served as control, in group II, surgical wound was induced. In group III chitosan nanosilver dressing was used after wound induction and group IV received intradermal injection of 1×10^6 mesenchymal stem cells derived from bone marrow after wound induction. All animals were scarified after seven days by decapitation. Prepared sections were subjected to histological (Haematoxylin and Eosin stain, Masson's trichrome stain, periodic acid-Schiff reaction, immunohistochemical stain for proliferating cell nuclear antigen - PCNA and immunofluorescent techniques for labeling mesenchymal stem cells). **Results:** Wound group showed complete shedding of epidermis, decreased mean optical density of collagen fibers, negative PAS reaction and negative PCNA immunostaining. Chitosan nanosilver dressing group showed significant increase in the mean epidermal thickness, collagen optical density, and the positive PCNA immunoreactivity compared to the mesenchymal stem cells group. **Conclusion:** Both chitosan nanosilver dressing and mesenchymal stem cells (BM-MSCs) promoted wound healing, but the non-invasive chitosan nanosilver dressing had better and faster wound healing effect.

© Copyright 2018 African Association of Physiological Sciences -ISSN: 2315-9987. All rights reserved

Introduction

Wounds constitute a major worldwide public health problem that affects a large population of patients, who require different interventions for optimum care (Hess, 2004). Wound care is important as the prevalence rate of chronic wounds is similar to that of heart failure (Berry et al., 2001). The most common complication of a wound is infection, and surgical wound infection is still a major post-operative problem. Different modalities were used for treating wound infection (Sun et al., 2014).

Chitosan is one of the most abundant, renewable, nontoxic and biodegradable carbohydrate polymers that used in treating wound infection (Boateng et al., 2008), and it is an excellent antifungal and antibacterial agent (Singla and Chawla, 2001). Chitosan maintains sterile wound exudates beneath a dry scab, preventing dehydration and contamination (Li et al., 2011). Also Silver nanoparticles (AgNPs) are one of the most commonly used nanomaterials (Seltenrich, 2013) due to their antibacterial, antifungal, antiviral and anti-inflammatory effects as well as their ability to enhance wound healing (Zheng et al., 2010; Liu et al., 2012). A recent combination of chitosan and AgNP (Chitosan-AgNP) in wound dressing has demonstrated a significantly improved wound healing and also reduced the skin discoloration caused by wounds (Singh and Singh, 2014) Additionally, chitosan-AgNPs wound

*Address for correspondence:
Email somaya@hotmail.com
Tel: +2 01223773789

dressings possessed a strong antibacterial potential for wound healing applications (Murphy et al., 2015).

Another modality which was extensively used for treating wound infection is stem cell therapy (Bubela et al., 2012). Various sources of stem cells were developed by researchers to treat wounds (Bubela et al., 2012).

Materials and Methods

Female rats, between 12 and 14 weeks age, weighing 120-150 grams were used in this study, animals were divided into 4 groups: group I served the control, In group II, two surgical wound were induced under aseptic conditions, the shape of the wound was marked on the skin, with the help of adaptable plastic frame to standardize the wound size (4mm in diameter) and ruler to standardize position (2cm between the wounds) using skin marker, two round full thickness skin wounds were performed on the back of all rats. The palpable shoulder joints were used as anatomical landmarks for defining the base of the wound. The skin flap was excised to create a full-thickness skin defect by scalpel (Gainza et al., 2015). In group III, chitosan nanosilver dressing was prepared and stitched over the wound (as described under Chitosan Nanosilver dressing preparation topic), In group IV, wound was induced followed by intradermal injection of 1×10^6 mesenchymal stem cells derived from bone marrow. All animals were scarified after seven days (at the end of the experiment) by decapitation

Isolation and culture of stem cells

MSCs were isolated from 5–7-week old male rats' bone marrows that were killed by cervical dislocation. The femurs and tibias were then scraped free from all visible flesh using scalpel. Both limbs have been put in a sterile container containing 70% alcohol. The isolation process was carried out in a laminar flow hood, using sterile gloves, masks, overhead covers, and laboratory coat to avoid any contamination. The two ends of the femur and tibia were cut. Using a sterile syringe, Dulbecco's modified Eagle's medium [DMEM] (Lonza Bioproducts, Belgium) was pushed from one end of each bone and was received in a falcon tube from the other end, this process was repeated many times. The rat bone marrow was washed with phosphate buffer saline (PBS) for 5 minutes at 2000 rpm. The marrow plugs were then dissociated by pipetting and the cell pellets were suspended in 4-5 ml of normal culture medium consisted of low-glucose DMEM complemented with 10% fetal bovine serum (FBS) and 1% penicillin/streptomycin at 5 %CO₂, 37°C (Wakitani et al., 1995). The cells were seeded in tissue

culture plates at a density of 1×10^6 cells/cm². After 72 hours, non-adherent cells were removed by aspiration and the medium was changed every other day until cells became 90 % confluent. Cells were then harvested by washing the culture twice by PBS and trypsinized them with 2ml of 0.25 trypsin containing 0.02% ethylene diamine tetra acetate [EDTA] (Lonza Bioproducts, Belgium) for about 5 minutes in the incubator (Havasi et al., 2013). The action of trypsin EDTA was blocked by adding 4ml of the normal culture medium (Basiouny et al., 2013). Cell number per ml was determined by multiplying it by 10000 then the result was divided by the number of quadrants that was counted. To get the total cell number, we multiplied the cells / ml by the total volume of the cell suspension (Basiouny et al., 2013). Each wound was injected with one million cells of BM-MSC in 1 ml PBS intradermally around the wound at eight injection sites directly after wound induction (sabot et al., 2012). The injection was done using an appropriately-sized needle and the injection was considered correct when a pale small bleb was seen at the injection site. (Machholz et al., 2012).

Chitosan Nanosilver dressing preparation

1.5 g chitosan was dissolved in 100 ml 1% (v/v) acetic acid solution, and then it was filtered and poured onto plastic plates. After that it was oven-dried at a constant temperature of 40°C over a period of 24 h. Sterile chitosan films were immersed in nano-silver solution at 4 ° C for 12 h, then, they were washed extensively with distilled water (Lu et al., 2008). Ag–N bonding produced the dressing at a concentration ranged between 0.69 and 1.64 mg/cm² (Rigo et al., 2013).

Two skin specimens with 3mm of the surrounding skin were obtained from the two wounds of each animal. The specimens were fixed in 10% neutral buffered formalin for 24 hours at room temperature (23–28°C) and were processed to prepare 5µm thick paraffin sections. The obtained sections were stained using Haematoxylin & Eosin stain (H& E) for the general architecture of the skin, Masson's trichrome stain for collagen fibers, periodic acid-Schiff reaction (PAS) for the basement membrane and immunohistochemical stain for the demonstration of proliferating cell nuclear antigen (PCNA) in the rat skin epidermis. Qualitative and quantitative assessments were done for histological and immunohistochemical changes in the skin. Quantitative measurements were done using computer software Pro Plus image J. The measurement included epidermal thickness and the optical density of; collagen fibers, PAS positive material of the epidermal basement

membrane and PCNA immunoreactivity in the epithelial cells of the epidermis.

All experimental procedures of animals used for the current study were approved by the Ethical Committee of the Faculty of Medicine, Suez Canal University. Stem cells were characterized using immunofluorescence technique by using DAPI 4', 6-Diamidino-2-phenylindole stain [Sigma -Aldrich, Germany] to label stem cells before injection.

Statistical analysis:

Data were presented as mean \pm standard deviation (SD). The results were compared using Student T test for the histological changes. Statistical significance was determined at 95% confidence interval.

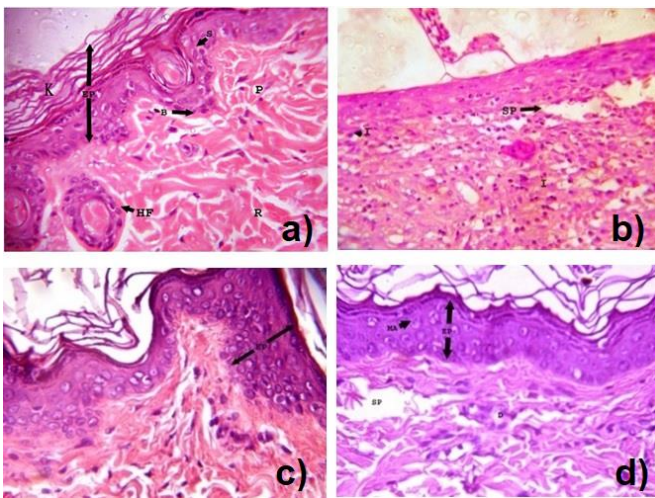


Fig. 1. H&E Stain: (a) A photomicrograph of thin skin of a rat from the control group showing the epidermis (EP) with ill-defined strata including stratum basale (B) stratum spinosum (S) and stratum corneum (K). Papillary (P) and reticular (R) layers of dermis and hair follicles (HF) are also shown (H&E x 400). (b) A photomicrograph of thin skin of a rat from the wound group showing complete shedding of epidermis, many spaces (SP), inflammatory cellular infiltrate (I) in the dermis and loss of skin appendages (H&E x 400). (c) A photomicrograph of thin skin of a rat from the ‘wound with chitosan nanosilver dressing’ group showing completely regenerated epidermis (EP) (H&E x 400) (d) A photomicrograph of thin skin of a rat from the ‘wound with mesenchymal stem cells’ group showing the epidermis (EP) with loss of the horny layer. Mitotic activity (MA) is shown. Spaces (SP) in the upper part of the dermis are shown (H&E x 400).

Group II (surgical wound induction group): showed complete shedding of epidermis with inflammatory cellular infiltration in the dermis and loss of some tissue areas leaving empty spaces (Fig.1b). Group III (wound induction followed by chitosan nanosilver

dressing) showed evidence of epithelization (Fig.1c). The epidermis appeared again with all its layers even the horny layer with hyperplasia and hypertrophy of its cells (Table 1, Fig.1c). Group IV: (wound induction followed by injection of intradermal 1×10^6 mesenchymal stem cells derived from bone marrow): showed reappearance of all epidermal layers except the horny layer. Hyperplasia of the epithelial cells and mitotic activity in cells of stratum spinosum layer were also detected (Fig.1d). Spaces were still seen in the dermis (Fig.1d). There was statistical significant increase in the epidermal thickness in group III (Chitosan) compared to group IV (MSCs) and there was statistical significant increase in the epidermal thickness in both groups III &IV compared to wound group. There was statistical significant increase in the epidermal thickness in both group III and group IV compared to control group (Table1).

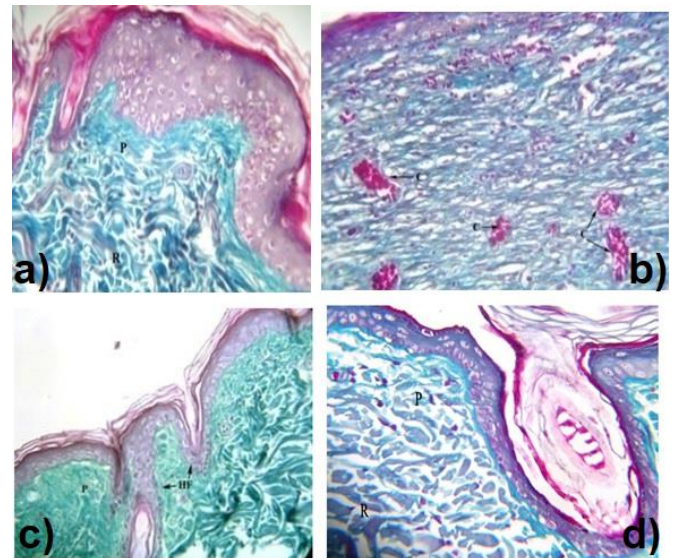


Fig. 2. Masson's Trichrome stain: (a) A photomicrograph of thin skin of a rat from control group showing fine collagen fibers in papillary layer of the dermis (P) aggregated below the basal lamina. Coarse irregular interwoven fibres in the reticular layer of the dermis (R) are shown (Masson's trichrome x 400). (2b): A photomicrograph of thin skin of a rat from wound group showing disorganized, irregular collagen fibers in the dermis with decrease in its amount compared to control group. Many congested blood vessels (C) are also shown (Masson's trichrome x 400). (c) A photomicrograph of thin skin of a rat from the ‘wound with chitosan nanosilver dressing’ group showing normal arranged dense collagen fibers in the papillary layer (P) of the dermis and around hair follicle [HF] (Masson's trichrome x 400). (d): A photomicrograph of thin skin of a rat from the ‘wound with mesenchymal stem cells’ group showing dense disorganized thick collagen fibers aggregated below the basal lamina, loosely arranged fibers in the dermal papillary layer (P) and thick irregular bundles in the reticular layer of the dermis [R] (Masson's trichrome x 400).

Table 1: The mean epidermal thickness and mean optical density of collagen in the different study groups:

Group	Mean \pm SD Epidermal thickness	Mean \pm SD collagen fibers density
Control group	37.6 \pm 11.6	0.356 \pm 0.1
Wound group	0 *	0.069 \pm 0.006*
Chitosan –nanosilver dressing group	147.2 \pm 21.2*#\\$	0.258 \pm 0.08*#\\$
MSCs group	135 \pm 24.3*#\\$	0.146 \pm 0.03*#\\$

Masson's trichrome stained sections of Group I showed normal fine green collagen fibers aggregated beneath the dermo-epidermal junction. Fine loosely arranged network of collagen fibers were seen in the papillary layer that combined with thick interwoven fibers in the reticular layer of the dermis and around the hair follicles and the sebaceous glands (Fig.2a). In Group II there were disorganized irregular collagen fibers in the reticular layer of the dermis with statistical significant decrease in the optical density of collagen fibers of wound group in comparison to control group (Table 1, Fig.2b). Group III showed normal arranged dense collagen fibers in the papillary layer of the dermis and around hair follicles (Fig.2c). Group IV: revealed disorganized collagen fibers in the papillary layer of the dermis and reticular layer of the dermis (Fig.2d). There was statistical significant decrease in the optical density of collagen fibers in both group III and group IV compared to control group and statistical significant increase in the optical density of collagen fibers in both group III and group IV compared to wound group. Also, there was statistical significant increase in the optical density of collagen fibers of group IV compared to group III (Table 1).

PAS stained sections of group I revealed normal PAS positive material in the basement membrane of the epidermis and around the hair follicle (Fig.3a). In Group II, there was no apparent basement membrane PAS material (Fig.3b). Group III revealed reappearance of the PAS positive material of the basement membrane of the epidermis but it was less in intensity than that of control group (Fig.3c). Group IV revealed PAS positive material in the basement membrane of the epidermis which was less than that of the control group and slightly less than Chitosan group (Fig.3d). There was statistically significant increase in the optical density of magenta

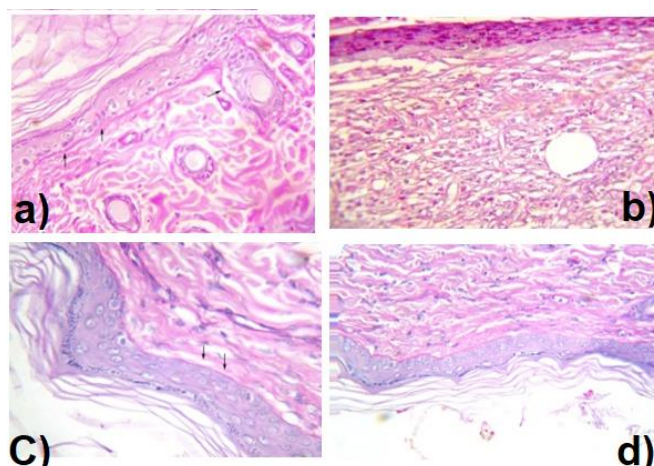


Fig. 3. PAS stain: (a) A photomicrograph of thin skin of a rat from control group showing PAS positive material in the basement membrane of the epidermis and around hair follicles (PAS x 400). (b) A photomicrograph of thin skin of a rat from wound group showing loss of the epidermis including its basement membrane. (PAS x400). (c) A photomicrograph of thin skin of a rat from the 'wound with chitosan nanosilver dressing' group rat showing PAS positive material in the basement membrane of the epidermis which is less in intensity than that of control group (PAS x400). (d) A photomicrograph of thin skin of a rat from wound with mesenchymal stem cells group showing PAS positive material in the basement membrane underlying the epidermis which is less intense than that of the control group and chitosan group (PAS x 400).

color of basement membrane in both group III and group IV compared to wound group; however, there was no significant difference in the optical density of basement membrane between group III and group IV (Table 2).

Immunohistochemical study

PCNA immunostaining of group I showed positive brownish color reaction in the nuclei of the basal layer of the epidermis (Fig. 4a). Group II showed negative reaction due to loss of the epidermal layer while the dermis had positive brown reaction in the nuclei which was not shown in the control group. (Fig. 4b). Group III & IV revealed positive brownish color reaction in the cells of basal layer of the epidermis and around hair follicle (Fig.4c&4d). There was statistical significant increase in PCNA immunoreactivity of both group III and group IV compared to control group and compared to wound group. Also, there was statistical significant increase in PCNA immunoreactivity of group III compared to group IV (Table2).

Immunofluorescence study

In group IV, green fluorescent deposits were detected within the regenerated epidermis, dermis and in hair follicles which confirm the presence of mesenchymal stem cells (Fig 5).

Table 2: The mean optical density of PAS material and the mean optical density of PCNA in the different study groups:

Group N/10	Mean \pm SD density of PAS	Mean \pm SD PCNA density
Control group	0.203 \pm 0.015	0.336 \pm 0.037
Wound group	0*	0*
Chitosan – nanosilver group	0.195 \pm 0.024#	0.673 \pm 0.111*#
MSCs group	0.183 \pm 0.022*#	0.572 \pm 0.104*#

(*) Statistical significant difference between these groups and control group ($P = 0.00$); (#) Statistical significant difference between these groups and wound group ($P = 0.00$); (\$) Statistical significant difference between chitosan nanosilver dressing group and MSCs group ($P = 0.001$).

DISCUSSION

The present study was designed to evaluate the therapeutic effects of chitosan nanosilver dressing versus bone marrow derived mesenchymal stem cells on wound healing in adult albino rats using light microscopic examination.

Light microscopic examination of wound group in this study showed severe histopathological changes. There was complete loss of all layers of the epidermis. The dermis showed inflammatory cellular infiltration and loss of skin appendages with consequent failure of complete healing in all animals. These results are consistent with sabol et al. (2012) study which demonstrated loss of epithelial cells and infiltration of dermis with polymorphonuclear leukocytes such as monocytes and macrophages with failure of hair regeneration in rats exposed to two (4mm) round full thickness cutaneous wounds for two, six, and fourteen days post.

In the wound group, there was statistically significant decrease in optical density of collagen fibers compared to control group. These results are consistent with those of Basiouny et al. (2013) who revealed scanty, irregularly-arranged collagen bundles and failure of

collagen remodeling after 7 days of wound induction. Also, Yulin et al. (2015) found collagen deposition without certain direction after one week in rats exposed to acute cutaneous wound for two weeks.

PAS stained sections revealed negative PAS material due to loss of all layers of epidermis including the basement membrane. These results are in accordance with those of Chan et al. (2001) who found that after seven days of acute wound in rats, there is no organized basement membrane.

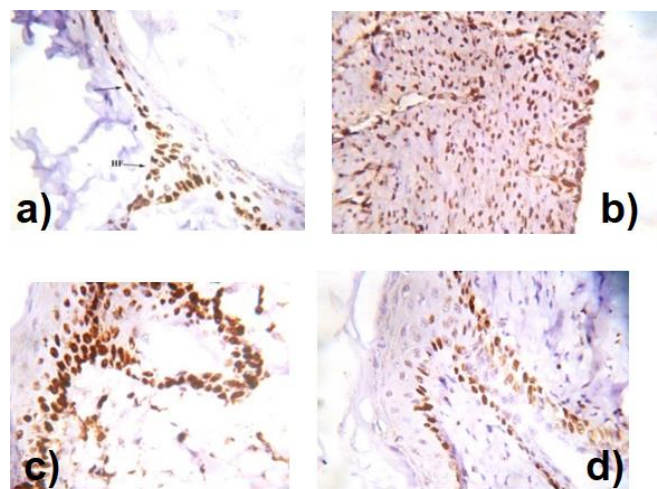


Fig. 4. PCNA stain: (a) A photomicrograph of thin skin of a rat from control group rat showing mild immunoreactivity of PCNA in the form of brown positive reaction in the nuclei of the cells of the basal layer of the epidermis and around hair follicle (HF) with negative reaction in the dermis (PCNA immunostaining x 400). (b) A photomicrograph of thin skin of a rat from wound group showing marked immunoreactivity of PCNA in the form of brownish color reaction in the papillary and reticular layers of the dermis (PCNA immunostaining x 400). (c): A photomicrograph of thin skin of a rat from wound with chitosan nanosilver dressing group showing intense immunoreactivity of PCNA in the form of brownish color in the basal layer of the epidermis and around hair follicle (PCNA immunostaining x 400). (d) A photomicrograph of thin skin of a rat from wound with mesenchymal stem cells group showing moderate brown immunoreactivity of PCNA in the basal layer of the epidermis and around hair follicle (PCNA immunostaining x 400).

Decrease of PCNA reaction observed in this group was due to loss of all layers of epidermis as result of the mechanical injury caused by the wound. These findings were documented in many studies such as that of Lian et al. (2014) who found decrease in the number of PCNA positive cells in rats of wound group than other groups, seven days post-surgery. Also, Xu et al. (2016) demonstrated decrease in the optical density of PCNA in wound group rats at the seventh day after wound



Fig. 5. green fluorescence: Photomicrograph of a section in the skin of rat treated one week duration showing labeled MSCs which appear as green fluorescent deposits within the regenerated epidermis, dermis and hair follicles (Immunofluorescence x 400).

induction. The positive brown reaction in the nuclei of the dermis that appeared in the wound group and not in the control group can be due to the detected inflammatory infiltration in the dermis of this group

In chitosan nanosilver (ChNs) dressing group the architecture is nearly similar to control group but with thicker epidermis. This was confirmed by the statistical significant increase of epidermal thickness in this group compared to control group. This finding was similar to the that of Ojeda-Martínez et al. (2015) who found a full-thickness re-epithelialization in wounds of rats treated with chitosan film plus deposited silver nanoparticles (AgNPs), which may confirm the increased thickness we found in our study. This increase in thickness can be explained by the ability of AgNPs to release transforming growth factor b that stimulate keratinocytes to produce vascular endothelial growth factor (Nadworny et al., 2010). In our study, we found normal arranged dense collagen fibers in the papillary layer of the dermis with dense irregular interwoven fibers in the reticular layer. This may be due to the stimulating effect of Chitosan on the fibroblasts to synthesize type I and type IV collagen fibers (Shi et al., 2006) and also its effect on accelerating the reformation of connective tissue (Gopal et al., 2013). It was found that Chitosan stimulates cell proliferation of fibroblasts through extracellular-signal-regulated kinases 1 and 2 (ERK1/2) signaling pathway (Silva et al., 2013). In our study, the

PCNA reaction was regained in the Chitosan group. This may be explained by the ability of Chitosan to acts as scaffold for keratinocytes and fibroblasts for basement membrane repair (Risbud et al., 2000; Price et al., 2007). Also, Ojeda-Martínez et al. (2015) demonstrated the presence of PCNA immunopositive cells in rats treated with chitosan films with AgNPs deposits. Their study reported that the cationic global nature of the chitosan film with AgNPs promotes an electrostatic interaction with keratin in the skin as it is rich in sulfur, thus induces an electric charge in cells which promotes proliferation and wound healing of the skin.

In MSCs group, MSCs showed re-epithelialization and significant increase of epidermal thickness compared to control, however the horny layer was not regained. Our results are in accordance with Liu et al. (2013) study which showed that rats injected intradermally by 1×10^6 BM-MSCs have epidermal regeneration with mature differentiation and recovery of skin appendages after seven days. In this group we observed disorganized collagen fibers in the papillary layer of the dermis and reticular layer of the dermis. This was confirmed by the statistical significant increase in the optical density of collagen fibers compared to wound group. Our results are consistent with the results of Wu et al. (2014) who demonstrated collagen fibers deposition which was not identical to the basket-weave pattern of the control group in rats subcutaneously injection with 1×10^6 MSCs. resemblance but

PAS stained sections of MSCs group revealed PAS positive material of the epidermal basement membrane which was also demonstrated in Ojeh and Navsaria, (2013) study which revealed that MSCs displayed multilayered, well-differentiated epidermis expressed differentiation markers (K10) with basement membrane proteins on in vitro skin models.

In our study PCNA stained sections of MSCs group revealed moderate positive brown reaction in basal layer of the epidermis. These results were supported by Ojeh and Navsaria, (2013) who explained it by the ability of MSCs to stimulate keratinocytes differentiation through expression markers of differentiation (K10), and hyperproliferation (K6). MSCs have been observed to transdifferentiate into keratinocytes which helps in wound healing (Sasaki et al., 2008). They accelerate the wound healing process via antimicrobial peptide secretion (Krasnodembskaya et al., 2010).

The benefits of using MSCs in wound healing were discussed by some investigators, Kiang and Gorbunov, (2014) showed that intradermal injection of BM-MSCs accelerated the wound healing rate from 5.7 mm² /day

to 7.6 mm²/day. Also, Chen et al., 2008; Sasaki et al., 2008; and Uysal et al., 2014 examined the effect of local injection of MSCs into incision full thickness wound and proved accelerated time of wound closure with increased angiogenesis, re-epithelialization, and recruitment of myeloid cells into the wound.

The limitations of using MSCs were also discussed by other investigators, Hu et al. (2014) reported that it is unfeasible to culture enough MSCs to heal a large wound. Moreover, the population of MSCs within humans decreases overtime, so it eliminates the option of using autologous MSCs for treatment in the older generations. In addition, Bentivegna et al. (2013) found that the efficacy of MSCs therapy requires large numbers of cells by ex vivo expansion of MSCs and for clinical use, it may cause epigenetic and phenotypic changes in cells which lead to mutations as a result of long term culture. Therefore, You and Han (2014) suggest that cell therapy is a standard treatment, however, further research is still needed to prove that.

Overall, this study, showed that the use of chitosan lead to complete healing of the surgical wound with improvements of all other used parameters after seven days of treatment, however MSC did not regain all the epidermal layers, added to the recorded limitations of using MSCs discussed previously, Chitosan nanosilver can be recommended as a faster feasible noninvasive technique than the invasive stem cell therapy.

CONCLUSION

Both chitosan nanosilver dressing and mesenchymal stem cells (BM-MSCs) promoted wound healing, however using the non-invasive technique of chitosan nanosilver dressing led to better and faster wound healing.

REFERENCES

- Basiouny H.S., Salama N.M., El Maadawi Z.M. and Farag E. A. (2013). Effect of bone marrow derived mesenchymal stem cells on healing of induced full-thickness skin wounds in albino rat. *International Journal of Stem Cells*; 6(1):12–25.
- Bentivegna A., Miloso M., Riva G. et al. (2013). DNA methylation changes during in vitro propagation of human mesenchymal stem cells: implications for their genomic stability? *Stem Cells International*; Article ID192425, 9 pages.
- Berry C., Murdoch D.R., McMurray J.J. (2001). Economics of chronic heart failure. *Eur J Heart Fail*; 3(3):283–291.
- Boateng J.S., Matthews K.H., Stevens H.N. and Eccleston, G.M. (2008). Wound healing dressings and drug delivery systems: a review. *J. Pharm. Sci.*; 97(8): 2892-2923.
- Bubela T., Li M.D., Hafez M., Bieber M., Atkins H. (2012). Is belief larger than fact: Expectations, optimism and reality for translational stem cell research". *BMC Med*; 10(133):1714– 7015.
- Chan J.C.Y., Duszczyszyn D.A., Castellino F.J. and Ploplis V.A. (2001). Accelerated Skin Wound Healing in Plasminogen Activator Inhibitor-1-Deficient Mice. *American Journal of Pathology*; 159(5): 1681-1688.
- Chen L., Tredget E.E., Wu P.Y.G. and Wu Y. (2008). Paracrine factors of mesenchymal stem cells recruit macrophages and endothelial lineage cells and enhance wound healing, *PLoS ONE*; 3(4).
- Gainza G., Bonafonte D.C., Moreno B., Aguirre J.J., et al., (2014). The topical administration of rhEGF-loaded nanostructured lipid carriers (rhEGF-NLC) improves healing in a porcine full-thickness excisional wound model. *Journal of Controlled Release*; 197 (2015) 41–47.
- Gopal A., Kant V., Syam R., Sreela L., Gupta V., Kumar D. et al (2013). Chitosan: A novel material for healing. *J. Med. & Allied Health Sciences*; 2(1):19–23.
- Havasi P., Nabioni M., Soleimani M., Bakhshandeh B. and Parivar K. (2013). Mesenchymal stem cells as an appropriate feeder layer for prolonged in vitro culture of human induced pluripotent stem cells. *Mol Biol Rep*; 40(4):3023-31.
- Hess C.T. (2004). Putting the squeeze on venous ulcers. *Nursing*; 34(Suppl Travel):8–13.
- Hu M.S., Leavitt T., Malhotra S., Duscher D., Pollhammer M.S., Walmsley G.G., Maan H.Z., Cheung A.T.M., Schmidt M., Huemer M.G., Longaker M. T. and Lorenz H.P. (2014). Stem Cell-Based Therapeutics to Improve Wound Healing. *J Clin Exp Pathol*; 4(5):191.
- Kiang J.G. and Gorbunov N.V. (2014). Bone Marrow Mesenchymal Stem Cells Increase Survival after Ionizing Irradiation Combined with Wound Trauma: Characterization and Therapy. *J Cell Sci Ther*, 5:6.
- Krasnodembskaya A., Song Y., Fang X. et al (2010). Antibacterial effect of human mesenchymal stem cells is mediated in part from secretion of the antimicrobial peptide LL-37, *Stem Cells*; 28(12):2229–2238.
- Li P, Poon YF, Li W, et al. (2011). A polycationic antimicrobial and biocompatible hydrogel with microbe membrane suctioning ability. *Nat Mater*; 10(2):149–156.
- Lian Z., Yin X., Li H., Jia L., He X., Yan Y., Liu N., Wan K., Li X. and Lin S. (2014). Synergistic Effect of

- Bone Marrow-Derived Mesenchymal Stem Cells and Platelet-Rich Plasma in Streptozotocin-Induced Diabetic Rats. *Ann Dermatol*; 26(1):1–10.
- Lu. S, Gao. W, Gu. H.Y. (2008). Construction, application and biosafety of silver nanocrystalline chitosan wound dressing. *Burns*. Volume 34(5), 623–628
- Liu X., Wangi Z., Wangi R., Zhaoi F., Shi P., Jiangi Y. and Pang X. (2013). Effect of MSCs from different sources on cutaneous wound, direct comparison of the potency of human mesenchymal stem cells derived from amnion tissue, bone marrow and adipose tissue at inducing dermal fibroblast responses to cutaneous wounds. *International Journal of Molecular Medicine*; 31: 407–415.
- Liu Y., Zheng Z., Zara J.N. et al., (2012). The antimicrobial and osteoinductive properties of silver nanoparticle/poly (dl-lactico-glycolic acid) -coated stainless steel. *Biomaterials*; 33(34):8745–8756.
- Machholz E, Mulder G., Ruiz C., Corning B.F. and Pritchett-coring K. R. (2012). Manual restraint and common compound administration routes I mice and rats. *Journal of visualized Experiments*; 67:2771.
- Murphy M., Ting K., Zhang X., Soo C. and Zheng Z. (2015). Current Development of Silver Nanoparticle Preparation, Investigation, and Application in the Field of Medicine. *Journal of Nanomaterials*; 2015:1–12.
- Nadworny P.L., Wang J.F., Tredget E.E. and Burrell R.E. (2010). Anti-inflammatory activity of nanocrystalline silver-derived solutions in porcine contact dermatitis. *J Inflam.* ; 7:13.
- Ojeda-Martínez M.L., Yáñez-Sánchez I., Velásquez-Ordoñez C., Martínez-Palomar M.M., Álvarez-Rodríguez A., García-Sánchez M.A., Rojas-González F. and Gálvez-Gastélum F.J. (2015). Skin wound healing with chitosan thin films containing supported silver nanospheres. *Journal of Bioactive and Compatible Polymers*; 30(6):617–632.
- Ojeh N.O. and Navsaria H.A. (2013). An in vitro skin model to study the effect of mesenchymal stem cells in wound healing and epidermal regeneration. *J Biomed Mater Res A*. 102 (8):2785-92.
- Price R.D., Berry M.G. and Navsaria H.A. (2007). Hyaluronic acid: the scientific and clinical evidence *Journal of Plastic, Reconstructive & Aesthetic Surgery*.; 60 (10): 1110–1119.
- Rigo C., Ferroni L., Tocco I., Roman M., Munivrana I., Gardin C., Cairns W., Vindigni V., Azzena B., Barbante C. and Zavan B. (2013). Active Silver Nanoparticles for Wound Healing. *Int. J. Mol. Sci.* ;14(3): 4817–4840.
- Risbud M., Hardikar A., and Bhonde R. (2000). Growth modulation of fibroblasts by chitosanpolyvinylpyrrolidone hydrogel: Implications for wound management? *J. Biosci.*; 25(25), 31–34.
- Sabol F., Dancakova L., Gal P., Vasilenko T., Novotny M., Smetana K., and Lenhardt L. (2012). Immunohistological changes in skin wounds during the early periods of healing in a rat model. *VeterinariMedicina*; 57 (2):77–82.
- Sasaki M., Abe R., Fujita Y., Ando S., Inokuma D. and Shimizu H. (2008). Mesenchymal stem cells are recruited into wounded skin and contribute to wound repair by transdifferentiation into multiple skin cell type, *The Journal of Immunology*; 180(4):2581–2587.
- Sasaki M., Abe R., Fujita Y., Ando S., Inokuma D. and Shimizu H. (2008). Mesenchymal stem cells are recruited into wounded skin and contribute to wound repair by transdifferentiation into multiple skin cell type, *The Journal of Immunology*; 180(4):2581–2587.
- Seltenrich N (2013). Nanosilver: weighing the risks and benefits. *Environ. Health Perspect*, 121(7), a 220-5.
- Shi C.M., Zhu Y., Ran X.Z., Wang M., Su Y. and Cheng T.M. (2006). Therapeutic potential of chitosan and its derivatives in regenerative medicine. *J. Surg. Res.*; 133(2):185–192.
- Silva D., Arancibia R., Tapia C., et al (2013). Chitosan and platelet-derived growth factor synergistically stimulate cell proliferation in gingival fibroblasts. *J Periodontal Res*; 48(6): 677–686.
- Singh R. and Singh D. (2014). Chitin membranes containing silver nanoparticles for wound dressing application, *International Wound Journal*; 11(3):264–268.
- Singla A.K. and Chawla M. (2001). Chitosan: some pharmaceutical and biological aspects-an update. *J. Pharm. Pharmacol.*; 53(8):1047-1067.
- Uysal A., Tobita M., Hyakusoku H., and Mizun H. (2014). The Effect of Bone-Marrow-Derived Stem Cells and Adipose-Derived Stem Cells on Wound Contraction and Epithelization. *405 Advances in Wound Care*; 3(6):405–413.
- Wakitani S, Saito T, and Caplan A.I. (1995). Myogenic cells derived from rat bone marrow mesenchymal stem cells exposed to 5-azacytidine. *Muscle Nerve*; 18 (12):1417–1426.
- Wu Y., Huang S., Enhe J., Ma K., Yang S., Sun T. and Fu X. (2014). Bone marrow-derived mesenchymal stem cell attenuates skin fibrosis development in mice. *Int Wound J*; 11(6):701–710.

- Xu R, Xia H, He W, Li Z, Zhao J, Liu B, Wang Y, Lei Q, Kong Y, Bai Y, Yao Z, Yan R, Li H, Zhan R, Yang S, Luo G and Wu J(2016). Controlled water vapor transmission rate promotes wound-healing via wound re-epithelialization and contraction enhancement. *Sci Rep.*; 6: 24596.
- You H-J and HanS-K(2014). Cell Therapy for Wound Healing. *J Korean Med Sci* 2014; 29: 311-319
- Yulin A., Wei W., Huan J., Leiguo M., Shiyu L. and Yan J. (2015). Bone marrow mesenchymal stem cell aggregate: an optimal cell therapy for full-layer cutaneous wound vascularization and regeneration. *Scientific Reports*; 46(4-5):431–438.
- Zheng Z., Yin W. and Zaratel J.N. (2010). The use of BMP-2coupled— nanosilver-PLGA composite grafts to induce bone repair in grossly infected segmental defects. *Biomaterials*; 31(35):9293–9300.