

HEPATOPROTECTIVE AND ANTIOXIDANT ACTIVITIES OF AQUEOUS EXTRACT OF *Moringa oleifera* FLOWER ON CCl₄-INDUCED TOXICITY IN RATS

Arise, R. O.^{1,2*}, Idris, B. I.¹, Aburo, O. R.³, Adewale, A. A.⁴

¹Department of Biochemistry, Faculty of Life Sciences, University of Ilorin, P.M.B. 1515, Ilorin, Nigeria.

²Landmark University, College of Science and Engineering, Department of Biological Sciences, Omu-Aran, Kwara State, Nigeria.

³Department of Biochemistry, Afe Babalola University, Ado Ekiti, Ekiti, Nigeria. E-mail: seun_aburo@yahoo.com

⁴Bowen University, Department of Biochemistry, Iwo, Osun State, Nigeria. E-mail: adewaleadenike14@gmail.com

*E-mail of corresponding author: arise.ro@unilorin.edu.ng or arise.rotimi@lmu.edu.ng Tel: +2348033869546

(Received: 9th April, 2018; Accepted: 24th February, 2019)

ABSTRACT

Liver disorders constitute part of health problems in developing countries, and available chemo-preventive drugs against liver diseases are costly and less effective. *Moringa oleifera* contains high concentrations of four natural dietary antioxidants: vitamins A, C, E and phenolics. This study was therefore carried out to evaluate the hepatoprotective activity of aqueous extract of *M. oleifera* flower on carbon tetrachloride (CCl₄)-induced hepatotoxicity in Wistar rats. Twenty five (25) male rats were randomly distributed into five groups. Group A (control) received distilled water, while groups B-E received 1.5 ml/kg b.w. of CCl₄ followed by 1 ml of distilled water, 62.5, 125 and 250 mg/kg b.w. of aqueous extract of *M. oleifera* flower (AEMOF) respectively. Serum alkaline phosphatase (ALP) activity of rats administered 1.5 ml/kg body weight of carbon tetrachloride, but untreated increased significantly ($p < 0.05$) when compared with the control. There was no significant difference ($p > 0.05$) in liver ALP activity of rats administered 125 and 250 mg/kg b.w. of aqueous extract of *M. oleifera* flower when compared with the control. Similarly, there were no significant differences in both serum and liver alanine aminotransferase (ALT) activities of rats administered 125 and 250 mg/kg b.w. of aqueous extract of *M. oleifera* flower relative to the control. This observation suggests that the hepatoprotective activity of aqueous extract of *M. oleifera* flower may be due to the prevention of leakage of intracellular enzymes of the hepatocyte by stabilizing its membrane. Furthermore, liver superoxide dismutase (SOD), catalase and gamma-glutamyl transferase (GGT) activities of rats treated with 250 mg/kg b.w. of aqueous extract of *M. oleifera* flower were not significantly ($p > 0.05$) different from the control. Histopathological examinations of the tissues from the experimental rats clearly supported the biochemical findings. Results from this study strongly indicate that aqueous extract of *M. oleifera* flower possesses remarkable hepatoprotective potential underlining its ability to prevent and reverse CCl₄-induced liver injury in experimental animals.

Keywords: *Moringa oleifera* flower, Carbon tetrachloride, Hepatotoxicity, Antioxidants, Lipid peroxidation

INTRODUCTION

Hepatic diseases, like alcoholic fatty liver and hepatocellular damage, play an important role in the development of liver cirrhosis and, hence, hepatocellular carcinoma (Hashemi, 2014). Conventional or synthetic drugs used in the treatment of liver diseases are known to be expensive and sometimes may have serious side effects (Hashemi, 2014). The liver plays an astonishing array of vital functions in the maintenance, performance and regulating homeostasis of the body. It is involved with almost all the biochemical pathways in growth, defense against diseases, nutrient supply, energy provision and reproduction (Sherman, 1991). The major functions of the liver are carbohydrate, protein and fat metabolism, detoxification,

secretion of bile and storage of vitamins (Hashemi, 2014). Thus, to maintain a healthy liver is a crucial factor for the overall health and well-being.

Liver damage can be caused by certain xenobiotics and microbial infiltration from ingestion or infection (Huo et al., 2011). Hepatotoxicity implies chemical-driven liver damage. Certain medicinal agents, when taken in high doses and sometimes even when used within therapeutic ranges, may injure the organ. Other chemical agents, such as those used in laboratories and industries, natural chemicals (e.g, microcystins) and herbal remedies can also induce hepatotoxicity. Chemicals that cause liver injury are called hepatotoxins. More than 900 drugs have

been implicated in causing liver injury and it is the most common reason for a drug to be withdrawn from the market (Kshirsagar et al., 2009). Abnormal liver enzyme tests often indicate subclinical liver injury caused by chemicals. More than 75 % of cases of idiosyncratic drug reactions result in liver transplantation or death (Ostapowicz et al., 2002).

Carbon tetrachloride (CCl_4) is a well-established xenobiotic. Previous studies showed that both liver and kidneys are the target organs of CCl_4 (Hashemi, 2014). Extensive evidence demonstrated that CCl_4 is activated in the liver to a highly reactive trichloromethyl radical which initiates free radical mediated lipid peroxidation of the cytoplasmic membrane phospholipids and causes functional and morphological changes in the cell membrane, leading to an accumulation of lipid-derived oxidants causing liver injury (Singh et al., 2008).

M. oleifera is a tropical, highly valued plant, distributed in many countries of the tropics and subtropics. It is a small, fast-growing ornamental tree originally found in India (Muluvi et al., 1999). Root, bark, pods, and leaves of this tree are used in traditional medicine for the treatment of human diseases. It has an impressive range of medicinal uses including: antibiotic (Fahey, 2005), anticancer (Guevara et al., 1999), and antidiabetic (Al-Malki and El Rabey, 2015). *M. oleifera* provides high concentrations of four natural dietary antioxidants: Vitamins A, C, E and phenolics. It contains 46 antioxidants which help cells to neutralize free radicals (Amaglo et al., 2010). The aim of this study was to evaluate the hepatoprotective and antioxidant effects of *M. oleifera* flower aqueous extract on CCl_4 -induced acute hepatotoxicity in rats.

MATERIALS AND METHODS

Materials

Plant Material

Fresh flowers of *M. oleifera* were obtained from the University of Ilorin Moringa Plantation, Ilorin, Nigeria. The plant was authenticated at the Herbarium Unit of the Department of Plant Biology, University of Ilorin, Nigeria where a specimen was deposited with a voucher number UIH/002/1008 for record purpose.

Experimental Animals

Twenty five (25) male Wistar rats of average weight of 160.00 ± 3.22 g were obtained from the Animal Holding Unit of the Department of Biochemistry, University of Ilorin, Nigeria. The animals were acclimatized for two weeks before the experiment, housed in clean wooden cages and were placed on standard feeds and allowed free access to water with 12 hours light/dark cycle.

Chemicals and Assay Kits

The assay kits for the albumin, total and conjugated bilirubin, urea, aspartate aminotransferase (AST), alkaline phosphatase (ALP) and alanine aminotransferase (ALT) were products of Randox Laboratory Ltd, Co-Atrium, UK. All other reagents used were of analytical grades and prepared in glass distilled water.

Methods

Preparation of Extract

M. oleifera flower was air-dried at room temperature and thereafter pulverized. 50 g of the powder was extracted in 1000 ml of distilled water for 48 hours at room temperature with constant shaking. The filtrate obtained using Whatman No. 1 filter paper was lyophilized to give a yield of 5.12 g and a corresponding percentage yield of 10.24%.

Animal Grouping and Extract Administration

Twenty five male rats were randomly distributed into five groups A-E of five animals each. Rats in group A (control group) were orally administered with 1 ml of distilled water once daily with the aid of a metal oropharyngeal cannula. Those in groups B, C, D and E, were administered with 1.5 ml/kg body weight of carbon tetrachloride on the first day to induce hepatotoxicity. Then, group B was administered with 1 ml of distilled water while groups C, D and E were administered with 62.5, 125 and 250 mg/kg body weight of the aqueous extract of *M. oleifera* flower respectively for eleven days.

The study was conducted in line with the guidelines on the care and use of laboratory animals of the Ethical Committee of the Department of Biochemistry, University of Ilorin.

Preparation of Serum

Rats were anaesthetized in diethyl ether fumes. The jugular veins were cut and 5 ml of blood was collected in centrifuge tubes, allowed to clot for 10 minutes at room temperature and centrifuged at $685 \times g$ for 10 minutes. The clear serum was collected, stored at $-20\text{ }^{\circ}\text{C}$ and used within 12 hours of preparation.

Preparation of Tissue Supernatant

After sacrifice, the liver was isolated from the dissected rats. The isolated tissues were cleansed with blotting paper to remove blood stains and weighed, and then stored immediately in ice-cold 0.25 M sucrose solution. The liver was then subjected to homogenization using mortar and pestle in ice-cold 0.25 M sucrose solution (1:5^{w/v}). The homogenates were centrifuged at $33.5 \times g$ for 15 minutes and the supernatant decanted and frozen until required for further analysis.

Biochemical Studies

Determination of alanine aminotransferase (ALT) and aspartate aminotransferase (AST) activities was carried out using the method described by Reitman and Frankel (1957). The method described by Wright et al. (1972) was employed to determine alkaline phosphatase (ALP) activity. Superoxide dismutase (SOD) activity in liver homogenate was determined by the method of Misra and Fridovich (1972). Catalase (CAT) and gamma-glutamyl transferase (GGT) activities in the liver were determined according to the method described by Sinha (1972) and Szasz et al. (1969) respectively. Histological analysis was carried out on the liver as described by Krause (2001).

STATISTICAL ANALYSIS

Results were expressed as the mean \pm SD. Means were analyzed using a one way analysis of variance (ANOVA), followed by the Duncan Multiple Range Test to determine significant differences in all the parameters. Differences with values of $p < 0.05$ were considered statistically significant.

RESULTS

Figure 1 shows the effect of aqueous extract of *M. oleifera* flower on serum and liver alkaline phosphatase activities in CCl_4 -induced hepatotoxic rats. There was no significant

difference ($p > 0.05$) in serum ALP activity of rats administered 125 and 250 mg/kg b.w, aqueous extract of *M. oleifera* flower when compared with the control. In contrast, serum ALP activity of rats administered 1.5 ml/kg body weight of carbon tetrachloride, but untreated and those treated with 62.5 mg/kg b.w. of extract increased significantly ($p < 0.05$) when compared with the control. Liver ALP activity of rats administered 125 and 250 mg/kg b.w. aqueous extract of *M. oleifera* flower were not significantly different from the control. However, liver ALP activity of untreated rats and those administered 62.5 mg/kg b.w. aqueous extract of *M. oleifera* flower differed significantly ($p < 0.05$) relative to the control.

Figure 2 shows the effect of aqueous extract of *M. oleifera* flower on liver and serum aspartate aminotransferase (AST) and alanine aminotransferase (ALT) activities in CCl_4 -induced hepatotoxic rats. Serum AST activity of rats treated with aqueous extract of *M. oleifera* flower decreased significantly ($p < 0.05$) when compared with the control. There was no significant difference in liver AST activity of rats treated with aqueous extract of *M. oleifera* flower relative to the control. Similarly, there was no significant difference in serum ALT activity of rats administered 125 and 250 mg/kg b.w aqueous extract of *M. oleifera* flower when compared with the control. In contrast, serum ALT activity of rats administered 1.5 mg/kg b.w. of carbon tetrachloride, but untreated and those treated with 62.5 mg/kg b.w. aqueous extract of *M. oleifera* flower decreased significantly ($p < 0.05$) when compared with the control. There was no significant difference ($p > 0.05$) in liver ALT activity of rats administered 125 and 250 mg/kg b.w, aqueous extract of *M. oleifera* flower when compared with the control. However, liver ALT activity of rats treated with 62.5 mg/kg b.w. aqueous extract of *M. oleifera* flower increased significantly when compared with the control.

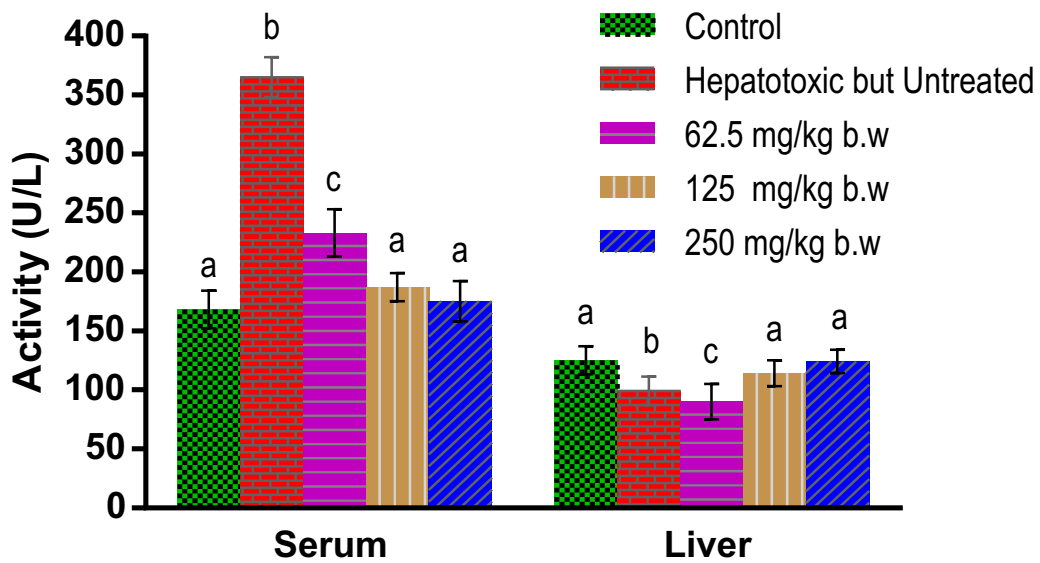


Figure 1: Effect of Aqueous Extract of Moringa oleifera Flower on Serum and Liver Alkaline Phosphatase Activities in CCl₄-induced Hepatotoxic Rats

Values are means (n = 5) ± SEM (bars with different superscripts are significantly different at p < 0.05)

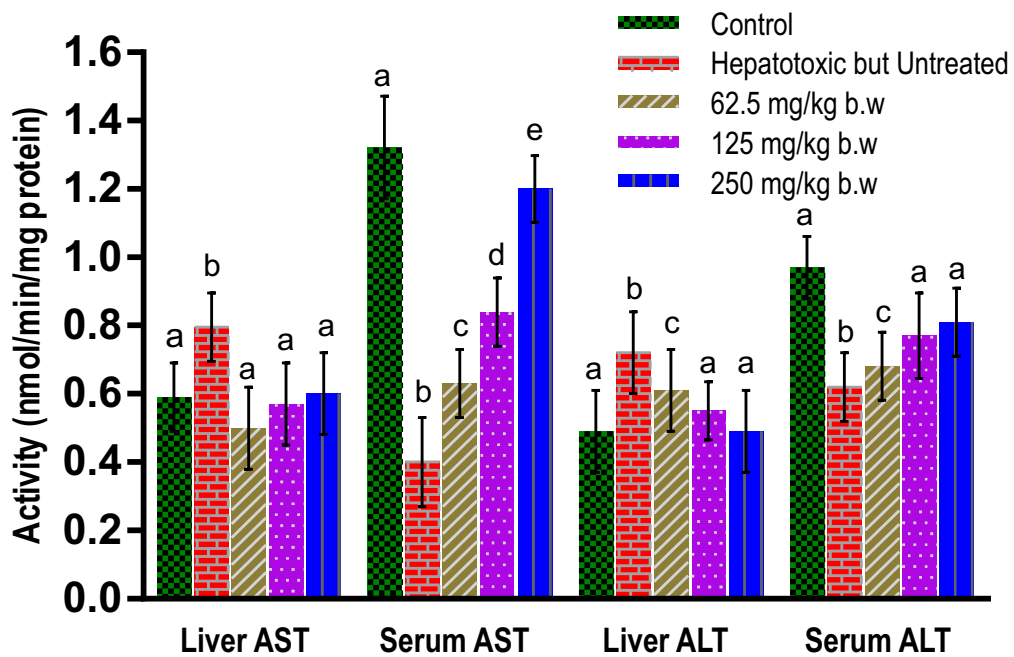


Figure 2: Effect of Aqueous Extract of Moringa oleifera Flower on Liver and Serum Alanine and Aspartate Aminotransferase Activities in CCl₄-induced Hepatotoxic Rats.

Values are means (n=5) ± SEM (bars with different superscript are significantly different at p < 0.05)

Table 1 shows the effect of aqueous extract of *M. oleifera* flower on liver GGT, catalase and SOD activities in CCl₄-induced hepatotoxic rats. Activities of liver SOD, catalase and GGT of rats treated with 250 mg/kg b.w. of aqueous extract of *M. oleifera* flower were not significantly different

from the control. However, liver SOD, CAT and GGT activities of rats treated with 62.5 and 125 mg/kg b.w. of aqueous extract of *M. oleifera* flower reduced significantly (p < 0.05) when compared with the control.

Table 1: Effect of Aqueous Extract of *Moringa oleifera* Flower on Liver GGT, Catalase and SOD Activities in CCl₄-induced Hepatotoxic Rats

Group	GGT (U/L)	CATALASE (nmol/min/mg protein)	SOD (nm ol/min/mg protein)
Control	1258 ± 30.00 ^a	0.50 ± 0.20 ^a	1.33 ± 0.20 ^a
Hepatotoxic but untreated	2345 ± 24.50 ^c	0.23 ± 0.03 ^c	0.40 ± 0.10 ^c
Hepatotoxic + 62.5 mg/kg b.w extract	567 ± 32.10 ^{bc}	0.42 ± 0.12 ^{bc}	0.63 ± 0.30 ^{bc}
Hepatotoxic + 125 mg/kg b.w extract	1001 ± 26.50 ^b	0.36 ± 0.11 ^b	0.84 ± 0.21 ^b
Hepatotoxic + 250 mg/kg b.w extract	1200 ± 43.20 ^a	0.49 ± 0.10 ^a	1.20 ± 0.27 ^a

Histopathology

Histological examinations are presented in plates A-E showing liver architecture of the normal, hepatotoxic but untreated as well as the aqueous extract of *M. oleifera* flower-treated groups of rats. Plate A shows normal liver architecture of the control group, without any degenerated hepatic cell. In contrast, plate B shows severely degenerated hepatic tissue architecture of untreated group of rats. The hepatic architecture

of plate C shows an inflamed and mild degenerated hepatocellular tissue of rats treated with 62.5 mg/kg b.w. of aqueous extract of *M. oleifera* flower. A moderately degenerated hepatocellular tissue of rats treated with 125 mg/kg b.w. of aqueous extract of *M. oleifera* flower is presented in plate D. Plate E shows mildly degenerated hepatocellular tissue of rats treated with 250 mg/kg b.w. of aqueous extract of *M. oleifera* flower.

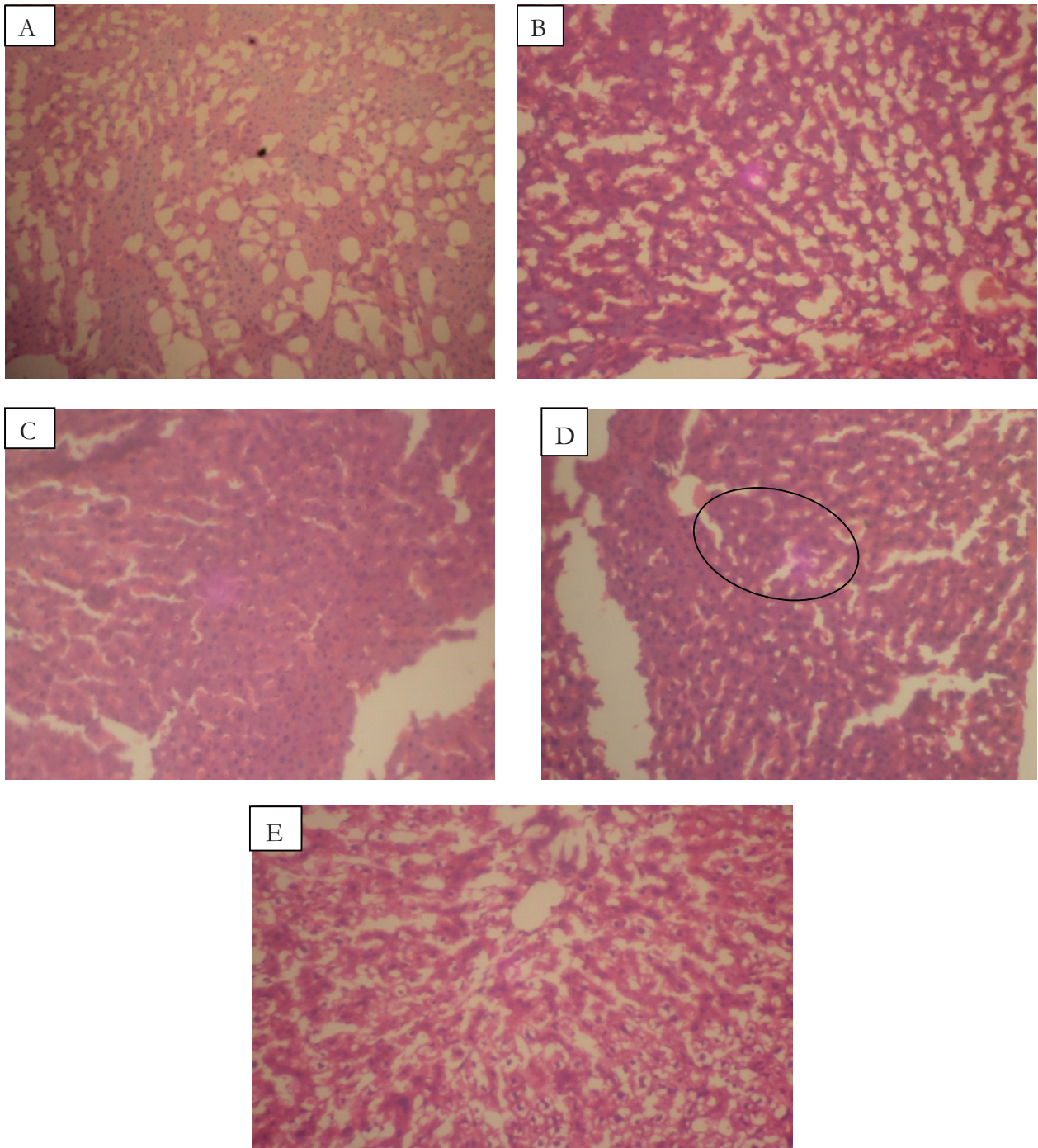


Plate A-E: Histopathology of Liver Tissue of Rats Following Administration of Aqueous Extract of *Moringa oleifera* Flowers (A): Photomicrograph of hepatic tissue of control group showing normal hepatocellular tissue [magnification $\times 200$]. (B): Photomicrograph of hepatic tissue area showing a severely degenerated hepatocellular tissue induced by administration of 1.5 ml/kg body weight carbon tetrachloride [magnification $\times 200$]. (C): Photomicrograph of hepatic tissue showing an inflamed and mildly degenerated hepatocellular tissue of rats treated with 62.5 mg/kg body weight of aqueous extract of *Moringa oleifera* flowers [magnification $\times 200$]. (D): Photomicrograph of hepatic tissue showing a moderately degenerated hepatocellular tissue of rats treated with 125 mg/kg body weight of aqueous extract of *Moringa oleifera* flowers [magnification $\times 200$]. (E): Photomicrograph of hepatic tissue showing mildly degenerated hepatocellular tissue of rats treated with 250 mg/kg body weight of aqueous extract of *Moringa oleifera* flowers [magnification $\times 200$].

DISCUSSION

Carbon tetrachloride is one of the most commonly used hepatotoxins in the experimental study of liver diseases. The hepatotoxic effects of CCl_4 are largely due to its active metabolite, trichloromethyl radical (Palanivel et al., 2008) which is probably a product of cytochrome P_{450} activity on CCl_4 (Çetin et al., 2011). These activated radicals bind covalently to the macromolecules and induce peroxidative degradation of membrane lipids of endoplasmic reticulum rich in polyunsaturated fatty acids. This leads to the formation of lipid peroxides. This lipid peroxidative degradation of biomembranes is one of the principal causes of hepatotoxicity induced by CCl_4 (Kaplowitz et al., 1986). This is evidenced by elevation in the activities of the serum marker enzymes such as AST, ALT and ALP.

In mammals, ALP is found mainly in the liver, bones and kidney. The significant increase in serum ALP activity of rats administered 1.5 ml/kg body weight of carbon tetrachloride, but untreated and those treated with 62.5 mg/kg b.w. of aqueous extract of *M. oleifera* flower could be as a result of damage to the membrane of the hepatocytes, cholestasis or rapid enzyme synthesis along with increasing biliary pressure (Toori et al., 2013). This observation is supported by the fact that, there was significant and concomitant reduction ($p < 0.05$) in the liver ALP activity of rats administered 1.5 ml/kg body weight of carbon tetrachloride, but not treated and those treated with 62.5 mg/kg b.w. of aqueous extract of *M. oleifera* flower. This observation may be due to leakage of the enzyme into the plasma as a result of damage to the membrane of the hepatocytes (Akanji et al., 1993). The results indicate that rats administered 1.5 ml/kg body weight of carbon tetrachloride experienced severe hepatic damage when compared to the control and rats treated with aqueous extract of *M. oleifera* flower. The hepatoprotective capacity of aqueous extract of *M. oleifera* flower appears to be dose-dependent, as there was no significant difference in serum and liver ALP activities of rats treated with 125 and 250 mg/kg b.w. of the extract when compared with the control. This observation could be as a result of repair of damaged tissue caused by hepatotoxic

compounds (Arise et al., 2016) or a depressed bioactivation of CCl_4 (Çetin et al., 2011).

ALT and AST are well-known diagnostic indicators of liver disease. In cases of liver damage with hepatocellular lesions and parenchymal cell necrosis, these marker enzymes are released from the damaged tissues into the blood stream (Santhosh et al., 2007). In the assessment of liver damage by CCl_4 , determination of activities of enzymes such as AST and ALT, is largely used (Palanivel et al., 2008). Significant decrease in serum AST activity of rats treated with aqueous extract of *M. oleifera* flower may indicate increased clearance of the enzyme from the plasma (Kristensen, 1994). Liver and serum ALT activity of rats treated with 125 and 250 mg/kg b.w. aqueous extract of *M. oleifera* flower were comparable to the control. This observation suggests that aqueous extract of *M. oleifera* flower hepatoprotective activity may be due to the prevention of leakage of intracellular enzymes of the hepatocyte by stabilizing its membrane. This is in agreement with the notion that serum levels of aminotransferases tend towards normalcy with the healing of hepatic parenchyma and regeneration of liver cells (Thabrew et al., 1987).

One of the principal causes of CCl_4 -induced liver injury is formation of lipid peroxides by free radical derivatives of CCl_4 (CCl_3 free radical). Thus, the antioxidant activity or the inhibition of generation of free radicals is important in the protection against CCl_4 -induced hepatopathy (Amer et al., 2015). The body has an effective defense mechanism to prevent and neutralize the free radical-induced damage. This is accomplished by a set of antioxidant enzymes such as SOD, CAT and GGT (Lee et al., 2004). In this study, the increased GGT activity in CCl_4 -induced hepatotoxic but untreated rats indicates lipid peroxidation leading to tissue damage and failure of antioxidant defence mechanism to prevent formation of excessive free radicals (Lee et al., 2004). The observed decrease in the liver activities of SOD and CAT of animal induced by acute administration of CCl_4 may be attributed to oxidative inactivation of enzyme protein by excess ROS generation. Restoration of SOD, CAT and GGT levels towards values that were not significantly ($p > 0.05$) different from that of the

control, achieved by the administration of 250 mg/kg b.w extract, suggests its hepatoprotective effect.

The histological results reported in the current study confirmed the biochemical results and indicated that CCl₄ induced severe histological changes in the hepatic tissues. The histological architecture of the liver section showed fatty degeneration of hepatocytes. Similar histological changes in the liver have been documented in previous studies (Çetin et al., 2011). The acute hepatotoxic effects induced by CCl₄ administration were confirmed histopathologically, revealing extensive hepatocellular degeneration and necrosis, inflammatory cell infiltration, congestion, and sinusoidal dilatation.

CONCLUSION

The results obtained from this study show that oxidative stress induced by CCl₄ exhibited detrimental effects on the experimental animals by causing hepatocellular and hepatic injury as well as imbalances in enzyme distribution while the aqueous extract of *M. oleifera* flower at doses of up to 250 mg/kg b.w displayed remarkable hepatoprotective potential underlining its ability to prevent and/or reverse the injuries associated with the adverse effect of CCl₄.

REFERENCES

- Akanji, M. A., Olagoke, O. A., Oloyede, O. B. (1993). Effect of chronic consumption of metabisulphite on the integrity of the rat kidney cellular system. *Toxicology*, 81(3): 173-179.
- Al-Malki, A. L. and El Rabey, H. A. (2015). The antidiabetic effect of low doses of *Moringa oleifera* Lam. Seeds on streptozotocin induced diabetes and diabetic nephropathy in male rats. *BioMedical Research International*, vol. 2015, 381040, 13 pages.
- Amaglo, N. K., Bennett, R. N., Lo Curto, R. B., Rosa, E. A. S., Lo Turco, V., Giuffrida, A., Lo Curto A., Crea F., Timpo, G. M. (2010). Profiling selected phytochemicals and nutrients in different tissues of the multipurpose tree *Moringa oleifera* L., grown in Ghana. *Food Chemistry*, 122(4): 1047-1054.
- Amer, M. A., EL-missiry, M. A. and rab EL-nabi, A. A. (2015). The Role of *Ficus carica* leaf extract in modulation of the experimentally induced hepatotoxic damage in male rats. *International Journal of Advanced Research*, 3(12): 572-585.
- Arise, R. O., Akapa, T., Adigun, M. A., Yekeen, A. A. and Oguntibeju, O. O. (2016). Normoglycaemic, normolipidaemic and antioxidant effects of ethanolic extract of *Acacia ataxacantha* root in streptozotocin-induced diabetic rats. *Notulae Scientia Biologicae*, 8(2): 144-150.
- Çetin, E., Kanbur, M., Çetin, N., Eraslan, G. and Atasever, A. (2011). Hepatoprotective effect of ghrelin on carbon tetrachloride-induced acute liver injury in rats. *Regulatory peptides*, 171(1): 1-5.
- Fahey, J. W. (2005). *Moringa oleifera*: a review of the medical evidence for its nutritional, therapeutic, and prophylactic properties. Part 1. *Trees for Life Journal*, 1(5): 1-15.
- Guevara, A. P., Vargas, C., Sakurai, H., Fujiwara, Y., Hashimoto, K., Maoka, T., Kozuka M., Ito Y., Tokuda H., and Nishino, H. (1999). An antitumor promoter from *Moringa oleifera* Lam. *Mutation Research/Genetic Toxicology and Environmental Mutagenesis*, 440(2): 181-188.
- Hashemi, J. M. (2014). *Hibiscus sabdariffa* calyx extract alleviate hepatotoxicity induced by carbon tetrachloride on male albino rats. *Nature and Science*, 12(6): 111-120.
- Huo, H. Z., Wang, B., Liang, Y. K., Bao, Y. Y. and Gu, Y. (2011). Hepatoprotective and antioxidant effects of licorice extract against CCl₄-induced oxidative damage in rats. *International Journal of Molecular Sciences*, 12(10): 6529-6543.
- Kaplowitz, N., Aw, T. Y., Simon, F. R. and Stolz, A. (1986). Drug-induced hepatotoxicity. *Annals of Internal Medicine*, 104(6): 826-839.
- Krause, W. J. (2001). *The art of examining and interpreting histologic preparations: A Student Handbook*: CRC Press.
- Kristensen, S.R. (1994). Mechanisms of cell damage and enzyme release. *Danish Medical Bulletin* 41(4), 423-433.

- Kshirsagar, A., Vetal, Y., Ashok, P., Bhosle, P. and Ingawale, D. (2009). Drug induced hepatotoxicity: a comprehensive review. *Internet Journal of Pharmacology*, 1: 1-19.
- Lee, D., Ha, M., Kim, K., Jin, D. and Jacobs, D. (2004). Gamma-glutamyltransferase: an effect modifier in the association between age and hypertension in a 4-year follow-up study. *Journal of Human Hypertension*, 18(11): 803-807.
- Misra, H. P. and Fridovich, I. (1972). The role of superoxide anion in the autoxidation of epinephrine and a simple assay for superoxide dismutase. *Journal of Biological Chemistry*, 247(10): 3170-3175.
- Muluvi, G. M., Sprent, J., Soranzo, N., Provan, J., Odee, D., Folkard, G., Mcnicol J.W., and Powell, W. (1999). Amplified fragment length polymorphism (AFLP) analysis of genetic variation in *Moringa oleifera* Lam. *Molecular Ecology*, 8(3): 463-470.
- Ostapowicz, G., Fontana, R. J., Schiødt, F. V., Larson, A., Davern, T. J., Han, S. H., McCaashland T. M., Shakil, A. O., Hay, J. E., Hynan, L., Crippin, J. S., Blei, A. T., Samuel, G., Reisch, J., and Lee, W. M. (2002). Results of a prospective study of acute liver failure at 17 tertiary care centers in the United States. *Annals of Internal Medicine*, 137(12): 947-954.
- Palanivel, M. G., Rajkapoor, B., Kumar, R. S., Einstein, J. W., Kumar, E. P., Rupesh Kumar, M., Kavitha K., Pradeep Kumar M., and Jayakar, B. (2008). Hepatoprotective and antioxidant effect of *Pisonia aculeata* L. against CCl₄-induced hepatic damage in rats. *Scientia Pharmaceutica*, 76(2): 203.
- Reitman, S. and Frankel, S. (1957). Determination of glutamate-pyruvate transaminase (ALT) and aspartate aminotransfrase (AST). *Journal of Clinical Pathology*, 28: 56.
- Santhosh, S., Sini, T. K., Anandan, R. and Mathew, P. T. (2007). Hepatoprotective activity of chitosan against isoniazid and rifampicin-induced toxicity in experimental rats. *European Journal of Pharmacology*, 572(1): 69-73.
- Sherman, K. E. (1991). Alanine aminotransferase in clinical practice: a review. *Archives of Internal Medicine*, 151(2): 260-265.
- Singh, N., Kamath, V., Narasimhamurthy, K. and Rajini, P. (2008). Protective effect of potato peel extract against carbon tetrachloride-induced liver injury in rats. *Environmental Toxicology and Pharmacology*, 26(2): 241-246.
- Sinha, A. K. (1972). Colorimetric assay of catalase. *Analytical biochemistry*, 47(2): 389-394.
- Szasz, G., Rosenthal, P. and Fritzsche, W. (1969). Gamma-glutamyl-transpeptidase, leucine aminopeptidase and alkaline phosphatase. Comparison of 3724 serums. *Schweizerische medizinische Wochenschrift*, 99(16): 606-608.
- Thabrew, M. I., Joice, P. and Rajatissa, W. (1987). A comparative study of the efficacy of *Pavetta indica* and *Osbeckia octandra* in the treatment of liver dysfunction. *Planta Medica*, 53(03): 239-241.
- Toori, M. A., Mirzaei, M., Mirzaei, N., Lamrood, P. and Mirzaei, A. (2013). Antioxidant and hepatoprotective effects of the internal layer of oak fruit (Jaft). *Journal of Medicinal Plants Research*, 7(1): 24-28.
- Wright, P., Leathwood, P. and Plummer, D. (1972). Enzymes in rat urine: alkaline phosphatase. *Enzymologia*, 42(4): 317-327.