



Internet Journal of Medical Update

Journal home page: <http://www.akspublication.com/ijmu>

Original Work

A Different Technique of Primary Indirect Inguinal Hernia Repair by Inserting a Synthetic Mesh into the Pre and Retroperitoneal Spaces to Wrap the Peritoneal Reflection: Preliminary Report

Professor Aydın Altan^Ψ MD

Department of General Surgery, Faculty of Medicine, Trakya University, Edirne, Turkey

(Received 26 January 2009 and accepted 25 May 2009)

ABSTRACT: In most methods of indirect inguinal hernia repair, the region of the sac stump remains a potential site of recurrence. A different technique that covers the site of the indirect sac stump is presented. Anterior parietal peritoneum is reflected posteriorly in the inguinal canal. In cases with Gilbert type I-II inguinal hernia, after the indirect sac is removed, the pre and retroperitoneal spaces in this region are dissected. A synthetic mesh is placed into these spaces, lateral to the inferior epigastric vessels. The posterior wall of this type hernia is intact. In cases with Gilbert type III inguinal hernia, either posterior wall repair is accomplished by using one of the tissue approximation techniques after placing a mesh in the region of the sac stump, or the entire peritoneal reflection in the inguinal canal is wrapped with a mesh after dissecting the pre and retroperitoneal spaces. This technique was performed in five patients. Of five patients, mesh was inserted on the region of stump in three (Gilbert I and II) and along the entire peritoneal reflection in two (Gilbert III). There were no postoperative complications such as seroma and pain and no recurrence till follow-up. This technique effectively wraps the peritoneal reflection and may prevent recurrences in primary indirect inguinal hernia, but it needs to be performed in a large number of cases for further evaluation.

KEY WORDS: Inguinal hernia; Indirect; Repair; Mesh

INTRODUCTION

Indirect inguinal hernia consists of a sac of peritoneum protruding through the internal ring, anterolateral to the spermatic cord or round ligament, through which intra-abdominal organs can enter. Direct hernia is a bulging as a result of weakness of the posterior wall of the inguinal canal, anywhere from the internal ring to the pubic tubercle, medial to the inferior epigastric vessels.¹ There is a wide variety of surgical methods for the treatment of

inguinal hernia. The optimum method for inguinal hernia repair has not yet been determined.^{2,3} The options for reconstruction of the inguinal floor consist of pure tissue approximation repairs and prosthetic material repairs. Recurrences following hernia repair have been a significant problem. Synthetic meshes are being increasingly used in hernia repair to prevent recurrences.⁴ In most methods of indirect inguinal hernia repair, the region of the indirect sac stump, which is at the peritoneal reflection, remains a potential site of recurrence. In the present technique of repair of primary indirect inguinal hernia, the region of the indirect sac stump is covered by pre and retroperitoneal placement of a synthetic mesh.

^Ψ**Correspondence at:** Demirkapi Mevkii, Avrupa Kent, E Adasi, 2-3, Edirne, Turkey
Phone Number: +90 542 594 2365
Email: aydinal@ttmail.com

METHODOLOGY

Technique

An oblique inguinal incision approximately 6 cm in length and 2 cm superomedial to the inguinal ligament is made. The lateral end of the incision is at the point midway between the pubic tubercle and the anterior superior iliac spine. Mobilization of the spermatic cord is performed in the proper plane avoiding damage to the transversalis fascia (**Figure 1**). The indirect sac is completely dissected and opened (**Figure 2**). A palpating finger is introduced into the peritoneal cavity through the open sac to grade the sac orifice according to the classification recommended by Gilbert, and to assess the posterior wall of the canal.⁵ A transfixion suture-ligation of the neck of the sac is performed by using polypropylene suture material and the excess sac is removed (**Figure 3**). The cremasteric muscle fibers around the internal ring are divided so that the internal oblique and transversalis muscle edges

at this region are freed. The ilioinguinal nerve is preserved during this procedure.

Traction is applied on the sac stump by pulling the strands of the suture-ligature and the pre and retroperitoneal spaces around the sac stump are bluntly dissected approximately 5 to 6 cm. in the cephalad direction, and from the inferior epigastric vessels medially to the inguinal ligament laterally so that the cord structures have been freed from the retroperitoneum with the dissection of the retroperitoneal space and a slit in the mesh is not required (**Figure 4, 5**). A synthetic mesh is fashioned approximately 10x6 cm in length and width to fit the dissected spaces. The strands of suture-ligature are passed through the center of the mesh (**Figure 6**). The mesh is pushed down to the stump and placed into the pre and retroperitoneal spaces and then the ligature is tied down so that the peritoneal reflection with the sac stump is partially wrapped lateral to the inferior epigastric vessels (**Fig 7, 8, 9, and 10**).

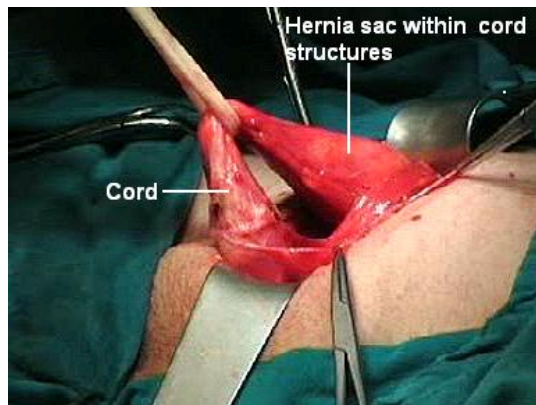


Figure 1: Left indirect inguinal hernia; Mobilization of the spermatic cord

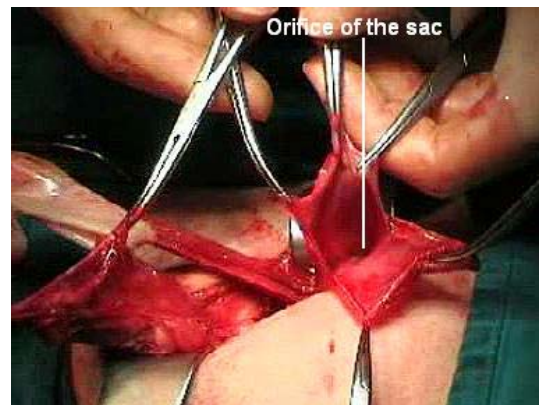


Figure 2: The indirect sac is dissected and opened; Gilbert II type of hernia

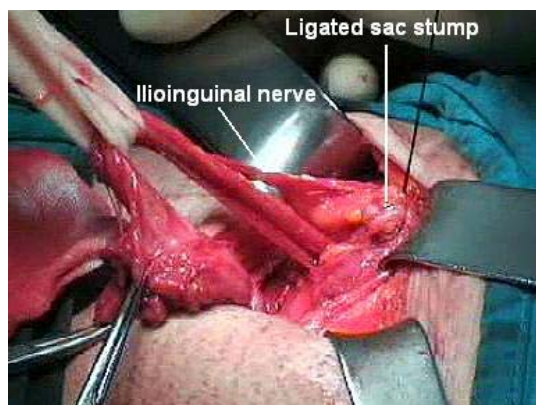


Figure 3: Ligated sac stump

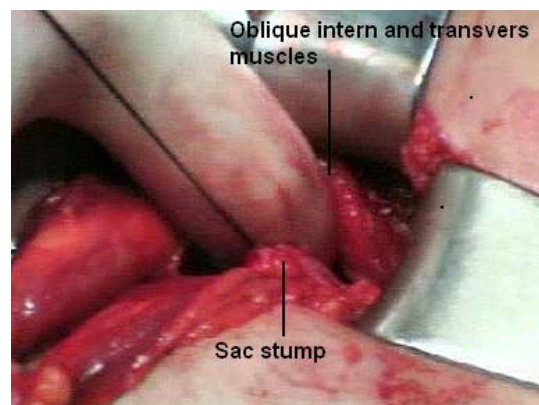


Figure 4: Finger dissection of the preperitoneal space

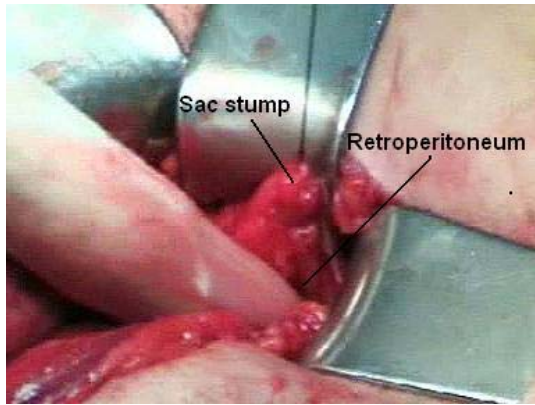

Figure 5: Finger dissection of the retroperitoneal space

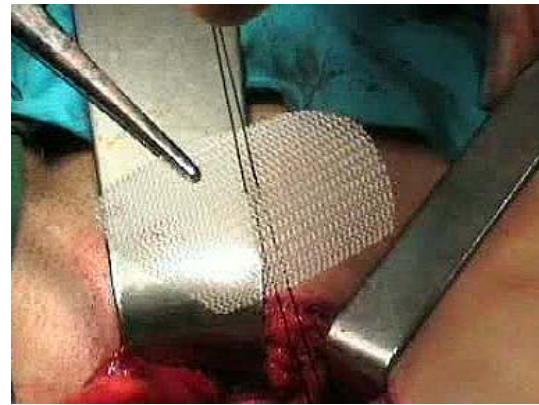

Figure 6: The strands of ligature is passed through the center of the mesh

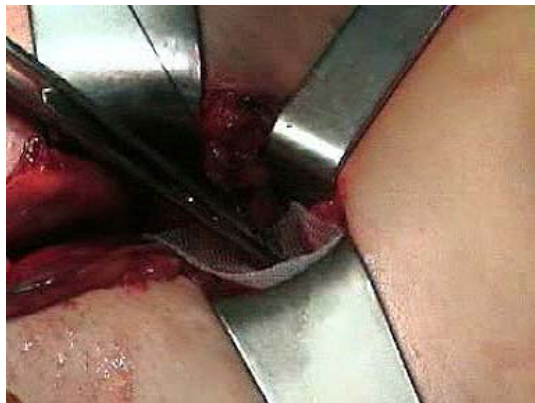

Figure 7: The mesh is placed preperitoneal space

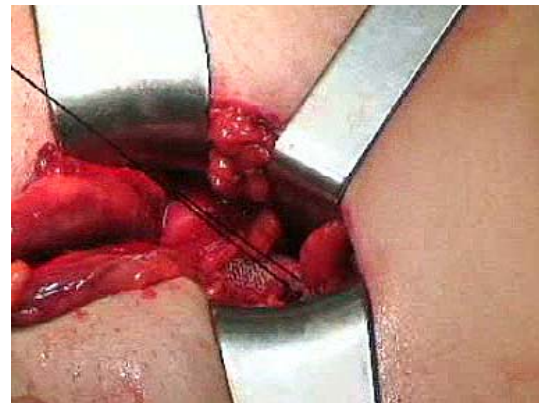

Figure 8: The mesh placed pre and retroperitoneal spaces

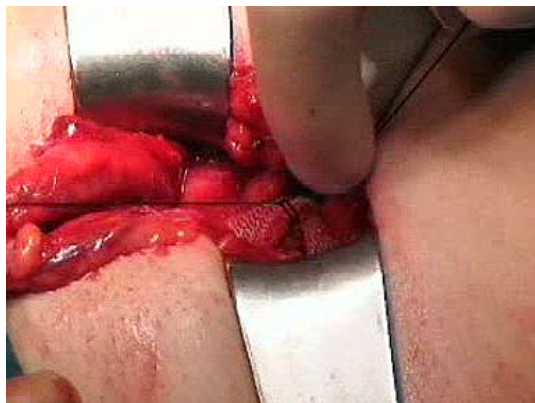


Figure 9: The ligature is tied on

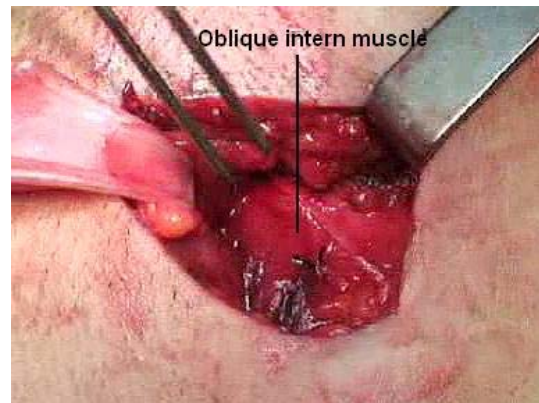

Figure 10: Completion of the operation; Mesh is under the muscles

The synthetic mesh of choice is polyester fiber because it stays in place without sutures.¹ If semi-rigid polypropylene mesh is substituted for polyester, the four corners of the mesh need to be fixed by suture. Firstly, the posterior two are sutured to the retroperitoneal connective tissue by retracting the peritoneal reflection upward, and then the anterior two are sutured to the under surface of transversalis muscle by retracting the muscle upward. Fibrin sealant

can be used as an alternative method of fixation.

In patients with an intact posterior inguinal canal floor (Gilbert type I-II hernia), nothing further is done. In patients with Gilbert type III inguinal hernia, posterior wall repair is accomplished by using one of the tissue approximation methods, after placing of a mesh in the region of the sac stump lateral to the inferior epigastric vessels as mentioned

previously. If the tissues of the patient are weak and unsuitable for posterior wall repair, the inferior epigastric vessels are divided, the pre and retroperitoneal spaces from the pubic tubercle to the inguinal ligament are dissected

and then a large synthetic mesh is placed into these spaces so that the entire peritoneal reflection in the inguinal canal is wrapped. **Figure 11** shows schematic diagram of this technique.

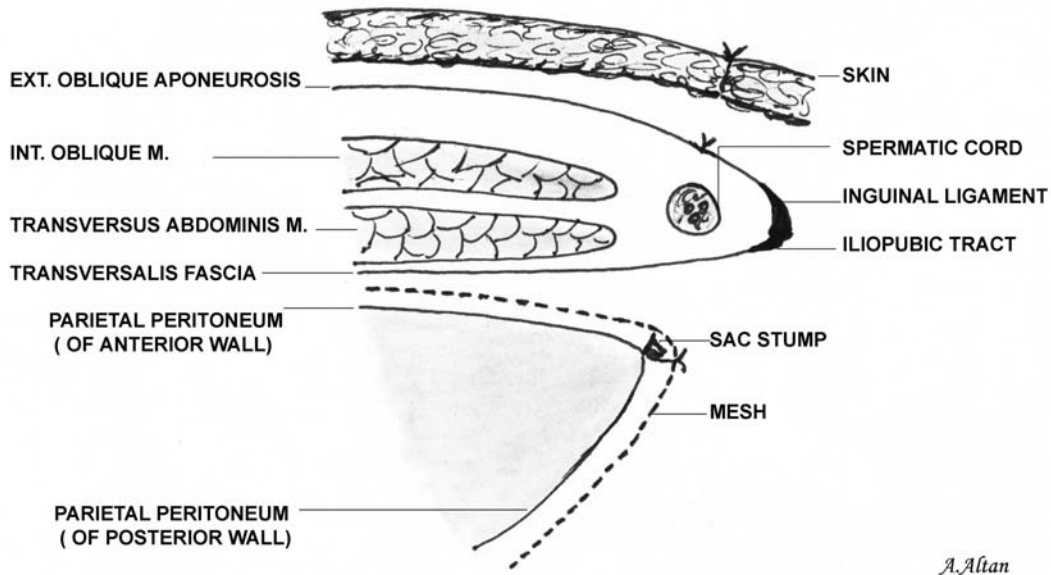


Figure 11: Schematic diagram of the operation

Patients

Between May 2005 and April 2008, a total of five patients with unilateral primary indirect inguinal hernia were operated upon by this procedure. The details of the operation were explained to the patients and informed consent was obtained.

Patients were operated under epidural anesthesia. Three of the five patients had Gilbert type I and II inguinal hernias (their ages: 33, 40 and 82 years). The peritoneal reflection lateral to the inferior epigastric vessels was wrapped with polyester mesh in these patients. The other two had Gilbert type III inguinal hernias (their ages: 34 and 65 years) and the entire peritoneal reflection in the inguinal canal was wrapped with polypropylene mesh. The mesh was fixed by using polypropylene suture material. All patients were followed up at three-month intervals till November 1, 2008 and were examined in the outpatient clinic.

RESULTS

The mean operation time was 35 minutes. Early postoperative course was uneventful. The patients were discharged from the hospital on the third day and returned to work after two

weeks. There were no pain, seroma and hernia recurrences during follow-up.

DISCUSSION

The efficacy of groin hernia repair is mainly evaluated by its recurrence rate.⁶ The recurrence rates have been reported as being from 1 to 3 percent in a 10-year follow-up by very experienced hernia surgeons using classical repairs.^{1,7,8} The recurrence rates for primary inguinal hernia repair are lower than those for direct and recurrent inguinal hernia by various methods.

Gilbert type I, II and III inguinal hernias are indirect.⁵ In repairing of Gilbert type I and II primary inguinal hernias by using tissue approximation repair or tension-free synthetic mesh application technique, the posterior wall of the inguinal canal is reinforced despite intact inguinal floor and the site of sac stump remains a potential site for peritoneal protrusion.

Parietal peritoneum covering the anterior abdominal wall is reflected posteriorly in the inguinal canal and it is known as visceral sac. Therefore, the orifice of the indirect or direct hernia sac is usually in the region of peritoneal reflection. In the present technique, region of the indirect sac stump localized lateral to the inferior epigastric vessels is wrapped by pre

and retroperitoneal placing of a synthetic mesh. A slit in the mesh to accommodate the spermatic cord is not required because the elements of the spermatic cord have been dissected from the peritoneum.

In the technique of giant prosthetic reinforcement of the visceral sac (GPRVS or Stoppa Procedure), a large synthetic mesh without slit is implanted in the preperitoneal space via a midline or Pfannenstiel incision bilaterally or unilaterally. The mesh extends far beyond the borders of the myopectineal orifice so that it smoothly envelopes the visceral sac.^{9,10} The laparoscopic totally extraperitoneal repair (TEP) uses exactly the same principles as the Stoppa repair.¹¹

In Kugel hernia repair, the mesh is placed preperitoneally through a 3-cm inguinal incision after blunt dissection of the preperitoneal space. Much like the laparoscopic repair, it covers the direct, indirect and femoral spaces. Approximately 3/5 of the patch is above the level of the inguinal ligament and the remaining 2/5 below the level of the ligament so that the posterior edge of the mesh lies smoothly on the iliac vessels.^{12,13}

In the technique of cone-shaped plug mesh, the site of indirect sac stump is not covered largely; instead the internal ring is only plugged. A mesh similar to Lichtenstein repair is inserted in the floor of the inguinal canal to reinforce the plug mesh (Gilbert's sutureless hernioplasty), but this patch is slit to accommodate the spermatic cord elements.^{14,15}

In the present technique, in patients with Gilbert type I and II primary inguinal hernia the mesh is only placed on the site of indirect sac stump and its posterior edge is inserted more proximal in the retroperitoneal space than the Stoppa and Kugel techniques so that the visceral sac lateral to the inferior epigastric vessels is efficiently wrapped. It is not necessary to repair the posterior wall because it is intact in this type of hernia. In a previous study of ours, high ligation was only performed in thirteen patients with Gilbert type I and II primary inguinal hernia and they were followed up for two to six years. Indirect hernia recurred in one patient three months after operation.¹⁶ Therefore, it seems to be important to cover the site of indirect sac stump.

In patients with Gilbert type III inguinal hernia, performing one of the classical tissue approximation repair techniques, such as Marcy's simple ring closure or Bassini hernioplasty, will suffice after wrapping the site of indirect sac stump lateral to the inferior epigastric vessels with synthetic mesh. If the

tissues of the patient are unsuitable for repair of the posterior wall of the inguinal canal, the inferior epigastric vessels are divided. After dissecting the pre and retroperitoneal spaces from the pubic tubercle to the inguinal ligament, a synthetic mesh is inserted into these spaces and the entire visceral sac in the inguinal canal is effectively wrapped.

CONCLUSION

In the present technique, the extent of dissection of the retroperitoneal space is greater and wrapping of the peritoneal reflection therefore seems logically more effective than the other methods. In patients with Gilbert type I and II inguinal hernias, wrapping only the site of sac stump, lateral to the inferior epigastric vessels, may suffice in preventing recurrences. For definitive evaluation, it is necessary to perform this procedure in a large number of patients.

REFERENCES

1. Wantz GE. Abdominal wall hernias. Schwartz's Principles of Surgery, 7th edition. Mc Graw-Hill Co, New York, St.Louis, San Francisco 1999:1585-611.
2. Schwab JR, Beaird DA, Ramshaw BJ, et al. After 10 years and 1903 inguinal hernias, what is the outcome for the laparoscopic repair? *Surg Endosc.* 2002;16(8):1201-6.
3. Tseng CC, Lin AD. Triple-combined herniorrhaphy for inguinal hernia repair: experience of 1411 cases. *Hepatogastroenterology.*2007;54(77):1433-7.
4. Sakorafas GH, Halikias I, Nissotakis C, et al. Open tension free repair of inguinal hernias; the Lichtenstein technique. *BMC Surg.* 2001;1:3.
5. Gilbert AI. An anatomic and functional classification for the diagnosis and treatment of inguinal hernia. *Am J Surg.* 1989;157(3):331-3.
6. Boudet MJ, Perniceni T. Inguinal hernia treatment. *J Chir (Paris).* 1988;135(2):57-64.
7. Dieudonné G. Plug repair of groin hernias: a 10-year experience. *Hernia.* 2001;5(4):189-91.
8. Wara P, Bay-Nielsen M, Juul P, et al. Prospective nationwide analysis of laparoscopic versus Lichtenstein repair of inguinal hernia. *Br J Surg.* 2005;92(10):1277-81.
9. Stoppa RE. The preperitoneal approach and prosthetic repair of groin hernias. In:

- Nyhus LM, Condon RE(eds): *Hernia*, 4th ed. Philadelphia, JB Lippincott; 1995;188-206.
10. Stoppa RE. Wrapping the visceral sac into a bilateral mesh prosthesis in groin hernia repair. *Hernia*. 2003;7(1):2-12.
 11. Beets GL, Dirksen CD, Go PM, et al. Open or laparoscopic preperitoneal mesh repair for recurrent inguinal hernia? A randomized controlled trial. *Surg Endosc*. 1999;13(4):323-7.
 12. Kugel RD. The Kugel repair for groin hernias. *Surg Clin North Am*. 2003;83(5):1119-39.
 13. Ceriani V, Faleschini E, Bignami P, et al. Kugel hernia repair: open “mini-invasive” technique. Personal experience on 620 patients. *Hernia*. 2005;9(4):344-7.
 14. Gilbert AI. Sutureless repair of inguinal hernia. *Am J Surg*. 1992;163(3):331-5.
 15. Wantz GE. Experience with the tension-free hernioplasty for primary inguinal hernias in men. *J Am Coll Surg*. 1996;183(4):351-6.
 16. Altan A, Goney E, Goker B, et al. Two to six years follow-up study of Bassini technique and anatomic repair performed in patients with primary indirect inguinal hernia. *Cerrahpasa Tip Fakultesi Dergisi*. 1985;16(3-4):162-5.