



Internet Journal of Medical Update

Journal home page: <http://www.akspublication.com/ijmu>

Original Work

Histomorphologic alterations of the cerebellum of Wistar rats following Amodiaquine plus Artesunate administration

Mr. M. B. Ekong[†], Mr. A. O. Igiri[†], and Mr. A. O. Egwu^{‡,‡}

[†]Department of Anatomy, Faculty of Basic Medical Sciences, University of Calabar, Calabar, Nigeria

[‡]Department of Anatomy, Faculty of Basic Medical Sciences, Ebonyi State University, Abakiliki, Nigeria

(Received 12 August 2008 and accepted 10 October 2008)

ABSTRACT: Amodiaquine and artesunate are two antimalarial drugs sold in combination as Larimal[®]. This drug is a very effective artemisinin-base combination. This study was to access the effects of amodiaquine and artesunate combination on the histology of the cerebellum. Twenty adult Wistar rats weighing between 150-180g were divided into four groups (A, B, C and D) of five animals each. Group A served as the control and the animals received distilled water, while group B received 8.75+2.86mg/kg of amodiaquine and artesunate combination for three days, group C received 8.75+2.86mg/kg of amodiaquine and artesunate combination for six days and group D received 17.50+5.71mg/kg of amodiaquine and artesunate combination for three days. Histological sections showed destruction of the Purkinje cortical layers in group B, with increased destructions in groups C and D compared to the control. These results reveal that amodiaquine and artesunate combination causes histological alterations, which were dose and time dependent and these may result in cerebellar dysfunction.

KEY WORDS: Amodiaquine; Artesunate; Histopathological alterations; Cerebellum; Larimal; Wistar rats

INTRODUCTION[‡]

Amodiaquine *plus* artesunate combination popularly sold as Larimal[®], is a combination of amodiaquine (AQ) 153.1mg, and artesunate (AS) 50mg, and has been increasingly used in the treatment of uncomplicated malaria caused by *Plasmodium falciparum*. The action of this drug is seen in its constituting drugs, AQ and AS¹. AQ is a 4-aminoquinoline antimalarial drug with schizonticidal activity and a similar mode of action to chloroquine. It also possesses antipyretic and anti-inflammatory properties and is effective against the erythrocytic stages of all

four species of *Plasmodium falciparum*^{1, 2}. The mode of AQ action is immune mediated³. This has earlier been reported⁴, where AQ gave rise to chemically reactive species by at least three distinct mechanisms, viz. autoxidation in neutral solution under air, peroxidase-catalyzed oxidation and N-chlorination.

In therapeutic doses used for prophylaxis and for malaria therapy, AQ has been reported to occasionally cause peripheral neuropathy, and vertigo and lethargy occasionally¹. Large doses of AQ have been reported to cause syncope, spasticity, convulsion and involuntary movements. The usual sign and symptoms of an overdose are headache, vertigo and vomiting¹.

Artesunate on the other hand is a water-soluble hemisuccinate derivative of artemisinin. It is

[‡] Correspondence at: egwuoc@yahoo.com

made of endoperoxide bond, which is the functional group responsible for the antimalarial activity of AS¹. The mechanism of action involves the heme-mediated decomposition of the endoperoxide bond to produce carbon-centered free radicals. Release of these active oxygen species from this bond kills the parasite if accumulated in the erythrocytes⁵. Neurotoxicity has been observed in animal studies but not in humans⁶. Other possible effects include; dizziness, headache, body ache, tinnitus and convulsions with cardiotoxicity observed in high doses¹. In animal studies, neurologic defects such as gait disturbances, loss of spinal and pain reflexes⁷, prominent loss of brain stem and eye reflexes and prominent neuropathic lesions sharply limited to the brain stem⁷⁻⁹, ataxia and slurred speech¹⁰ have been reported with artesunate.

With these facts in mind, this work was carried out to determine the possible effect of amodiaquine in combination with artesunate on the histology of the cerebellum of Wistar rats.

MATERIALS AND METHODS

Twenty adult Wistar rats weighing between 150-180g were divided into four groups (A, B, C and D) of five animals each. Each packet of Larimal[®] contained twelve blister tablets each of AQ Hydrochloride USP equivalent to AQ base (153.1mg) and AS (50mg).

The drugs were given orally using orogastric tubes. The dosages were in milligram per kilogram body weight (mg/kg) given twelve hourly (twice a day) using distilled water as the vehicle. The treatment lasted three days for groups B and D, and six days for group C animals. Group A served as the control and the animals received distilled water. These are seen in **Table 1**.

Table 1: The Administration of the Drugs

Groups (n=5)	Treatment	Duration (days)
A	Distilled Water	3
B	8.75+2.86mg/kg of Larimal [®]	3
C	8.75+2.86mg/kg of Larimal [®]	6
D	17.50+5.71mg/kg of Larimal [®]	3

Larimal[®] = amodiaquine plus artesunate

Twelve hours after the last administrations the animals were sacrificed by chloroform anaesthesia. There were perfused with formal saline and the skulls opened to remove the cerebellums. Routine Haematoxylin and eosin method¹¹ was used for processing the tissues.

RESULTS

Group A (Control) section shows the cerebellum and its layers: the outer cerebellar cortex and the inner medulla. The cerebellar cortex shows three layers; the outer molecular layer, the intermediate Purkinje layer and the inner granular layer, which limits the cortex from the medulla. Within the molecular layer are sparse cells scattered all over. Within the Purkinje layer are large Purkinje cells with the granular layer having numerous, thickly populated cells. (**Figure 1**)

Group B section treated with 8.75+2.86mg/kg of amodiaquine plus artesunate for three days, shows the Purkinje cells which are reduced in size compared to the control. (**Figure 2**)

Group C section treated with 8.75+2.86mg/kg of amodiaquine plus artesunate for six days, shows shrinkage of the Purkinje cell layer and cells, as well as loss of the Purkinje cells compared to the control. (**Figure 3**)

Group D section treated with 17.50+5.71mg/kg of amodiaquine plus artesunate for three days shows shrinkage of the Purkinje cell layer and cells as well as loss of Purkinje cells compared to the control. (**Figure 4**)

DISCUSSION

There were slight lesions in group B treated with 8.75+2.86mg/kg of amodiaquine plus artesunate for three days, and reduction in the Purkinje cells sizes and population, as well as shrinkage of this layer in groups C and D sections treated with 8.75+2.86mg/kg and 17.50+5.71mg/kg respectively of amodiaquine plus artesunate for six and three days compared to the control.

Amodiaquine (AQ) and artesunate (AS) are the components of Larimal[®], and have some adverse effects on the brain tissues of the body. AQ is a 4-aminoquinolone, which generates free radicals in the form of AQ quinone imine and semi quinone imine. These have been implicated in lipid peroxidation in the membranes of hepatocyte cells⁴. It does not require an overdose for its toxicity, because it is still toxic to mammalian cells in therapeutic dose¹. Artemisinin and its derivatives are toxic to

malaria parasites in vitro at nanomolar concentration, whereas micromolar concentration is required for toxicity to mammalian cells¹¹. AS releases reactive, alkylating, oxygen free radicals from its endoperoxide bond⁴ leading to lipid

peroxidation¹². The effects seen in this study might have been due to the ability of the components of the drug to carry out the above effects in the cerebellum of the treated Wistar rats.

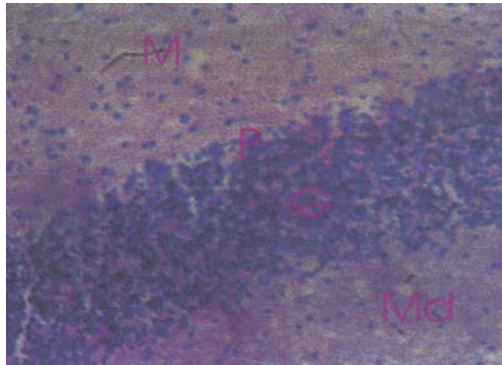


Figure 1: Cerebellar section of the Control (group A) showing normal architecture: M= Molecular layer; P= Purkinje layer; G= Granular layer; Md= Medulla (400X)

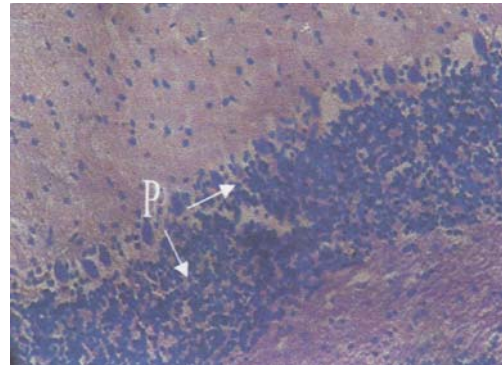


Figure 2: Cerebellar section of group B showing the Purkinje cells (P) reduced in size (400X)

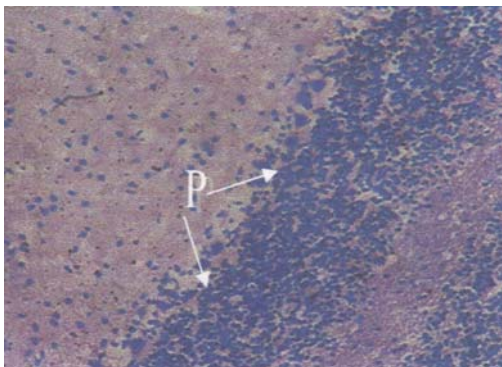


Figure 3: Cerebellar section of group C showing shrinkage of the Purkinje cell layer, as well as loss of the Purkinje cells (P) (400X)

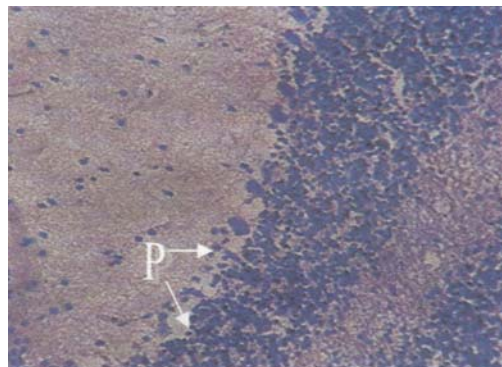


Figure 4: Cerebellar section of group D showing shrinkage of the Purkinje cell layer, as well as loss of Purkinje cells (P) (400X)

There have been reports that chemically induced neurodegeneration is usually characterised by different patterns of neuronal cell death, gliosis, swollen or destroyed axons, or destruction of the myelin sheath. These effects are usually preceded by changes on biochemical targets¹³. This is in line with the study¹⁴ who reported that Wistar rats treated with Cyclophosphamide or Lomustine showed changes in the cerebellum with ultrastructural lesions found mainly in the astroglia cells localized in the perivascular area. The cytoplasm of these cells was on the large area devoid of organelles. Neurons were less affected but in Purkinje cells, mild ultrastructural lesions were found with increased activity of glucose-6-phosphatase and decreased succinate

dehydrogenase activity, suggesting disturbed metabolism in the neurons.

The change in the cell morphology at light microscopic level as seen in this study, shows that the drug affects the Purkinje cells and layer in the groups treated with 8.75+2.86mg/kg and 17.50+5.71mg/kg of amodiaquine plus artesunate for six and three days respectively. This may result in inadequate output signal from the cerebellar cortex to the rest of the brain and other parts of the body, since it is the major cortical output of the cerebellum. The cerebellum functions in the maintenance of balance and coordination of all motor activities¹⁵. With the disruption of output signals, it may result in the

inability of the cerebellum to function effectively.

These results reveal that amodiaquine plus artesunate causes histological alterations in the cerebellum, which may result in cerebellar dysfunction manifesting in some motor problems like dizziness, gait disturbances and convulsion; and these effects were dose and time dependent.

REFERENCES

1. Ipca. Larimal[®] Drug Leaflet. Ipca Laboratories Ltd. 48, Kandivi Ind. Estate, Mumba; 400067. 2004.
2. Olliaro P, Mussano P. Amodiaquine for Treating Malaria. The Cochrane Database of System Reviews; 2: Cd000016. DOI: 10.1002/14651858. CD000016. In the Cochrane Library. 1, 2006. Chichester, UK: John Wiley and Sons, Ltd. 2003:1196-60.
3. Clarke JB, Maggs JL, Kitteringham NR, et al. Immunogenicity of Amodiaquine in the Rat. *Int Arch Allergy Appl Immunol*. 1990;91(4):335-42.
4. Maggs JL, Tingle MD, Kitteringham NR, et al. Drug-protein conjugates--XIV. Mechanisms of formation of protein-aryllating intermediates from amodiaquine, a myelotoxin and hepatotoxin in man.. *Biochem Pharmacol*. 1988 Jan;37(2):303-11.
5. Meshnick SR. Artemisinin: mechanism of action, resistance and toxicity. *Int J Parasitol*. 2002 Dec;32(13):1655-60.
6. Gordi T, Lepist EI. Artemisinin derivatives: toxic for laboratory animals, safe for Humans? *Toxicol Lett*. 2004 Mar;147(2):99-107.
7. Brewer TG, Peggins JO, Grate SJ et al. Neurotoxicity in Animals Due to Arteether and Artemether. Govt Reports Announcements and amp; Index (GRA & I), 24. Walter Reed Army Inst. Of Research, Washington, DC. 1994.
8. Genovese RF, Newman DB, Brewer TG. Behavioral and Neurotoxicity of the artemisinin antimalarial, arteether, but not artesunate and artelinate, in rats. *Pharmacol Biochem Behav*. 2000 Sep;67(1):37-44.
9. Nontprasert A, Pukrittayakames S, Dondrop AM, et al. Neuropathologic toxicity of artemisinin derivatives in a mouse model. *Am J Trop Med Hyg*. 2002 Oct;67(4): 423-9.
10. Miller LG, Panosian CB. Ataxia and slurred speech after artesunate treatment for falciparum malaria. *N Engl J Med*. 1997 May;336(5):1328.
11. Drury RAB, Wallington EA. Carlton's histological techniques. 4th ed. New York, Oxford University Press. 1967:98.
12. Robert A, Benoit-Vical F, Dechy-Cabaret O, et al. From classical antimalarial drugs to new compounds based on the mechanism of action of artemisinin. *Pur Appl Chem*. 2001;73(7):1173-88.
13. Ridley RG, Hudson AT. Chemotherapy of malaria. *Curr Opin Infect Dis*. 1998 Dec;11(6):691-705.
14. Maslinska D. Effect of alkylating drugs on rat cerebellum. *Folia Histochem Cytobiol*. 1986;24(1):47-52.
15. Singh I. Gross Anatomy of Cerebellum. *Textbook of Human Neuroanatomy*. 6thed: Jaypee Brothers Medical Publishers (P) Ltd. Delhi. 2002:62-6.