



## Case Report

### Gastric diverticulum: an uncommon endoscopic finding in a case of halitosis

Vipul D Yagnik<sup>‡</sup>

Consultant endoscopic and laparoscopic surgeon, Ronak Endo-laparoscopy and General Surgical Hospital, Patan, Gujarat, India

(Received 08 January 2018 and accepted 01 February 2018)

**ABSTRACT:** A gastric diverticulum is an outpouching of the stomach or gastric wall. It is an uncommon anatomical abnormality and can present with a variety of symptoms. Here, we present an interesting case of a gastric diverticulum along with halitosis, which was diagnosed on esophagogastroduodenoscopy (EGD) and was managed successfully with conservative treatment, and we review the relevant literature. Surgery is required in case of failed medical management and severe complications.

**KEY WORDS:** *Gastric diverticulum; Halitosis; esophagogastroduodenoscopy; conservative; Surgery*

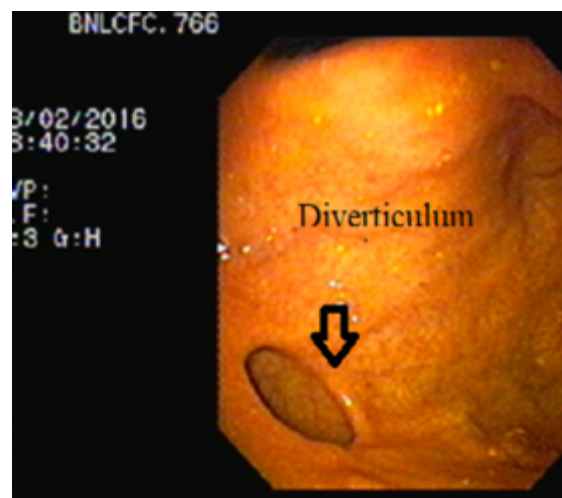
#### INTRODUCTION

Gastric diverticula (GDs) are uncommon, and they are detected incidentally at the time of routine diagnostic testing. They are equally distributed in both sexes, and are commonly found in the 5th and 6th decades of life. There are no typical clinical features to suspect GDs. Patients usually present with flatulent dyspepsia, gastroesophageal reflux disease, and complications, such as bleeding, ulcers, and inflammation<sup>1</sup>. In rare cases, a GD can mimic a left adrenal tumor<sup>2</sup>. This represents a challenge for the consulting physician. Here, we present an interesting case of a GD along with oral fetor or halitosis, which was diagnosed on EGD and was managed successfully with conservative treatment, and we review the relevant literature.

#### CASE DETAILS

A 65-year-old woman with a history of flatulent dyspepsia, presented with abdominal fullness and pain. She also reported halitosis. On abdominal examination, her abdomen was soft and non-tender. She denied a history of hematemesis, melena, or significant weight loss. Additionally, there was no history of *Helicobacter pylori* eradication therapy or upper abdominal surgery. Physical examination

revealed a pulse rate of 84 beats/min and blood pressure of 130/80 mmHg. Oral cavity and otolaryngological examinations were normal. Laboratory investigations revealed a normal leucocyte count, average random serum glucose level (130 mg/dL), normal serum creatinine level (1.2 mg/dL), and mildly elevated erythrocyte sedimentation rate (45mm/h). Her liver function test results were normal. Additionally, abdominal ultrasonography and chest radiography findings were normal. EGD revealed a gastric fundal diverticulum (**Figure1**).



**Figure 1:** A diverticulum in the fundus of the stomach

<sup>‡</sup>Correspondence at: 77, Siddhraj Nagar, Rajmahal Road, Patan-384265, Gujarat, India; Email: [vipulyagnik78@gmail.com](mailto:vipulyagnik78@gmail.com)

No specific content or findings were observed through the 30-mm circular opening of the diverticulum. EGD revealed normal diverticular mucosa, and there were no signs of inflammation, bleeding, ulcer, or malignancy. Other findings were normal, with no evidence of a hiatal hernia, gastritis, or gastroesophageal reflux disease. The result of a rapid urease test was negative. We managed the patient conservatively with a proton pump inhibitor for 6 weeks. The patient remained symptom-free on follow-up after 1.5 years.

## DISCUSSION

A GD is an uncommon anatomic abnormality with a prevalence of 0.1–2.6% at autopsy<sup>3</sup>. It commonly arises from the gastric cardia or fundus near the gastroesophageal junction. Focal weakness caused by splitting of longitudinal muscle fibers, absence of a peritoneal membrane, and a perforating arteriole are responsible for the fundal location of GDs<sup>4</sup>, and 75% of GDs are congenital in origin. Acquired diverticula are associated with a tumor, healing ulcer, or radiation. They have also been reported as a complication of bariatric surgery, as gas production sometimes increases because of carbohydrate malabsorption. Most diverticula are asymptomatic and are found incidentally. The size of the diverticula can range from 1 cm to 10 cm, and GDs are commonly seen in the 5<sup>th</sup> or 6<sup>th</sup> decades of life. They may also be noted in newborns, and are usually associated with pyloric or duodenal obstruction. The patient may experience vague epigastric pain, fullness, dyspepsia, or vomiting. Belching and halitosis have also been reported<sup>5</sup>. Food retention and possible overgrowth of bacteria within the diverticulum have been suggested as possible causes for belching and halitosis<sup>5</sup>. Kinberg *et al.* found that gastrointestinal pathology was common in patients with halitosis and that most patients improved with treatment<sup>6</sup>.

A review by Zeist *et al* showed that of 87 GD patients, thirty-seven (46%) had a hiatal hernia; fifty-seven (72%) had colonic diverticulosis, forty-two (51%) had gastroesophageal reflux, and twenty-nine (37%) had gastritis<sup>7</sup>. Rarely, a GD becomes inflamed and shows bleeding, torsion, or perforation<sup>4</sup>. Malignant degeneration of the mucosa is also possible<sup>4</sup>.

Contrast study of the upper gastrointestinal tract and contrast-enhanced computed tomography can identify a GD. However, both techniques may yield false negative results owing to the limited entry of contrast into the pouch. It has been mentioned that a GD is best identified during contrast study of the upper gastrointestinal tract in the supine, slightly left lateral decubitus, and 15° head low or Trendelenburg positions with a right anterior oblique view<sup>8</sup>. Esophagogastroduodenoscopy can

reliably diagnose a GD. An advantage of endoscopy is that insufflation of the GD by the gastroscope may mimic a clinical presentation and may suggest which patients would benefit from surgery<sup>9</sup>.

Asymptomatic diverticula require no further treatment. On the other hand, symptomatic diverticula may be treated successfully with medication. Surgical management is needed in the case of a large diverticulum or complications involving bleeding, perforation, or malignancy<sup>(4)</sup>. Disabling halitosis may also be an indication for surgery<sup>6</sup>. In the index case, it has been managed by conservative medical management. Both open and laparoscopic surgeries yield good results. However, laparoscopic resection is considered a safe and suitable option when surgery is planned<sup>6</sup>.

## CONCLUSION

The condition represents a great challenge to the consulting physician, and careful examination is required. Early diagnosis can help prevent subsequent complications. Surgery is required in the case of failed medical management and severe complications. Halitosis can also be managed by medical management. Laparoscopic surgery is considered as a safe and suitable procedure.

## REFERENCES

1. Ponsonby A, Gockel I, Thomschke D, Lorenz D. Gastrointestinal: Gastric diverticula. *J Gastroenterol Hepatol.* 2004;19:227.
2. Araki A, Shinohara M, Yamakawa J, et al. Gastric diverticulum preoperatively diagnosed as one of two left adrenal adenomas. *Int J Urol.* 2006;13:64-6.
3. Schiller AH, Rogendorf B, Delker-Wegener S, et al. Laparoscopic resection of gastric diverticula: two case reports. *Zentralbl Chir.* 2007;132:251e5.
4. Carucci LR. Miscellaneous disorder of the stomach (Gastric diverticulum). In, Levy AD, Mortelet KJ, Yeh BJ. *Gastrointestinal imaging*, 1st edition, New York: oxford press. 2015;99-100.
5. Rashid F, Singh R, Cole A, et al. Troublesome belching with fetor odour. *Gut.* 2010;59:310-24.
6. Kinberg S, Stein M, Zion N, et al. The gastrointestinal aspects of halitosis. *Can J Gastroenterol.* 2010;24:552-6
7. Ziesat MC, Zapf M, Ujiki M. Natural history of the gastric diverticulum: a Retrospective Review of 87 Patients. Retrieved from: <https://www.sages.org/meetings/annual-meeting/abstracts-archive/natural-history-of-the-gastric-diverticulum-a-retrospective-review-of-87-patients>

8. Bothen N, Eklof O. Diverticula and duplications (enterogenous cysts) of the stomach and duodenum. *Am J Roentgenol. Radium Ther Nucl Med.* 1966;96:375-81.
9. Anaise D, Brand DL, Smith NL, et al. Pitfalls in the diagnosis and treatment of a symptomatic gastric diverticulum. *Gastrointestinal Endoscopy.* 1984;30:28-30.