



Case Report

Angiomyolipoma of the cervix – report of a rare entity

N. Hariharanadha Sarma^{¶1}, Rama Srivastava², Smriti Agnihotri³

¹Consultant Pathologist, Department of Pathology, RDT Hospital, Bathalapalli, Andhra Pradesh, India

²Professor, Department of Pathology, SSR Medical College, Belle Rive, Mauritius

³Professor, Department of Pathology, American University of Antigua College of Medicine, Antigua & Barbuda, WI

(Received 22 September 2017 and accepted 04 October 2017)

ABSTRACT: Angiomyolipoma (AML) is a mesenchymal neoplasm seen usually in the kidney. Few cases of extra renal AML have been documented in various organs including the female genital tract, where the uterus is the most common site. To the best of our knowledge, only 4 cases of AML in the cervix have been reported in the literature. Association of AML with tuberous sclerosis is well known. Presently AML is included in the spectrum of disease entities called PEComa. We report a case of AML without tuberous sclerosis arising from the uterine cervix, which has to be differentiated from lipoleiomyoma.

KEY WORDS: *Angiomyolipoma; Uterine cervix; PEComas; Uterine tumor*

INTRODUCTION

Angiomyolipoma (AML) occurs most frequently in the kidney, where it is closely related to tuberous sclerosis complex (TSC)^{1,2}, occasionally in other organs, most commonly the liver, but occurrence at other sites is extremely rare³. Irrespective of the type of organ involved, the diagnosis can be established by the presence of a marker of melanogenesis, such as human melanoma black 45 (HMB-45) and positive smooth muscle cells⁴. Angiomyolipoma (AML) has undergone a remarkable transformation in recent years, from a rare and rather pedestrian tumor type restricted to kidney, to a biologically fascinating and morphologically heterogenous entity which can occur in a wide variety of sites and which has been given the collective name of PEComa⁵. Typically, AML is benign, but malignant AMLs of the kidney and liver have been described in exceptional cases^{6,7}. Regarding uterine AMLs, in most cases AMLs originate from the body of the uterus but cases have been reported of cervical

localization⁸, and mostly in females over 40⁹. The occurrence of AML in the cervix without concurrent incidence in the kidney is extremely rare, and only four cases have been reported in the scientific literature¹⁰. We are reporting a case of uterine cervix AML without tuberous sclerosis because of its rarity.

CASE DETAILS

Clinical Summary

A 30-year-old female patient presented with bleeding per vagina for the last two weeks. Clinical examination revealed that she was mentally retarded. She was not cooperative for complete clinical examination. The patient did not have a noteworthy family history of any disease. The patient's attendant gave history of seizures in the patient. Per speculum examination revealed a firm polypoidal mass of about 4 x 5cms size with thick pedicle arising from the uterine cervix. Ultrasonography disclosed normal kidneys, mildly cystic ovaries and a 3 x 4cms sized homogenous well-circumscribed lesion with high vascularity arising from the anterior part of the cervix and extending into the myometrium. Clinical diagnosis of endocervical polyp/cervical fibroid was made. Hysterectomy was performed, and sent for histopathological examination.

[¶]**Correspondence at:** Consultant Pathologist & Head, Department of Pathology, RDT Hospital, Bathalapalli 515661 Andhra Pradesh, India; Phone: +919177155517; Email: nandyalahari@yahoo.com

Pathological Findings

Macroscopically, the hysterectomy specimen contained a polypoidal growth arising from the anterior lip of the cervix. The growth measured 3 x 4 x 6cms, and the cut surface was a uniform greyish brown color. On microscopic examination, the cervical growth consisted of blood vessels and smooth muscle fibers in the cervical stroma covered by stratified squamous epithelium (**Figure 1**). In addition, the focal clusters of adipocytes and the plump spindle cells surrounding small or medium sized thick walled blood vessels were also seen (**Figure 2**). There was no atypia or increased mitotic activity in the tumor.

Immunohistochemical Findings

The tumor showed positive staining for Desmin (**Figure 3**), and negative for HMB-45 and S-100.

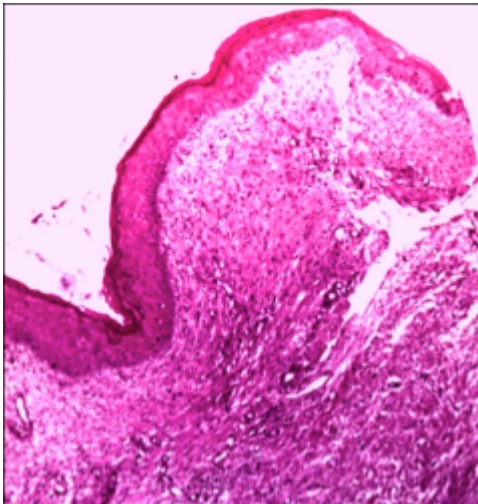


Figure 1: Scanner view of tumor consisting of blood vessels and smooth muscle fibers in the cervical stroma covered by stratified squamous epithelium. H & E X 5

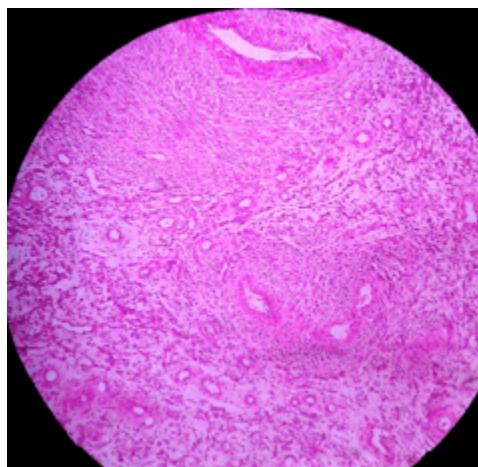


Figure 2: Tumor consisting of thick walled blood vessels surrounded by plump spindle cells. Foci of adipocytes and smooth muscle fibers are also seen. H & E x 20.

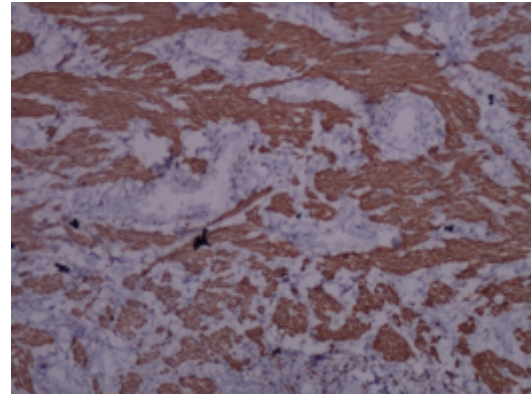


Figure 3: Smooth muscle fibers showing desmin positivity by immunostain X 20

DISCUSSION

Angiomyolipomas (AMLs) are benign mesenchymal neoplasms composed of a variable mixture of adipose tissue and smooth muscle cells with anomalous vascular component. Intrauterine AMLs are extremely rare, and are not officially listed in the WHO Classification of female reproductive system tumors¹¹. According to a summary out of 22 cases of reported uterine angiomyolipomatous lesions¹⁰, only 4 cases arose in the uterine cervix.

The clinical presentations of uterine AMLs are non-specific and variable, and the ultrasound image depends on the biological features of the tumor. Therefore, neither the clinical presentation nor the ultrasound findings are sufficient to make a preoperative diagnosis¹². The diagnosis can be confirmed by FNAC supplemented by immunohistochemistry. It is of interest that non-vascular smooth muscle cells were negative for HMB-45, in contrast to renal and other extra-renal AML in which HMB-45 immunoreactivity has been demonstrated in these cells¹³. In our case, the non-vascular smooth muscle cells were negative for HMB-45 and S-100. Aung *et al*¹⁴ reported that 20% of angiomyolipomas are negative for HMB-45. This is the major point to consider when using HMB-45 antigen alone for the diagnosis of uterine angiomyolipoma. HMB-45 antigen staining is useful for diagnosing uterine smooth muscle tumors, but it is not a definitive indicator of uterine angiomyolipoma.

The association of angiomyolipoma with tuberous sclerosis (TS) patients is well recognized. Some literature has suggested that patients with TS are at increased risk of renal neoplasm. It is well known that AMLs are associated with TS in 5% to 50% of cases¹⁵. However, our case was not associated with TS.

Angiomyolipomas may mimic lipoleiomyoma, degenerated myoma and vascular leiomyoma with a fat component¹⁶. Lipoleiomyomas have a significant percentage of fat between the muscle

cells and the fat cell component may arise from perivascular immature proliferating mesenchymal cells or from direct transformation of smooth muscle cells into adipocytes by means of progressive intracellular storage of lipids¹⁴. In lipoleiomyoma the vascular prominence is not significant whereas in the AML the thick walled blood vessels are the most prominent morphological finding. Degenerated myomas can be differentiated from AML by echogenicity, without shadowing and irregular margins.

CONCLUSION

To conclude, the differential diagnosis of a lower abdominal mass and dysfunctional uterine bleeding should include the AMLs even though the uterine cervix is an extremely rare location for these tumors. We also believe that angioleiomyomas should be recognized as a distinct entity and included in the World Health Organization classification of tumors of the female genital tract.

REFERENCES

1. Eble JN. Angiomyolipoma of kidney. *Semin Diagn Pathol.* 1998;15:21-40.
2. Jimenez RE, Eble JN, Reuter VE, Epstein JI, et al. Concurrent angiomyolipoma and renal cell neoplasia: a study of 36 cases. *Mod Pathol.* 2001;14:157-6
3. Nonomura A, Mizukami Y, Takayanagi N, Masuda S, et al. Immunohistochemical study of hepatic angiomyolipoma. *Pathol Int.* 1996;46:24-32.
4. Tsui WMS, Yuen AKT, Ma KF, TSE CC. Hepatic angiomyolipoma with a deceptive trabecular pattern and HMB-45 reactivity. *Histopathology.* 1992;21:569-73.
5. Ordonez NG, Rosai J. Urinary tract: Kidney, renal pelvis, and ureter; bladder. In Rosai and Ackerman's Surgical Pathology. New York, Elsevier, 2011;1102-6.
6. Guo B, Song H, Yue J, Li G. Malignant renal epithelioid angiomyolipoma: A case report and review of the literature. *Oncol Lett.* 2016;11(1):9-98.
7. Ortiz S, Tortosa F. Epithelioid angiomyolipoma of the liver: Clinicopathological correlation in a series of 4 cases. *Rev Esp Enferm Dig.* 2015;108. doi: 10.17235/reed.2015.3947/2015.
8. Huang PC, Chen JT, Ho WL. Clinicopathologic analysis of renal and extra renal angiomyolipomas: report of 44 cases. *Chinese Med J.* 2000;63(1):37- 44.
9. Ren R, Wu HH. Pathologic quiz case a 40-year-old woman with an unusual uterine tumor. *Arch Pathol Lab Med.* 2004;128:e31-32
10. Yilmaz M, Ingec M, Isaoglu U, Sipal S. Angiomyolipoma of the uterus. *Eur J Gen Med.* 2013;10(3):178-80.
11. Chetty R, Pillay P. Sporadic Angiomyolipoma of the uterus. *J Gynecol Surg.* 2000;16(2):87-91.
12. Tovet TP, Mateva SA, Nikolova MR, Gorchev GA. Uterine angiomyolipoma: a case report, differential diagnosis with PECOMA and review of the literature. *J Biomed Clin Res.* 2014;7(1):47-52.
13. Yaegashi H, Moriya T, Soeda S, Yonemoto Y, Nagura H, Sasano H. Uterine angiomyolipoma: case report and review of the literature. *Pathol Int.* 2001;51(11):896-901.
14. Aung T, Goto M, Nomoto M, Kitajima S, et al. Uterine lipoleiomyoma: a histopathological review of 17 cases. *Pathol Int.* 2004;54:751-8.
15. Cho HY, Kim HB, Lee MJ, Kim KK. Uterine angiomyolipoma with partial cystic changes. *J Women's Med.* 2009;2:88-91.
16. An J, Kim HN, Cho HY, Chung DH, et al. Uterine vascular leiomyoma with a fat component mimicking angiomyolipoma: a case report. *J Women's Med.* 2010;3:130-3.