



Case Report

Type II perforation of the body of the gallbladder in acalculous cholecystitis: a rare complication of enteric fever

Vipul D Yagnik^{w1}

¹Consultant endoscopic and laparoscopic surgeon, Ronak Endo-laparoscopy and General Surgical Hospital, Patan, Gujarat, India

(Received 01 June 2017 and accepted 23 June 2017)

ABSTRACT: Gallbladder perforation is a rare but potentially life-threatening complication of acute cholecystitis with or without gallstones. Enteric fever leading to small bowel perforation is rare, and gallbladder perforation is extremely rare. It requires early and accurate diagnosis. If left untreated, it is associated with high mortality. Clinical diagnosis is often difficult. The most common site of perforation is the fundus; perforation in the body is rare. We report a case of gallbladder perforation as a complication of enteric fever, which presented as acute abdomen and responded very well after cholecystectomy. Although rare and unusual, this case report shows that gallbladder perforation should be considered in patients presenting with acute abdomen and a history of enteric fever.

KEY WORDS: *Enteric fever; Acalculous cholecystitis; Perforation; Cholecystectomy*

INTRODUCTION

Gallbladder perforation is a rare but devastating complication of acute cholecystitis with or without gallstones. Gallbladder perforation secondary to enteric fever is an exceedingly rare event. Niemeier had proposed a classification of gallbladder perforation in 1934¹. Stewart *et al*² have recently replaced the old classification of Niemeier. Most perforations are associated with a localized peritoneal abscess. Free perforation bile peritonitis, intrahepatic abscess, and cholecystoenteric fistula are rare. The fundus is the commonest site of perforation in the gallbladder because of its poor blood supply^{3,4}. Because of its rare occurrence, there are no consensus guidelines for its management. We report a case of gallbladder perforation as a complication of enteric fever, which presented as acute abdomen and responded very well after cholecystectomy.

CASE DETAILS

A 26-year-old male patient presented with a history of severe abdominal pain, distention, fever, and

bilious vomiting over four days. He had not passed stool for the last four days and had a history of occasional fever and abdominal pain over three weeks. He was a smoker, non-alcoholic and denied any history of yellow discoloration of sclera or urine. He had been treated locally with antibiotics and antipyretics. Vitals at the time of admission were: blood pressure - 92/64 mmHg, pulse rate - 134/ per minute, temperature - 37.4°C, and respiratory rate - 26 breaths/minute. On examination, the abdomen was distended, and tender with rigidity all over. X-ray abdomen-erect showed free gas under both the domes of the diaphragm. Ultrasound of the abdomen demonstrated mild hepatosplenomegaly along with moderate to gross free fluid with internal echoes and a collapsed gallbladder without stones suggestive of peritonitis due to perforation. Laboratory examination revealed neutrophilic leukocytosis with band cells>25%. Mildly altered liver and renal functions were noted. Coagulation profile and pancreatic enzymes were within normal limit. Serum Widal test for *S. typhi* was positive at the titre of 1:320. Resuscitation was performed with intravenous fluids and vasopressor agent noradrenaline at the rate of 4µg/hr. Because of hemodynamic instability, we did not order computed tomography (CT) scan. Diagnostic laparoscopy was also not performed for the same reason. After initial resuscitation, the patient was

^wCorrespondence at: 77, Siddhraj Nagar, Rajmahal Road, Patan-384265, Gujarat, India; Email: vipulyagnik78@gmail.com

operated upon, with a subcostal incision because of preoperative suspicion of gallbladder perforation. Laparotomy revealed purulent peritonitis. There was no perforation in the small bowel, but a large perforation was noted in the body of the gallbladder (**Figure 1**). We looked carefully for gallstones in the gallbladder, cystic duct, and peritoneal cavity but none were found. Cholecystectomy was performed, and a drain placed in Morrison's pouch after thorough peritoneal lavage. The rectus sheath was closed with polydioxanone suture and skin was closed with staples. Culture of bile and blood were positive for *Salmonella* and *Klebsiella* respectively. Histopathological examination of the specimen revealed acute inflammatory infiltrate and transmural necrosis of gallbladder. Injection ceftriaxone was administered postoperatively. In the post-operative period, the patient developed basal atelectasis and pneumonia, which was treated with antibiotics and aggressive chest physiotherapy. After surgery, he recovered well and was discharged 12 days later. He was on follow-up for two months without any problem.

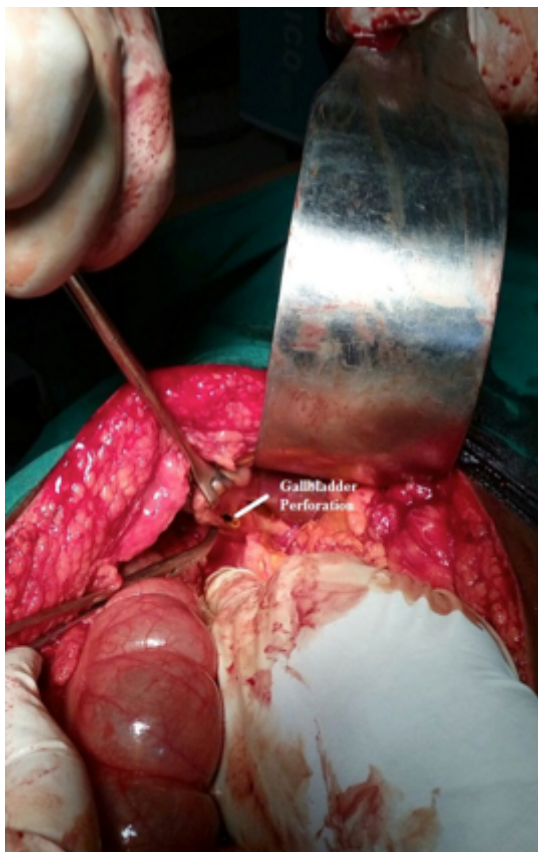


Figure 1: Perforation in the gall bladder

DISCUSSION

Typhoidal *Salmonella*, including *Salmonella enterica* serotype Typhi, Paratyphi A, B and C5 cause enteric fever. All these bacteria are gram-negative bacilli. The global burden of many

intestinal infections has fallen in the last two decades, but the global burden of typhoid has increased significantly⁶. Acute acalculous cholecystitis associated with gallbladder perforation is often seen with severe infections like pneumonia, viral infections, and with enteric fever where the causative organism *Salmonella typhi* was identified in bile and are further concentrated in gallbladder⁷. Through an extensive literature in the PubMed and Google Scholar search, only 23 publications on gallbladder perforation due to typhoid were found since 1895 till date. Typhoid complicated cholecystitis has a reported incidence of 2.8% with 1.7% being acalculous⁸. Gunturi *et al*⁹ stated that every gallbladder perforation may not have necrosis or gangrene, but may have a small perforation.

Gallbladder perforation (GBP) is a rare but devastating complication of acute cholecystitis. Initially, in 1934, Niemeier classified GBP into three categories (1) Type-I (acute): free perforation with generalized peritonitis; (2) Type II (sub-acute): localized peritonitis; (3) Type III (chronic): cholecystoenteric fistula¹. Recently, the classification had been revised by Stewart *et al*² as peritoneal abscess, intrahepatic abscess, free perforation, and cholecystoenteric fistula. It occurs in 2 to 11% of patients with acute cholecystitis¹⁰. In a study series and review of 198 patients, Date *et al*¹¹ demonstrated a mean age of 62.1 ± 9.1 (range 47-71) years and a median male gender proportion of 55.4% (range 33.3-76.7%). The most common GBPs were type II (median 46.2%, range 7.4-83.3%), followed by type I (median 40.6%, range 16.7-70.0%) and type III (median 10.1%, range 0-48.1%)¹¹. Perforation was associated with cholelithiasis in 86.6% (median range 78.9-90.6%) of patients, and the overall median mortality rate was 10.8% (range 0-12.5%)⁹. In a series of 15 cases of GBP, the mortality was 12.5% (1/8) in type I, and 42.8% (3/7) in type II. The high mortality in type II perforation may be due to delay in diagnosis as the condition masquerades as other common surgical conditions and so specific treatment is usually delayed¹². Focal defect or hole sign on the gall bladder is more specific to perforation¹³. CT scan is more accurate for diagnosis of GBP as compared to ultrasonography. It may also reveal a tomographic hole-sign¹⁴. Kim *et al*¹⁵ reported that gallbladder wall defect and bulging of the gallbladder wall suggesting a site of perforation was seen in 38.5% on ultrasound and 69.2% on CT. The signs of gallbladder perforation can be either direct and indirect: the demonstration of either calculus outside the gallbladder or sonographic or tomographic hole-sign is a direct indicator according to Pedrosa *et al*¹⁶. Indirect indicators include the presence of a pericholecystic abscess along with calculus cholecystitis. Free intraperitoneal fluid with collapsed gallbladder

raises the suspicion of gallbladder perforation. Most of the cases of perforation can only be diagnosed during surgical intervention. Localized abscess is the most common while free perforation (<1%) is less common and least common is the cholecystoenteric fistula. It occurs due to an inability of the greater omentum to cover the inflammatory condition. Persistent obstruction of the cystic duct leads to an empyema. The increased intraluminal pressure within the gallbladder due to persisting obstruction leads to vascular compromise, gangrene, necrosis, and perforation. The fundus is the commonest site^{3,4}. Acalculous cholecystitis without obstruction is unlikely to result in perforation¹⁷. Perforation in such cases is because of the result of intense inflammation coupled with acute infection and existence of an immunocompromised state leading to uncontrolled infection and thrombosis of the blood vessels¹⁸. Our patient developed perforation probably due to ischemia and acalculous cholecystitis in the body of the gallbladder. This case is rare and therefore challenging. Such patients require aggressive fluid resuscitation, antibiotics, and emergency cholecystectomy. Preoperative sepsis was the most important risk factor for postoperative morbidity, and mortality¹⁰. In a large series, morbidity and mortality rates were 57.7% and 9.5% respectively¹⁰. Cholecystostomy is an acceptable alternative especially in high-risk patients¹⁹.

CONCLUSION

Early diagnosis of gall bladder perforation and immediate surgical intervention are of crucial importance to reduce the morbidity and mortality associated with GBP. Sepsis is the most important risk factor for mortality and morbidity, and emergency cholecystectomy should be considered. Gallbladder perforation secondary to enteric fever requires a high index of clinical suspicion for diagnosis.

REFERENCES

- Niemeier OW. Acute free perforation of the gallbladder. *Ann Surg.* 1934;99:922-4.
- Stewart L, Jarvis G, Griffiss JM. The treatment and revised classification of gallbladder perforation in acute cholecystitis: the importance of intrahepatic and abdominal abscess formation. *Gastroenterology.* 2014;146(5):1024-5.
- Roslyn JJ, Thompson JE, Darvin H. Risk factors for gallbladder perforation. *Am J Gastroenterol.* 1987;82:636-40.
- Essenhigh DM. Perforation of the gallbladder. *Br J Surg.* 1968;55:175-8.
- Buckle GC, Fischer Walker CL, Black RE. Typhoid fever and paratyphoid fever: systematic review to estimate global morbidity and mortality for 2010. *J Global Health.* 2012;2(1):10401.
- World Health Organization. Typhoid vaccines: WHO position paper. *Wkly Epidemiol Rec.* 2008;83(6):49-59.
- Christie AB. Typhoid and paratyphoid fever. In Christie AB, editor. *Infectious Diseases: Epidemiology and Clinical Practice.* 3rd edition. New York: Churchill Livingstone; 1980:47.
- Bhandari RS, Luitel BR, Lakhey PJ, Singh KP. Gallbladder complications of typhoid. *J Institute Medicine.* 2009;13(2):44-7.
- Gunturi SRV, Thumma VM, Satheesh B, Nambada M, et al. Gallbladder perforation following typhoid fever - a case report (Personal Communication). 2012.
- Ausania F, Guzman Suarez S, Alvarez Garcia H, Senra Del Rio P, et al. Gallbladder perforation: morbidity, mortality and preoperative risk prediction. *Surg Endosc.* 2015;29(4):955-60.
- Date RS, Thrumurthy SG, Whiteside S, Umer MA, et al. Gallbladder perforation: case series and systematic review. *Int J Surg.* 2012;10:63-8.
- Jain BK, Prasad D, Mohanty D, Garg PK, et al. Gallbladder perforation: a great masquerader. *Am Surg.* 2012;78(1):E30-2.
- Sood BP, Kalra N, Gupta S, Sidhu R, et al. Role of sonography in the diagnosis of gallbladder perforation. *J Clin Ultrasound.* 2002;30(5):270-4.
- Morris BS, Balpande PR, Morani AC, Chaudhary RK, et al. The CT appearances of gallbladder perforation. *Br J Radiol.* 2007;80(959):898-901
- Kim PN, Lee KS, Kim IY, Bae WK, et al. Gallbladder perforation: comparison of US findings with CT. *Abdom Imaging.* 1994;19(3):239-42.
- Pedrosa CS, Casanova R, Rodriguez R. CT findings in subacute perforation of the gallbladder: report on 5 cases. *Eur J Radiol.* 1981;1(2):137-42.
- Roslyn JJ, Thompson JE Jr, Darvin H, DenBesten L. Risk factors for gallbladder perforation. *Am J Gastroenterol.* 1987;82(7):636-40.
- Jaramillo Samaniego J.G. Acalculous acute cholecystitis during the course of typhoid fever in children. *Rev Gastroenterol Peru.* 2001;21(1):36-41.
- Singh S, Mohanty D, Singh B, Jain BK. Enteric fever with gallbladder perforation. *Trop Gastroenterol.* 2010;31(1):49-51.