



**Case Report**

**An unusual case of common carotid artery pseudoaneurysm caused by migration of swallowed sewing needle**

**Ganesh Sanap<sup>\*†</sup>, Kiran Naiknaware<sup>\*\*</sup>, Kishor Taori<sup>\*\*</sup> and Anil Bhaya<sup>\*</sup>**

**\*Apple Hospital and Research institute, Shahupuri, Kolhapur, Maharashtra, India**

**\*\*Department of Radiodiagnosis, Government Medical College, Nagpur, Maharashtra, India**

*(Received 10 February 2013 and accepted 21 October 2013)*

**ABSTRACT:** Common carotid artery (CCA) pseudoaneurysms are most commonly a result of traumatic injuries. CCA pseudoaneurysm due to migration of ingested foreign body is an unusual occurrence. Here we report a case of a 50-year-old female who presented with a pulsatile swelling in the right lower neck for 2 months. Ultrasonography (USG) and Computed Tomography Angiography (CTA) of neck revealed a large partially thrombosed pseudoaneurysm involving the right common carotid artery. Sewing needle (metallic foreign body) was noted within the thrombosed portion of the pseudoaneurysm and was successfully removed at surgery followed by repair of the pseudoaneurysm.

**KEY WORDS:** *Pseudoaneurysm; Metallic foreign body; CT angiography; PTFE graft*

**INTRODUCTION**

Pseudoaneurysms occur due to a variety of causes such as inflammation and trauma and may also be iatrogenic<sup>1</sup>. Common carotid artery (CCA) pseudoaneurysms are commonly due to penetrating neck injuries. It is very rare for a swallowed foreign body to migrate through the esophagus and erode the adjacent artery resulting in a pseudoaneurysm. We report here a 50 year old female who accidentally swallowed a sewing needle with food which migrated and resulted in pseudoaneurysm of the right common carotid artery.

**CASE DETAILS**

A 50 year old female presented with sudden onset pulsatile and gradually increasing swelling in the right lower neck for 2 months (**Figure 1**). The swelling was painless, non-tender and gradually increasing in size. On examination there was visible swelling noted on right lower neck which was relatively soft on palpation. There was no redness over the region. There was no palpable

thrill or bruit. The patient revealed a history of accidentally swallowing a sewing needle along with food around 3 months back and of having odynophagia for a few days. The pain abated to mild discomfort for the next 15-20 days, and was relieved by eating plenty of bananas and drinking large quantities of water, as advised by a local physician. Neck radiographs (AP & lateral views) revealed soft tissue swelling on the right side extending from C6 to T2 vertebral level with displacement of tracheal shadow towards the left (**Figure 2**). A vertically oriented linear radio-opaque metallic foreign body was noted overlying the left pedicles of T1 and T2 vertebral bodies. Ultrasonography with Colour Doppler using linear array 12-3Mhz probe revealed partially thrombosed large pseudoaneurysm (exhibiting typical swirling blood flow) involving the right CCA (**Figure 3**). The right CCA was narrowed in caliber just distal to the pseudoaneurysm due to mass effect. The pseudoaneurysm sac was connecting with right CCA. There was no stenosis or atherosclerosis of the distal part of CCA. Doppler Ultrasonography showed typical swirling motion of blood flow referred to as the “yinyang sign” within the pseudoaneurysm. The sac did not contract or expand on cardiac pulsation.

<sup>†</sup>**Correspondence at:** Resident, Apple hospital and research Institute, E ward, Shahupuri, Kolhapur, Maharashtra, India; Cell: +919823962823; Email: [drganeshsanap1009@gmail.com](mailto:drganeshsanap1009@gmail.com)

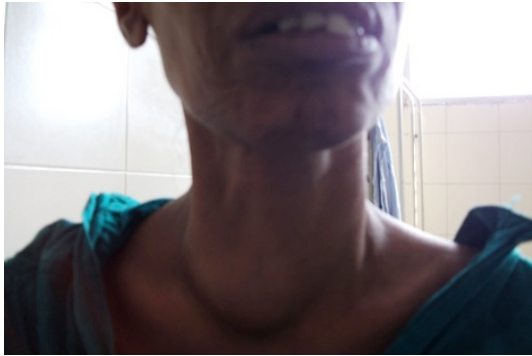


Figure 1: Clinical photograph of patient showing swelling within the right lower part of neck

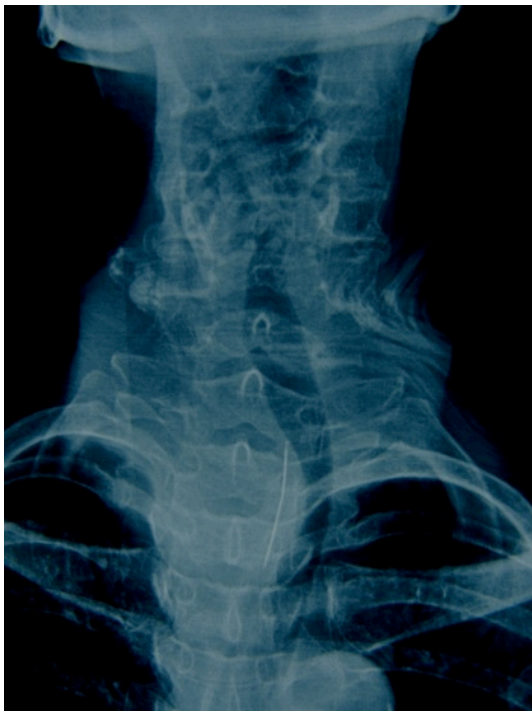

Figure 2: Neck radiograph AP view shows soft tissue swelling on right side at the C6 to T2 vertebral level with displacement of trachea towards the left side. A vertically positioned linear radio-opaque metallic foreign body is noted.

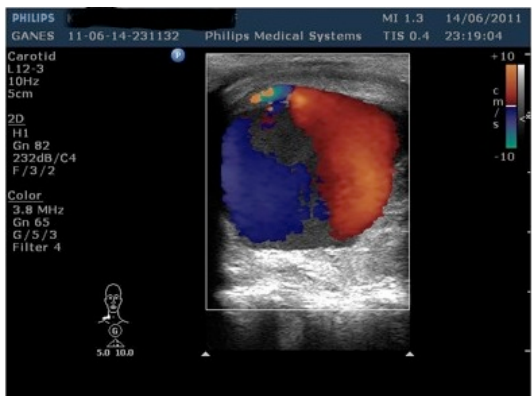


Figure 3a: Color Duplex Sonography with spectral waveform showing partially thrombosed large pseudoaneurysm (note yin-yang pattern of blood flow) involving the right CCA.

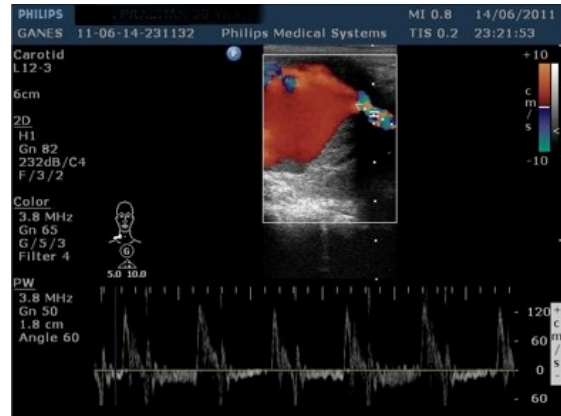


Figure 3b: Color Duplex Sonography with spectral waveform showing partially thrombosed large pseudoaneurysm (showing yin-yang type of blood flow) involving the right CCA

CT angiography confirmed the diagnosis of a pseudoaneurysm measuring approximate 6 x 7 cms (AP x RL) involving the proximal right CCA (**Figure 4**). This pseudoaneurysm was displacing the trachea & thyroid gland towards the left. The right internal jugular vein was displaced laterally. The metallic foreign body (sewing needle) was seen within the thrombosed medial portion of pseudoaneurysm. The sewing needle was oriented vertically closely abutting the esophageal wall. However, no obvious signs of esophageal perforation or inflammation were detected. CT scan of brain was not done in this case as there are no signs of neuronal deficit. Part of CCA just distal to pseudoaneurysm is narrowed due to mass effect. There is no stenosis or atherosclerosis in distal part of CCA seen.

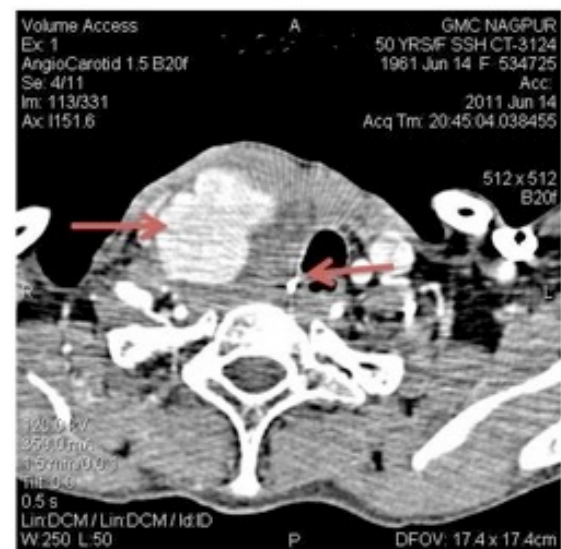


Figure 4a: Axial section through neck, CT Angiography showing large pseudoaneurysm involving the proximal right CCA. The pseudoaneurysm displaces the trachea towards the left. The right internal jugular vein was compressed. Arrows showing foreign body.

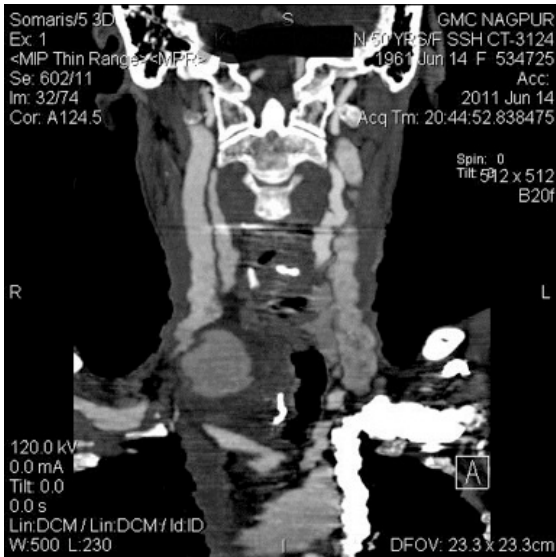


Figure 4b: 3D MIP images of partly thrombosed pseudoaneurysm displacing trachea to left with foreign body located along the medial aspect.

The patient was operated upon and the sewing needle was removed (Figure 5) along with aneurysmectomy followed by PTFE graft repair. No active management of the distal part of CCA was done and it got re-established to its original size after treating the pseudoaneurysm. Post-operatively it was difficult to analyze the true nature of arterial wall due to graft. Surgical correction was preferred to remove the sewing needle as other options like endovascular procedures were not useful to assess associated complications like leak; moreover it was not possible to assess perivascular and peri-esophageal soft tissue by endovascular procedure.

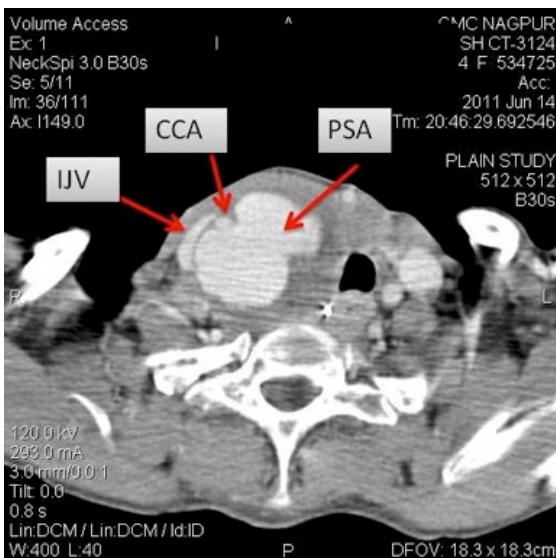


Figure 5: Communication between CCA and pseudoaneurysm.

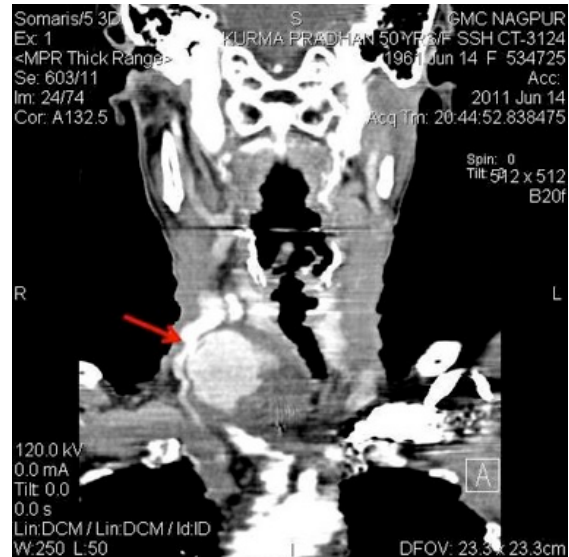


Figure 5b: Communication between CCA and pseudoaneurysm.

## DISCUSSION

Pseudoaneurysms arise due to disruption in continuity of the arterial wall, which may result from inflammation, trauma or iatrogenic causes<sup>1</sup>. Carotid artery pseudoaneurysms are most commonly a result of penetrating trauma. Swallowed sharp foreign bodies can penetrate through the esophageal wall and rarely result in pseudoaneurysm. The literature reports few cases of thoracic aortic pseudoaneurysm due to swallowed foreign body and common carotid artery pseudoaneurysm due to ingested metallic foreign body<sup>2-4</sup>. In our case the culprit was a swallowed sewing needle that had penetrated the esophageal wall and resulted in right common carotid artery pseudoaneurysm.

With the introduction of modern imaging modalities, the diagnosis of pseudoaneurysms has become more common<sup>5</sup>. Although conventional angiography remains the diagnostic standard of reference, other modalities such as Duplex Doppler Ultrasonography (USG), spiral Computed Tomography Angiography (CTA) and Magnetic Resonance Angiography (MRA) are useful tools for the noninvasive detection and diagnosis of pseudoaneurysms<sup>6,7</sup>.

Pseudoaneurysms may be asymptomatic. When symptomatic, pseudoaneurysms may manifest with local or systemic signs and symptoms. Local effects are secondary to mass effect upon adjacent structures and may manifest as a palpable thrill, audible bruit, or a pulsatile mass. In the index case the patient presented with a pulsatile swelling in the right lower neck. Doppler Ultrasonography helped establish the diagnosis. Ultrasonography has been reported to have sensitivity of 94% and specificity of 97% in detection of pseudoaneurysm<sup>8</sup>. Pseudoaneurysms commonly demonstrate blood

flow within a cystic structure characterized by a typical swirling motion referred to as the “yinyang sign”<sup>9</sup>. The diagnostic clincher is the demonstration of a communicating channel (neck) between the sac and the feeding artery with a “to-and-fro” waveform at Doppler US. Ultrasonography (USG) can also be used to follow up patients following treatment. In our patient on Colour Doppler Ultrasonography the pseudoaneurysm exhibited characteristic yin yang sign in the lower neck with feeding vessel being the right common carotid artery. Contrast-enhanced CT, in such cases, may demonstrate a contrast material filled sac with or without a low-attenuation (thrombosed) area associated with the pseudoaneurysm. CT angiography has a sensitivity and specificity of 95.1% and 98.7% respectively in detecting pseudoaneurysm.<sup>6</sup> The donor artery adjacent to the pseudo aneurysm can usually be seen communicating with it. CT Angiography has advantages over other imaging modalities being noninvasive, with fewer operator dependent errors and a shorter acquisition time. Post processing of the raw data yields three-dimensional images, Maximum Intensity Projection (MIP) & Volume Rendering Technique (VRT) images. Furthermore, CT can help detect associated injuries or other pathologies that may not be detected with catheter angiography, a technique limited to evaluation of vascular structures<sup>10</sup>.

Three-dimensional gadolinium-enhanced MR angiography allows visualization of a lesion in any projection. Furthermore, unlike CT angiography, no iodinated contrast material or ionizing radiation is utilized<sup>11</sup>, making 3D contrast-enhanced MR angiography a valuable tool in the imaging of pseudoaneurysms in patients with impaired renal function and allergies to CT contrast material<sup>12</sup>. Usefulness of MR angiography may also be limited due to artifacts caused by patient motion, metallic artifacts due to surgical clips or foreign body, turbulent flow or vessel tortuosity or pulsatility<sup>13</sup>. Conventional catheter based angiography remains the standard of reference for the diagnosis of pseudoaneurysms despite the advent of new imaging technologies such as CT angiography and MR angiography. A significant advantage of angiography is its capacity for real-time hemodynamic assessment of a particular vascular bed, which includes identifying collateral vessels to assess the expendability of the donor artery. Such assessment is important in treatment planning. The donor artery can be accurately identified and selective angiography performed to identify the characteristics of the pseudoaneurysm, including the size of its neck<sup>5</sup>. In addition, angiography provides a diagnostic tool with concomitant therapeutic potential, if indicated<sup>6,11</sup>. However the main disadvantage is it being unable to demonstrate

the exact size of the thrombosed part of the aneurysm.

In our case CT Angiography demonstrated a partly thrombosed large right CCA pseudoaneurysm. The right proximal CCA was narrowed in caliber. A metallic sewing needle was identified within the medial wall of the pseudoaneurysm abutting the esophageal wall. MR Angiography was not performed in our case as metallic foreign body usually result in signal void and also there were chances of migration of the needle due to magnetic field effects<sup>14,15</sup>.

There are various methods of treating a pseudo aneurysm. US guided compression is useful for superficially located extremity pseudoaneurysms<sup>8,16</sup>. Percutaneous thrombin can be injected in selected cases as well. Despite the growing popularity of image guided compression and endoluminal catheter related management of pseudoaneurysms, surgical management still plays an important role especially in pseudoaneurysms with local mass effect, complications such as ischemia and neuropathy, infected pseudoaneurysms, and in patients in whom minimally invasive therapeutic techniques have failed<sup>8</sup>. In general, surgical techniques vary widely and include resection and repair with bypass grafts (autologous vein or synthetic graft prostheses) and arterial ligation<sup>17</sup>. In the index case, surgical management was preferred as it was difficult to remove the needle by endovascular methods and because examination of perivascular and periesophageal soft tissue was deemed necessary. Consequently, aneurysmectomy and arterial repair with placement of Polytetrafluoroethylene (PTFE) graft was performed. So it is very important to decide the management technique based on etiology.

The patient recovered uneventfully and no delayed complications were reported till the time of writing this case report.

## CONCLUSION

Migration of accidentally swallowed metallic sewing needle through esophagus resulting in CCA pseudoaneurysm is an extremely rare occurrence. Color Duplex Ultrasonography and CT Angiography were valuable in the preoperative diagnosis and assessment of the pseudoaneurysm. Despite advances in the endoluminal management of pseudoaneurysms such a scenario generally requires comprehensive surgical management (aneurysmectomy with PTFE Graft placement and removal of the foreign body).

## REFERENCES

1. Schwartz LB, Clark ET, Gewertz BL. Anastomotic and other pseudoaneurysms. In:

- Rutherford RB, ed. Vascular surgery. 5th ed. Philadelphia, Pa:Saunders, 2000:752-63.
2. Schumacher KJ, Weaver DL, Knight MR, Presberg HJ. Aortic pseudo aneurysm due to ingested foreign body. *South Med J*. 1986;79(2):246-8.
3. Ferro C, Rossi UG, Bovio G, Dahmane M, et al. Images in cardiovascular medicine. Aortic pseudoaneurysm caused by migration of a swallowed sewing needle: interventional radiology and endoscopic management. *Circulation*. 2008;118(2):e11-5.
4. Mathur NN, Joshi RR, Nepal A, Rauniyar RK. Common carotid artery pseudoaneurysm formation following foreign body ingestion. *J Laryngol Otol*. 2010;124(6):684-6.
5. Arata MA, Cope C. Principles used in the management of visceral aneurysms. *Tech Vasc Intervent Radiol*. 2000;3:124-9.
6. Soto JA, Múnera F, Morales C, Lopera JE, et al. Focal arterial injuries of the proximal extremities: helical CT arteriography as the initial method of diagnosis. *Radiology*. 2001;218(1):188-94.
7. Ahmed A, Samuels SL, Keefe EB, Cheung RC. Delayed fatal hemorrhage from pseudo aneurysm of the hepatic artery after percutaneous liver biopsy. *Am J Gastroenterol*. 2001;96(1):233-7.
8. Morgan R, Belli AM. Current treatment methods for postcatheterization pseudoaneurysms. *J Vasc Interv Radiol*. 2003;14(6):697-710.
9. Saad NE, Saad WE, Davies MG, Waldman DL, et al. Pseudoaneurysms and the role of minimally invasive techniques in their management. *Radiographics*. 2005;25 Suppl 1:S173-89.
10. Munera F, Soto JA, Palacio D, Velez SM, et al. Diagnosis of arterial injuries caused by penetrating trauma to the neck: comparison of helical CT angiography and conventional angiography. *Radiology*. 2000;216(2):356-62.
11. Glockner JF. Three-dimensional gadolinium-enhanced MR angiography: applications for abdominal imaging. *Radiographics*. 2001;21(2):357-70.
12. Natri MV, Baptista LP, Baroni RH, Blasbalg R, et al. Gadolinium-enhanced three-dimensional MR angiography of Takayasu arteritis. *Radiographics*. 2004; 24(3):773-86.
13. Baum R, Carpenter JP. Peripheral Vascular magnetic resonance angiography. In: Baum R, ed. *Abram's angiography* 4th ed. Boston Mass 21. Little Brown 1997: 752-63
14. Kiliç A, Avcu S, Tekin S, Gül A, Cinal A, et al. MRI-Induced Migration of Retained Metallic Foreign Body in the Eye. *Ophthalmic Surg Lasers Imaging*. 2010;1-3. doi: 10.3928/15428877-20100215-62.
15. Tang IP, Singh S, Shoba N, Rahmat O, et al. Migrating foreign body into the common carotid artery and internal jugular vein--a rare case. *Auris Nasus Larynx*. 2009;36(3):380-2.
16. La Perna L, Olin JW, Goines D, Childs MB, et al. Ultrasound-guided thrombin injection for the treatment of post catheterization pseudoaneurysms. *Circulation*. 2000;102(19):2391-5.
17. Bergert H, Hinterseher I, Kersting S, Leonhardt J, et al. Management and outcome of hemorrhage due to arterial pseudoaneurysms in pancreatitis. *Surgery*. 2005;137(3):323-8.