

Original Article

An evaluation of the carrying angle of the elbow joint in adolescents

Rajesh B*, Reshma VR, Jaene RC, Somasekhar IT, Vaithilingam A

Department of Anatomy and Orthopedics, Sri Lakshmi Narayana Institute of Medical Sciences,
Pondicherry - 605 502, India

*Corresponding author: anat_rajesh@rediffmail.com

Received: 13.03.13; Accepted: 03.11.13

ABSTRACT

Background: The acute angle produced medially when the axis of the forearm deviates laterally from the long axis of the humerus, with the arm extended and the palm facing forward, is referred to as the carrying angle. Variations in the angle have clinical as well as pathological significance. **Aim:** This study was conducted to evaluate the elbow carrying angle in normal adolescents of South India and also analyze the data statistically to find out any significant difference in the angle between the different groups of subjects within the study population. **Methods:** 60 adolescents with ages varying from 17 to 20 years were evaluated. Carrying angles formed by the long axis of the humerus and ulna, were measured. **Results:** The result of the study showed that the average carrying angle was 13.6 degrees for females and 6.7 degrees for males. The length of the forearm and the carrying angle showed significant relation. **Conclusion:** The result of the study could be useful in the management of elbow displacement, fractures, epicondylar disease and surgical planning for elbow reconstruction.

Key words: Carrying angle, elbow joint, adolescent, forearm, humerus, ulna

INTRODUCTION

When the upper extremity is in the anatomic position, the long axis of the humerus and the long axis of the ulna form an acute angle medially at the elbow which is called the carrying angle.^[1] This angle is marginally greater in female than in male. The average angle in men is about 5° whereas in women it is about 10° to 15° (170° in males and 163° -167° laterally).^[1,2] This angle is important in walking, swinging, and carrying objects.

The angulation is as a result of the configuration of the articulating surfaces of the humerus and ulna which produce a normal valgus angulation of the forearm in relation to the humerus.^[1] The angle is usually greater in females than in males and the difference has been considered to be a secondary sexual characteristic.^[3-7] However, some workers reported no significant difference in carrying angle of males and females of any age group.^[8-10] The carrying angle permits the arm to swing without contacting the hips.^[11,12]

Women on average have smaller shoulders and wider hips than men, which may necessitate a more acute carrying angle.^[11] There is, however, extensive overlap in the carrying angle of men and women, and a sex-bias has not been consistently observed in scientific studies.^[11-13]

The angle is greater in the dominant limb than in the non-dominant limb of both sexes, suggesting that natural forces acting on the elbow modify the carrying angle.^[14,15] Developmental, ageing and possibly racial influences add further to the variability of this parameter.^[14-16]

An increase in the carrying angle is abnormal, particularly if it occurs unilaterally. If the angle is increased beyond the average, it is called cubitus valgus.^[15,17] The knowledge of carrying angle is highly significant in the management of various types of fractures of the elbow.^[17]

As there is a difference in opinion about the carrying angle of males and females (vide supra), the present study is designed to estimate the difference in the carrying angle of adolescent males and females of south India. The study also aims to evaluate the relation of the carrying angle with various other parameters.

METHODOLOGY

For the present study total 60 healthy students (30 female and 30 male) of Sri Lakshmi Narayana Institute of Medical Sciences were selected. They belong to various states of South India and their ages ranged from 17 to 20 years. The carrying angles were measured using a goniometer following the methods described earlier with slight changes.^[17,18] The age, height, length of forearm and hip circumference were also recorded.

Method to Measure the Carrying Angle

The subjects were asked to stand in anatomical position (stand up straight, roll his/her shoulders back and the elbow was fully extended and the forearm fully supinated). The arms of the goniometer were kept into a straight line and the

goniometer's measurement plate placed at the fulcrum of one elbow. One arm of the goniometer was aligned along the middle of the person's upper arm. The goniometer's other arm was swung/moved along until it lined up along the middle of the person's forearm. The angle was recorded from the readout on the measurement plate. The process was repeated for the other elbow.

A stature meter was used to measure the height. Height was measured from vertex to heel of the individual with bare foot in anatomical position. A measuring tape was used to measure the length of forearm and width of the Hip. The distance between the edial epicondyle and styloid process of the ulna were recorded as length of forearm. All measurements were repeated once with the same instrument to reduce errors.

Statistical analysis

The data collected were statistically analyzed using student t- test.

RESULTS

The carrying angle values of boys and girls were showed a great variability at all ages. The mean carrying angle in boys and girls was 6.7 and 13.56 degrees respectively. The other measurements are given below in table 1.

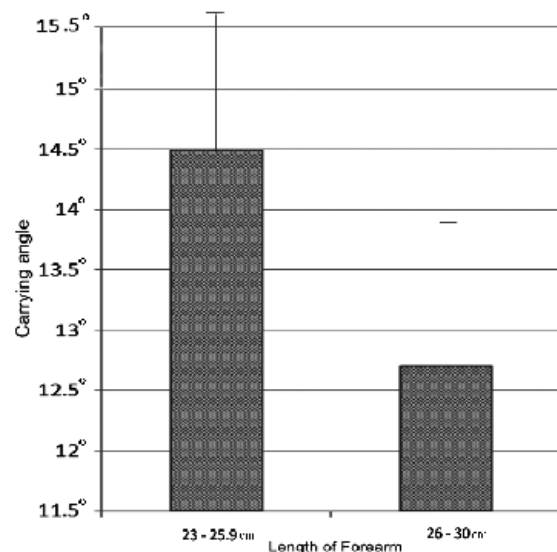


Figure 1: Graph illustrating the higher carrying angle in individuals with shorter forearm

Table 1: Mean measurements of height, length of the forearm, hip and carrying angle in boys and girls

	Measurements			
	Height [in cm] Mean± (SD)	Length of Forearm [in cm] Mean± (SD)	Hip [in inches] Mean± (SD)	Carrying Angle [in degrees] Mean± (SD)
GIRLS	157.7±5.4	25.1±1.6	35.2±4.0	13.3±2.4
BOYS	169.8±5.0	44.4±2.8	33.1±5.5	6.7±1.0

There was a significant association in the carrying angle and length of forearm among the girls. The length of forearm and the carrying angle were inversely proportional.

The other parameters like height of the individual, and width of the pelvis/waist were of not significant (table 2 and 3).

Table 2: Correlation of carrying angle with height, length of the forearm and hip in girls

	Measurements					
	Hip (inch)		Length of forearm (cm)		Height (cm)	
	≤34	≥35	≤25	≥26	≤157	≥158
Carrying Angle of Girls [in degrees]	13.6±2.5	15±3	14.5±2.4	12.7±2*	14.2±2.5	13.3±2.2

*P value 0.03

Table 3: Correlation of carrying angle with height, length of the forearm and hip in boys

	Measurements					
	Hip (inch)		Length of forearm (cm)		Height (cm)	
	≤33	≥34	≤44	≥45	≤169	≥170
Carrying Angle of Boys [in degrees]	6.65±0.9	6.66±1.3	6.76±0.9	6.5±1	6.46±1.1	6.85±0.8

DISCUSSION

The present study is conducted to measure the carrying angle in both girls and boys of similar age group and its relation with other parameters like height and length of forearm. It has been documented that the carrying angle is greater in females than in males and this difference is considered as a secondary sexual characteristic.^[3,4] The result of the present study is also showing a similar pattern.

In a previous study the elbow carrying angle appears not directly related to the height, weight or length of the ulna or humerus.^[19] However, the present study revealed that the elbow carrying angle is higher in girls who have a short forearm/ulna, which is similar to the findings of Khare *et al.*^[20] The variables like height of the individual, length of the arm and width of the hip are not influencing the carrying angle.

Difference between the carrying angles of the right and left sides may suggest ligamentous laxity at the medial elbow or asymmetrical bone growth. Thirty percent of professional baseball pitchers have a valgus elbow deformity- an increased carrying in the dominant elbow (10-15 degrees), which can be taken as a bony remodeling to adapt to stress.^[21] Since the subjects are normal individuals in this series, such discrepancies are not noticed.

Even though changes in the carrying angle have only cosmetic value, an evaluation of the same can help the medical practitioner in the management of certain elbow disorders. In the present study 60 healthy adolescent boys and girls of ages 17 to 20 were evaluated and the average carrying angle was 13.6 for girls and 6.7 degrees for boys. This is supporting the fact that the carrying angle is a secondary sexual characteristic. Among the girls who have a short forearm the carrying angle was very high, which is an important finding in this study. The result of the study could be useful in the management of elbow displacement, fractures, epicondylar disease and surgical planning for elbow reconstruction.

REFERENCES

1. Williams PL, Bannister LH, Berry MM, Collins P, Dyson M, Dussek JE, Ferguson MW, Greys Anatomy, 38th Ed, Churchill Livingstone, London, 1995. pp. 642 -643.
2. Snell RS. Clinical Anatomy for Medical Students. 6th Ed, LWW, New York; 2000: pp 464.
3. Potter HP. The obliquity of the arm of the females in extension. *J Anat Physiol* 1895;29:488-492.
4. Atkinson WD, Elftman H. The carrying angle of the human arm as a, secondary sex character. *Anat Record* 1945;91:49-53.
5. Aebi H, Ellbogenwinkel DER, Geschlecht SB, Hüftbreite KU. *Acta Anat* 1947;3:228-264.
6. Keats TE, Teeslink R, Diamong AE, Williams JH. Normal axial relationship of the major joints. *Radiol* 1966;87:904-908.
7. Baugman FA, Higgins JV, Wads-worth TG, Demaray MJ. The carrying angle in sex chromosome anomalies. *JAMA* 1974;230:718-720.
8. Steel FLD, Tomalinson JDW. The carrying angle in man. *J Anat* 1958;92:315-317.
9. Smith L. Deformity following supracondylar fractures of the humerus. *J Bone Joint Surg* 1960;42:235-238.
10. Beals RK. Normal carrying angle of the elbow. *Clin Orthop* 1976;110:194-196.
11. Steel F, Tomlinson J. The carrying angle in man. *J Anat* 1958;92:315-7.
12. Van Roy P, Baeyens JP, Fauvart D, Lanssiers R, Clarijs JP. Arthro-kinematics of the elbow: study of the carrying angle. *Ergonomics* 2005;48:1645-56.
13. Zampagni M, Casino D, Zaffagnini S, Visani AA, Marcacci M. Estimating the elbow carrying angle with an electrogoniometer: acquisition of data and reliability of measurements. *Orthopedics* 2008 Apr;31:370.
14. Paraskevas G, Papadopoulos A, Papaziogas B, Spanidou S, Argiriadou H, Gigis J. Study of the carrying angle of the human elbow joint in full extension: a morphometric analysis. *Surg Radiol Anat* 2004;26:19-23.
15. Yilmaz E, Karakurt L, Belhan O, Bulut M, Serin E, Avci M. Variation of carrying angle with age, sex, and special reference to side. *Orthopedics* 2005;28:1360-3.
16. Tukenmez M, Demirel H, Perçin S, Tezeren G. Measurement of the carrying angle of the elbow in 2,000 children at ages six and fourteen years. *Acta Orthopaedica et Traumatologica Turcica* 2004;38:274-6.
17. Zampagni ML, Casino D, Martelli S, Visani A, Marcacci M. A protocol for clinical evaluation of the carrying angle of the elbow by anatomic landmarks. *J Shoulder Elbow Surg* 2008;17:106-12.

18. Rai J, Prakash S, Singhal V. Carrying angle in Indian boys and girls. *Ind J Orthop* 1980;14:170-74.
19. Balasubramanian P, Madhuri V, Muliylil J. Carrying angle in children: a normative study. *J Pediatr Orthop B* 2006;15:37-40.
20. Khare GN, Goel SC, Saraf SK, Singh G, Mohanty C. New observations on carrying angle. *Indian J Med Sci* 1999;53:61-7.
21. Tullos HS, Schwab G, Bennett JB, Woods GW. Factors influencing elbow instability. *Instr Course Lect* 1981;30:185-99.

doi: <http://dx.doi.org/10.14194/ijmbr.2310>

How to cite this article: Rajesh B, Reshma VR, Jaene RC, Somasekhar IT, Vaithilingam A. An evaluation of the carrying angle of the elbow joint in adolescents. *Int J Med Biomed Res* 2013;2(3):221-225

Conflict of Interest: None declared



This is an Open Access article distributed under the terms of the Creative Commons Attribution 3.0 License (<http://creativecommons.org/licenses/by-nc-sa/3.0/>) which permits unrestricted, non-commercial, share-alike use, distribution, and reproduction in any medium, provided the original work is properly cited.