

Case Report

## Post-traumatic bronchial mucus plug leading to pneumonectomy

Khan M.S\*, Sarkar U.N

Department of Cardiothoracic and Vascular Surgery, Seth Sukhlal Karnani Memorial Hospital, Institute of Postgraduate Medical Education and Research, 242 AJC Bose Road Kolkata 70020, India.

\*Corresponding Author: mohdshahbaazkhan@yahoo.com

Received: 18.06.12; Accepted: 22.10.12

### ABSTRACT

**Background:** Blunt trauma of the chest is not uncommon these days. The most important cause of blunt chest trauma is motor vehicle accidents. Pedestrians struck by vehicles, falls from height, blast injuries and acts of violence are other causative mechanisms. Most of the blunt trauma cases need no operative intervention and can be managed by supportive procedures. **Aim:** We present a case of a 10-year old boy who had blunt trauma to chest due to fall from height. **Findings:** The patient was in respiratory distress and developed surgical emphysema and pneumothorax on the left side. He was managed by putting in a chest drain on the left side. Patient improved and was discharged. He again developed respiratory distress 15 days later. On bronchoscopic examination, an obstruction was found just distal to the carina in the left bronchus. Several futile attempts were made to retrieve the obstructing material. Hence, mucus plug was removed through left bronchotomy. There was no improvement in the ventilation of the left lung for 7 days. Bronchoscopic suction was done. All the measures failed and the lung remained collapsed. Patient underwent pneumonectomy as the last treatment option available in our hospital. At the time of reporting this case, patient was doing well. **Conclusion:** Chest physiotherapy helps in reducing lung collapse. If patient is reluctant to chest physiotherapy and coughing, it can lead to accumulation of respiratory secretions and formation of mucus plug. This mucus plug can cause collapse of the lung and ill consequences.

**Key words:** Trauma, atelectasis, pneumonectomy, bronchotomy, mucus plug

### INTRODUCTION

Studies describing chest trauma and its treatment date to antiquity.<sup>[1]</sup> An ancient Egyptian treatise, the Edwin Smith Surgical  
Int J Med Biomed Res 2012;1(3):250-253

Papyrus [circa 3000-1600 BC] contains a series of trauma case reports, including thoracic injuries.<sup>[1]</sup> Blunt injury to the chest can affect any one or all components of the chest wall and thoracic cavity; these include the bony skeleton

(ribs, clavicles, scapulae, and sternum), lungs and pleurae, tracheobronchial tree, esophagus, heart, great vessels of the chest, and the diaphragm.<sup>[2]</sup> The most important cause of blunt chest trauma is motor vehicle accidents accounting for 70 to 80% of blunt thoracic injuries.<sup>[2]</sup> Blunt trauma commonly results in chest wall injuries such as rib fractures.<sup>[3]</sup> The pain, direct lung injury, shunting and dead space ventilation associated with these injuries can make breathing difficult and this may compromise ventilation.<sup>[3]</sup>

## CASE REPORT

A 10-year old boy was admitted to the Emergency department with chief complaints of pain and respiratory difficulty due to fall from height. On examination, his pulse rate was 110beats/minute, respiratory rate was 24 cycles/minute, and blood pressure was 90/50 mmHg. There was a decreased breath sound on the left side of the chest. Patient was having surgical emphysema. X-ray chest showed left-sided pneumothorax but no rib fracture. A chest drain was put on the left side and large amount of air came out. Patient was managed with oxygen, nebulization, intravenous fluids and antibiotics. Patient's general condition improved. He was discharged after 7 days. Patient again developed respiratory distress 15 days later and was re-admitted in the Emergency department. On examination, chest movements were decreased on the left side and there were no breath sounds. Chest x- ray, postero-anterior view, was showing fluid collection on the left side. So a chest drain was put again. Patient was then managed with intravenous antibiotics, nebulization and chest physiotherapy regularly. There was no improvement in the ventilation of the left lung even after 4 days. Bronchoscopy was done and an obstruction was found in left bronchus, just distal to the carina. Several attempts were made to retrieve the obstructing material with the bronchoscope but were unsuccessful. Left thoracotomy was done immediately. Left lung was found collapsed. Left bronchotomy was done (figure 1) and a Foley's catheter passed proximally through the incision (figure 2). A large mucus plug was removed (figure 3) with the Foley's catheter. Bronchotomy incision was closed with vincryl suture in interrupted fashion and patient was shifted to the Intensive Care Unit. After weaning from the ventilator, patient received humidified oxygen, nebulization and chest physiotherapy regularly,

but there was no improvement in breath sounds on the affected side. Chest x-ray was done and it showed collapse of the left lung. A decision was taken to for bronchoscopy. Bronchoscopic suction was done several times, but all the measures failed and the lung remained collapsed. The patient developed severe fever and was not responding to the medical management. He slowly developed the features of septicaemia and hemodynamic compromise. As the last available treatment in our hospital, patient underwent left pneumonectomy. Now patient is in follow-up and doing well.

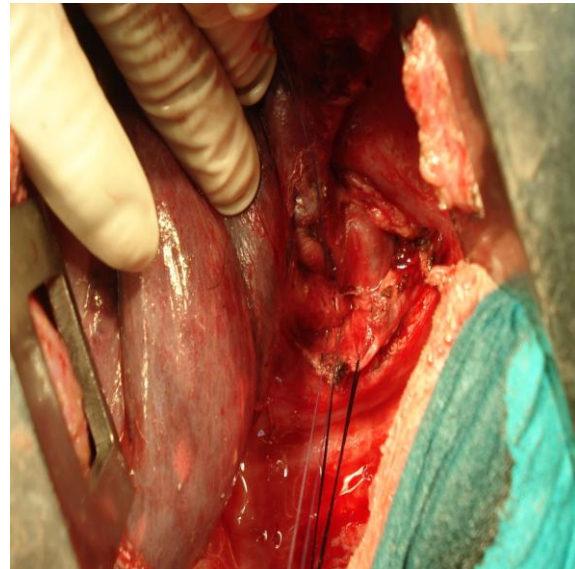


Figure 1: Left Bronchotomy

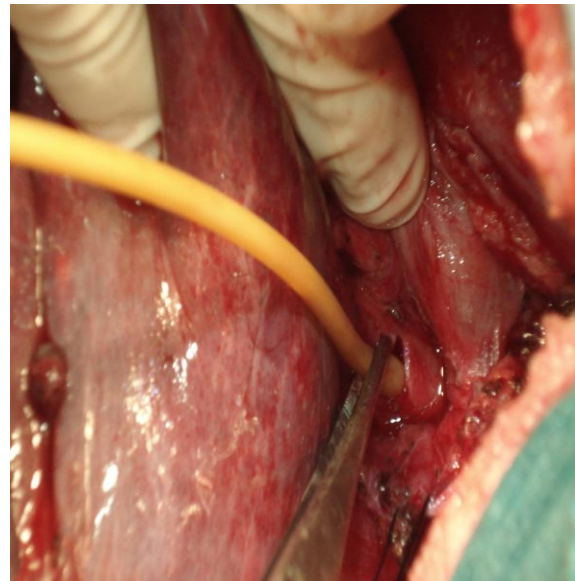


Figure 2: Introduction of Foley's catheter for mucus plug removal

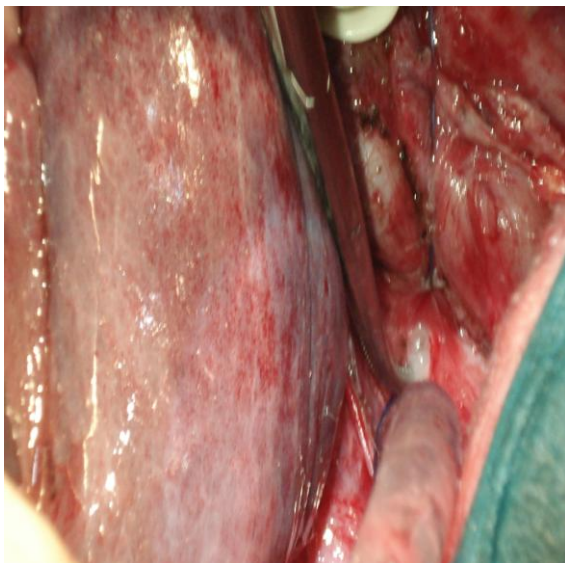


Figure 3: Mucus plug seen through the bronchotomy incision

## DISCUSSION

Blunt trauma of the chest is not uncommon these days and it can cause injury to all the structure of the chest wall and chest cavity. Most of the cases can be managed with supportive treatment only. Indications for immediate surgery include a massive air leak following chest tube insertion, a massive hemothorax or continued high rate of blood loss via the chest tube (i.e. 1500 ml of blood upon chest tube insertion or continued loss of 250 ml/h for 3 consecutive hours), radiographically or endoscopically confirmed tracheal, major bronchial, or esophageal injury, and the recovery of gastrointestinal tract contents via the chest tube.<sup>[3]</sup> Relatively immediate and long-term indications for surgery include a chronic clotted hemothorax or fibrothorax, especially when associated with a trapped or nonexpanding lung, empyema, traumatic lung abscess, delayed recognition of tracheobronchial or esophageal injury, tracheoesophageal fistula, and a persistent thoracic duct fistula/chylothorax.<sup>[3]</sup> Trauma or surgery can cause collapse of the lung. Lung collapse can be classified as either absorptive or compressive atelectasis. Absorptive atelectasis is also called gas atelectasis.<sup>[4]</sup> The production of pulmonary atelectasis due to obstruction with retained secretions was recognized first time by Gairdner<sup>[5]</sup> of Glasgow. Two mechanisms have been established in the pathogenesis of absorptive atelectasis. After complete airway

occlusion, a pocket of trapped gas is created in the lung unit distal to the obstruction; because gas uptake by the blood continues and gas inflow is prevented by blocked airways, the gas pocket collapses.<sup>[6]</sup> Under these conditions, the rate of absorption of gas from an unventilated lung area increases with elevation of the fraction of inspired oxygen (FIO<sub>2</sub>).<sup>[7]</sup> In adulthood, progressive age is not associated with increased propensity for development of atelectasis.<sup>[8]</sup> However, in young children (aged 1-3 years), atelectasis seems to develop more readily than in adults,<sup>[9]</sup> possibly because of the far greater thoracic wall compliance resulting in less outwardly directed lung distension forces.<sup>[10]</sup> In infants, contraction of the diaphragm may cause paradoxical inward movement of the highly deformable chest wall, resulting in loss of lung traction.<sup>[10]</sup> The resultant atelectasis could reduce ventilator efficiency, increase diaphragmatic fatigue, and thereby further increase the tendency for atelectasis development.<sup>[8-10]</sup> Bradford<sup>[11]</sup> suggested the reflex paralysis of the respiratory muscles as the cause in blunt injury to the chest. According to the Jacobaeus<sup>[12]</sup> absorption of the trapped gas distal to the obstruction is not the only mechanism of atelectasis because post traumatic accumulation of the secretions in airway causes rapid collapse of lung within 10 minutes. He proposed that secretions act as ball-valve allowing air to go out in expiration but not to go in during inspiration and so there can be rapid collapse of the lung. The ball valve like action of the mucus plug can readily be accepted because bronchi are not of the same caliber throughout the length. The distal portion is narrower than the proximal portion and that is why it blocks the air to enter during inspiration and let the air go out during expiration. Jackson<sup>[13]</sup> emphasized the importance of the bronchial obstruction in causing atelectasis and according to him cough reflex is the watch dog of the lungs and when that reflex fails the the lumen becomes completely obstructed. Krieder and Lipson<sup>[14]</sup> in a recent review concluded bronchoscopy to be the treatment of choice in lobar and segmental atelectasis but less effective for subsegmental or distal atelectasis. Here in this case, a decision was taken to do bronchoscopy. Bronchoscopic suction was done several times and tried to retrieve the mucus plug and inflate the lung but all the measures failed and the lung remained collapsed. The patient developed severe fever and was not responding to the medical management. He

slowly developed the features of septicaemia and hemodynamic compromise. Patient's condition was not improving, so as a last measure available in our hospital, patient underwent left pneumonectomy. Pneumonectomy removed the infective focus. As at the time this case was reported, patient was in follow-up and doing well.

## CONCLUSION

The chest physiotherapy and incentive spirometry help in reducing the lung collapse. But if patient is reluctant to chest physiotherapy and coughing, it can lead to accumulation of respiratory secretions and formation of mucus plug. This mucus plug can cause collapse of the lung with superadded infections and ill consequences. Pneumonectomy is the last option to save the life of the patient if the general condition of the patient is continuously deteriorates even with all other measures to save the atelectatic and infective lung.

## REFERENCES

1. Breasted J. The Edwin Smith Surgical Papyrus. Vol.1. Chicago, University of Chicago Press, 1930.
2. Shorr R.M, Crittenden M, Indeck M. Blunt thoracic trauma: analysis of 515 patients. *Ann Surg* 1987;206:200.
3. Mary C.M. Blunt chest trauma. *emedicine.medscape.com/article/428723-overview* Updated: Jan 10, 2012.
4. Hedenstierna G, Rothen H.U. Ventilation and perfusion matching. *Anesthesia Biologic Foundations*. Edited by Yaksh T.L, Lynch C.L, Zapol W.M, Maze M, Biebuyck J.F, Saidman L.J. Philadelphia, Lippincott-Raven, 1998;pp 1349–66.
5. Gairdner WT. *Month. Journ Med Sci* 1851;12:440.
6. Loring S.H, Butler J.P. Gas exchange in body cavities, *Handbook of Physiology*. Section 3, The Respiratory System. Vol 4, Gas Exchange. Edited by Farhi LE, Tenney SM. Bethesda, American Physiological Society, 1987;pp 283–95.
7. Joyce C.J, Baker A.B, Kennedy R.R. Gas uptake from an unventilated area of lung: Computer model of absorption atelectasis. *J Appl Physiol* 1993;74:1107–16.
8. Gunnarsson L, Tokics L, Gustavsson H, Hedenstierna G. Influence of age on atelectasis formation and gas exchange impairment during general anaesthesia. *Br J Anaesth* 1991;66:423–32.
9. Serafini G, Cornara G, Cavalloro F, Mori A, Dore R, Marraro G, Braschi A. Pulmonary atelectasis during paediatric anaesthesia, CT scan evaluation and effect of positive end-expiratory pressure (PEEP). *Paediatr Anaesth* 1999;9:225-8.
10. Davis G.M, Coates A.L, Papageorgiou A, Bureau M.A. Direct measurement of static chest wall compliance in animal and human neonates. *J Appl Physiol* 1988;65:1093-8.
11. Bradford J.R. Massive collapse of the lung as a result of the gunshot wounds, with special reference to wounds of the chest. *Quart Journ Med* 1918-19;12:127.
12. Jacobaeus HC. A study of acute massive atelectatic collapse of the lung. *Brit Journ Radiol* 1930;3:50.
13. Jackson C and Lee. Massive collapse of the lung. *Ann Surg* 1925;82:364.
14. Krieder M.E, Lipson D.A. Bronchoscopy for atelectasis in ICU: a case report and review of literature. *Chest* 2003,124:344-350.

doi: <http://dx.doi.org/10.14194/ijmbr.1313>

**How to cite this article:** Khan M.S, and Sarkar U.N. Post-traumatic bronchial mucus plug leading to pneumonectomy  
*Int J Med Biomed Res* 2012;1(3):250-253

**Conflict of Interest:** None declared