

A giant hydronephrotic pelvic kidney mimicking an ovarian cyst in a 34-week pregnancy



Okunade K.S^{1*}, Sekumade A², Sajo A², Daramola E², Okojie O², Ojewola R.W³, Balogun O.S³, Afolabi B.B¹, Anorlu R.I¹

¹Department of Obstetrics and Gynaecology, College of Medicine, University of Lagos, Lagos, Nigeria. ²Department of Obstetrics and Gynaecology, Lagos University Teaching Hospital, Lagos, Nigeria. ³Department of Surgery, College of Medicine, University of Lagos, Lagos, Nigeria.

*Corresponding author: kehindeokunade@gmail.com, sokunade@unilag.edu.ng

Received: 16.04.16; Accepted: 20.06.16; Published: 28.06.16

ABSTRACT

Background: A giant hydronephrosis is defined as a dilated pelvi-calyceal system with an amount of urine exceeding one Litre in the urinary tract of an adult. It can mimic several other clinical conditions including a huge ovarian cyst. An ectopic pelvic kidney with hydronephrosis in pregnancy is a rare occurrence. **Aim:** This study documents a case of giant hydronephrosis that was wrongly diagnosed as an ovarian cyst. **Findings:** A 36-year old primiparous with a giant hydronephrosis which was initially diagnosed as an ovarian cyst. She was planned for a laparotomy with caesarean section and ovarian cystectomy at 34 weeks gestation. She was delivered of a live female neonate. Further exploration was done which revealed a left ectopic kidney. She had a left simple nephrectomy because the kidney appeared totally unhealthy. **Conclusion:** There is a need to be careful when dealing with cystic lesions of the abdomen. A high index of suspicion is required and further imaging other than ultrasound scan such as computerized tomography or magnetic resonance imaging may be necessary to make accurate diagnosis.

Key words: Caesarean section, ectopic gestation, hydronephrosis, urinary tract, cystectomy, ovarian cysts

INTRODUCTION

An ectopic kidney is a congenital abnormality in which a kidney is located inferior, superior, or on the opposite side of its usual position.^[1] About one in 900 people has an ectopic kidney giving a prevalence of 0.11%.^[1] It is a pelvic kidney when it is located below the pelvic brim and one of its rare complications is hydronephrosis. A giant hydronephrosis is defined as a dilated pelvi-calyceal system with an amount of urine exceeding one Litre in the urinary tract of an

adult.^[2] A giant hydronephrosis can mimic several other clinical conditions such as ascites, intraperitoneal cysts, retroperitoneal cysts and ovarian cysts or tumours.^[3] Therefore patient may undergo an unnecessary surgical exploration, wrong treatment or at times even a nephrectomy. We report on a case of hydronephrosis in a 34 week pregnant woman who had a surgical exploration and subsequent nephrectomy of a giant pelvic kidney wrongly diagnosed preoperatively as an ovarian cyst.



CASE PRESENTATION

A 36-year old primiparous (gravida 2, para 1) patient presented, following referral from a private hospital, to the emergency department at 34 weeks' gestation because of increasing lower abdominal pain of 2 weeks duration. The patient's last confinement was 10 years earlier during which she had an elective Caesarean section due to severe preeclampsia. The child was alive and well. She had no associated history of fever, chills, vaginal bleeding or dysuria. Her medical history was unremarkable, and this pregnancy had been uneventful till about 2 weeks prior to her presentation at the referring hospital. She had an ultrasound scan done 1 week earlier which revealed a normal cyesis with a coexisting huge adnexal mass. On examination, she was in painful distress, afebrile and anicteric. She had a blood pressure of 150/100mmHg and her pulse rate was 66 beats per minute, regular and with full volume. The abdomen was distended with an old sub-umbilical midline scar. It was slightly tensed with generalised tenderness that was more marked on the left lower quadrant. Fundal height and foetal parts were difficult to assess. Foetal heart rate detected using a hand held Doppler device was 146 beats per minute. The cervix was long and closed. Laboratory investigations revealed a normal full blood count, serum electrolytes, urea and creatinine, and urine microscopic findings (table 1). A bedside ultrasound scan showed a live singleton foetus at estimated gestational age of 35 weeks in transverse lie with coexisting left complex ovarian cyst measuring 50 x 30 x 15cm in diameter. The right ovary appeared normal and her left kidney was not visualised. The patient's blood pressure was stabilised with oral alpha methyldopa at a dose of 500mg 8 hourly and she was planned for a laparotomy with caesarean section and ovarian cystectomy. However, intra-operatively the uterus was found to be obscured by the huge cystic mass measuring 45 x 25 x 20cm in diameter (figure 1) which was deliberately decompressed by draining about 15 litres of seropurulent fluid to gain access to the uterus. She subsequently had a caesarean section with delivery of a healthy live male neonate with birth weight of 2.6kg and apgar score of 7 and 9 in 1 and 5 minute respectively. Exploration of the abdominal cavity revealed a healthy normal sized right kidney with absence of the left kidney. Further assessment of the decompressed pelvic mass revealed that it was a left ectopic kidney, after which she had a left simple nephrectomy as the kidney appeared totally unhealthy to be left behind (figure 2). The

patient did well postoperatively and was discharged on the 5th postoperative day. The histological examination of the cystic mass showed chronic pyelonephritis with marked dilatation of the pelvi-calyceal system. The patient was co-managed with the nephrologist and urologist and she has remained healthy with normal blood electrolytes, urea and creatinine till date.

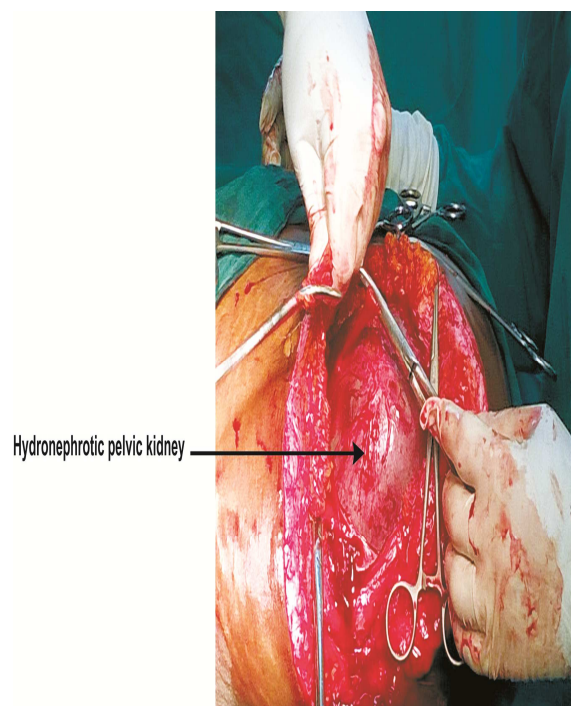


Figure 1: Hydronephrotic ectopic kidney after decompression (intra-operative finding)

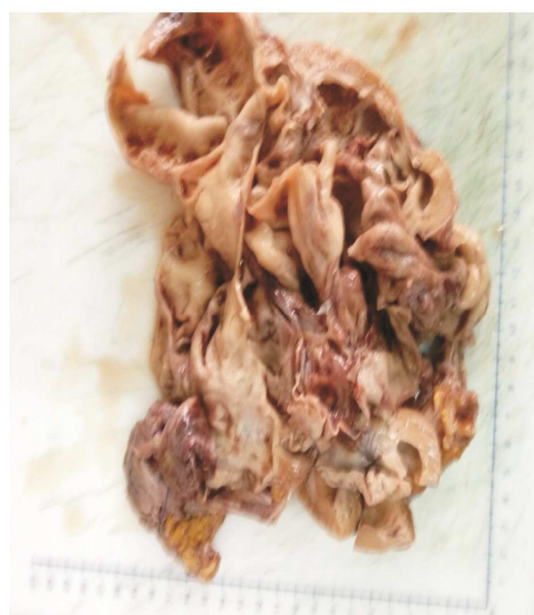

Figure 2: Fixed section of the hydronephrotic cystic mass

Table 1: Summary of results of laboratory investigations

S/N	Test	Result	Reference Range ^[11]
1.	Complete Blood Count		
	i. Haemoglobin	13	12-15g/dL
	i. Packed Cells Volume	36	35-44%
	i. White cells count	6	5.6-16.9 X 10 ⁹ /L
	/ Platelet count	250	146-429 X 10 ⁹ /L
2.	Electrolytes, blood urea and creatinine		
	i. Urea	6.1	3-11mg/dL
	ii. Creatinine	0.53	0.4-0.9mg/dL
	iii. Electrolytes	Within normal ranges	
3.	Urine microscopy	No growth after 48 hours of incubation	

DISCUSSION

The differential diagnosis of ovarian masses in pregnancy is diverse.^[4,5] Uncommon aetiologies that have been sonographically noted to mimic ovarian masses in pregnancy include uterine leiomyomata, mesenteric lipomas, and, rarely, hydronephrosis.^[4-6] There are few case reports of mistaken diagnosis in the literature. An unusual case of hydronephrotic pelvic kidney mimicking an ovarian cyst was reported by Ko *et al.*^[7] Neena *et al.*^[8] also reported an ectopic hydronephrotic kidney masquerading as an ovarian cyst during pregnancy but this has never been reported in any Nigerian or other African literatures. Ovarian cystic masses are easier to distinguish from renal lesions in non-gravid patients and during early pregnancy in comparison with later in gestation.^[9] With gradual uterine enlargement, with advancing gestational age, and once the uterus rises out of the pelvis and becomes an abdominal organ, the potential locations of the ovary and the kidney become closer to each other.^[7,8] As a result, differentiation between these two separate organs, especially in pathologic conditions, may become difficult.^[7] In the index patient, the congenital ectopic pelvic kidney which was initially asymptomatic became symptomatic with increasing abdominal pain associated with worsening uretero-pelvic junction (UPJ) obstruction with subsequent huge hydronephrosis, possibly worsened by further compression due to the enlarging uterine size.^[7,8] The sonographic depiction in the patient was consistent with a large cystic ovarian mass occupying the abdomen and the pelvis.^[8] A very significant observation is that just as we saw in this case and other previous case reports outside Nigeria, it appears that hydronephrotic pelvic kidney occur more commonly on the left for reason that is still largely unclear.^[9,10] It had also been reported that occasionally, a patient

with the UPJ obstruction may present with hypertension as seen in our patient; the pathophysiology being a functional ischemia with reduced blood flow caused by the enlarged collecting system that produces a renin-mediated hypertension.^[10]

CONCLUSION

An ectopic pelvic kidney with hydronephrosis in pregnancy is a rare occurrence and therefore error in its diagnosis may have significant health consequences for the patient. One needs to be careful when dealing with huge cystic lesions of the abdomen in pregnancy and thus hydronephrotic kidney should always be a strong differential diagnosis. A high index of suspicion is required coupled with the involvement of an experienced sonologist to making accurate diagnosis in the advanced stage of pregnancy. Further imaging such as computerized tomography or magnetic resonance imaging may sometimes be necessary in highly specialized centres to assist the clinician in making the correct diagnosis prior to instituting any surgical intervention with the involvement of a multidisciplinary team comprising of the obstetrician/gynaecologist, urologist and nephrologist.

REFERENCES

- Bauer SB. Anomalies of the upper urinary tract. In: Wein A, ed. Campbell-Walsh Urology. 9th ed. Philadelphia: Saunders Elsevier 2007:3269–3304.
- Mediavilla E, Ballester R, Correas MA, Luis Gutierrez J. About a case report of giant hydronephrosis. *Case Rep Urol.* 2013;3. <http://dx.doi.org/10.1155/2013/257969> Article ID 257969.
- Yang W.T, Metreweli C. Giant hydronephrosis in adults: the great mimic. *Early*

diagnosis with ultrasound. *Postgrad Med J* 1995;71:409–412

4. Sherer DM, Maitland CY, Levine NF, Eisenberg C, Abulafia O. Prenatal magnetic resonance imaging assisting in the differentiating between large degenerating intramural leiomyoma and complex adnexal mass during pregnancy. *J Matern Fetal Med* 2000;9:186–191.

5. Sherer DM, Lysikiewicz A, Chambers JT, Frager D, Eliakim R, Miodovnik M. Large mesenteric Lipoma ultrasonographically mimicking a mature cystic teratoma during pregnancy. *J Ultrasound Med* 2002;21:473–476.

6. Malhotra N, Roy KK, Garg PK, Takkar D. Ectopic hydronephrotic kidney masquerading as an ovarian cyst during pregnancy. *Eur J Obstet Gynecol Reprod Biol* 2001;97:239–240.

7. Ko S.F, Wan Y.L, Hsieh H.H, Huang F.J, Ng S.H, Lee T.Y. Hydronephrotic pelvic kidney mimicking an ovarian cyst. *Ultrasound Obstet Gynecol* 1998;11:152–156.

8. Neena M. Ectopic hydronephrotic kidney masquerading as an ovarian cyst during pregnancy. *Eur J Obstet Gynecol Reprod Biol* 2001;97:239–240.

9. Sherer D.M, Stimpfil R., Hellman M., Zinn H., Bitton C., Angus S. Marked maternal ureteropelvic obstruction mimicking a large ovarian mass at 20 weeks' gestation. *J Ultrasound Med* 2005;24:1309–1312.

10. Nerli R.B, Mungarwadi A, Mudegowdar A.S, Patil A, Hiremath M.B, Ghagane S. A giant hydronephrosis mistakenly diagnosed as ovarian tumor in a pregnant woman. *Urol Case Rep* 2016;4: 20–21.

11. Normal Reference Ranges and Laboratory Values in Pregnancy. www.perinatology.com

doi: <http://dx.doi.org/10.14194/ijmbr.5.2.1>

How to cite this article: Okunade K.S, Sekumade A, Sajo A, Daramola E, Okojie O, Ojewola R.W, Balogun O.S, Afolabi B.B, Anorlu R.I. A giant hydronephrotic pelvic kidney mimicking an ovarian cyst in a 34-week pregnancy. *Int J Med Biomed Res* 2016;5(2):57-60

Conflict of Interest: None declared

Submit your valuable manuscripts to Michael Joanna Publications for:

- User-friendly online submission
- Rigorous, constructive and unbiased peer-review
- No space constraints or colour figure charges
- Immediate publication on acceptance
- Unlimited readership
- Inclusion in AJOL, CAS, DOAJ, and Google Scholar

Submit your manuscript at
www.michaeljoanna.com/journals.php



Submit your next manuscript to any of our journals that is the best fit for your research



International Journal of Medicine and Biomedical Research

Scope: *IJMBR publishes cutting edge studies in medical sciences*


Editor-in-Chief: *Sofola A. Olusoga, MBBS, PhD, FAS*

Deputy Editor: *Lehr J. Eric, MD, PhD, FRCSC*

URL: *www.ijmbr.com*

E-mail: *editor@ijmbr.com*

Pissn: *2277-0941, eISSN: 2315-5019*



International Journal of Ethnomedicine and Pharmacognosy

Scope: *IJEP publishes novel findings on the use of complementary and alternative medicine in the management of diseases*

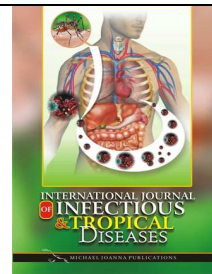
Editor-in-Chief: *Dickson A. Rita, B.Pharm, GCAP, PhD, MPSGh, MCPA*

Deputy Editor: *Kuete V., PhD*

URL: *www.ijepharm.com*

E-mail: *editor@ijepharm.com*

Pissn: *2437-1262, eISSN: 2437-1254*



International Journal of Infectious and Tropical Diseases

Scope: *IJITD publishes interesting findings on infectious and tropical diseases of public health importance*

Editor-in-Chief: *Yang Z., PhD*

Deputy Editor: *Liping L.P., MD, PhD*

URL: *www.ijitd.com*

E-mail: *editor@ijitd.com*

Pissn: *2384-6607, eISSN: 2384-6585*

Reasons to publish your manuscript with Michael Joanna Publications:

• User-friendly online submission • Rigorous, constructive and unbiased peer-review • No space constraints or coloured figure charges • Immediate publication on acceptance • Authors retain copyright • Inclusion in AJOL, CAS, CNKI, DOAJ, EBSCO, Google Scholar, and J-Gate • Unlimited and wide readership • Member of COPE and CrossRef

Editorial Director

Professor Sofola A. Olusoga,
Department of Physiology,
University of Lagos,
Nigeria.

Tel: +234(0) 7093848134

Email: enquiry@michaeljoanna.com

www.michaeljoanna.com

