



ASN-PH-020919
ISSN: 2315-537X

International Journal of Herbs and Pharmacological Research

IJHPR, 2012, 1(3): 68–74.

www.antrescentpub.com

RESEARCH PAPER

EFFECT OF L- ARGININE ON TESTICULAR HISTOLOGY FOLLOWING 720⁰ TORSION – DETORSION

^{*1}*Olugbenga, M.A.*, ²*Duru, F.I.O.*, ³*Ogedengbe, O.O.*, ⁴*Ogbodo L.A.*, ⁵*Babatunde A.*

Department of ¹Anatomy, College of Medicine, Ambrose Alli University, Ekpoma, Edo, Nigeria; ²Anatomy, University of Lagos, Lagos, Nigeria. ³Anatomy, Afe Babalola University, Ado-Ekiti, Ekiti, Nigeria. ⁴Morbid Anatomy, University of Nigeria Teaching Hospital, Ituku/Ozalla, Enugu, Nigeria. ⁵School of Post-Basic Nursing, Irrua Specialist Teaching Hospital, Irrua, Edo -Nigeria.

Corresponding author: docmaryll@yahoo.com

Received: 10th August, 2012

Accepted: 12th October, 2012

Published: 31st October, 2012

ABSTRACT

This study evaluates the effect L- arginine on testicular histology following 720⁰ torsion-detorsion at different time intervals. Twenty male rats (130- 200g) were used. They were grouped into seven groups of three rats each (A-G) with group G as control. With an atraumatic silk suture through the tunica albuginea, unilateral testicular torsion was created in groups A-F by rotating the left testicles in the clockwise direction along the longitudinal axis for 15, 30, and 45 minutes respectively. Alternate groups (A,C,E) were treated intraperitoneally with 150mg/kg body weight of L- arginine for 1 hour after detorsion, while the remaining groups (B,D,F) were untreated. The results showed that the control tissue sections presented normal features while group B (untreated) presented atrophic seminiferous tubules with no luminal spermatozoon. Similarly, group C (treated) presented severe oedema, atrophic seminiferous tubules with hyperplasia of germ cells, and reduction in size and thickness of lining cells of the seminiferous tubules. The untreated group E however, showed mild oedema but normal seminiferous tubules with luminal spermatozoa and germ cells in various stages of development, while group F showed severe interstitial oedema as well as loss of germ cells. Comparatively therefore, there was an improvement in the treated group E as compared with that of the untreated group F. Our results suggest therefore, that L- arginine tends to reduce oxidative stress in torsioned testes and helps maintain the seminiferous epithelium, thereby preserving the cells of the spermatogenic series

Key words: Testicular torsion, L-arginine, Ischemia-reperfusion, Rotation, Spermatic cord

INTRODUCTION

Testicular torsion is the act of twisting, turning rotating the spermatic cord and the testis about its axis (Dorland, 2000). It is a surgical emergency in humans that may lead to testicular injury and infertility if untreated within few hours. Those at risk include young men and adolescent boys, as well as those who have had previous experiences. It is estimated that one out of every 4000 men below the age of 25years will have torsion of the testis (Ringdahl and Teague, 2006). The main pathophysiology of testicular torsion is ischemic reperfusion injury of the testis caused by twisted spermatic cord and its release (Anim et al., 2005). Reperfusion of ischemic tissue leads to a cascade of events that injure the tissue. The injuries produced by reperfusion can be more severe than the injuries induced by ischemia (Ozokutan et al., 2006).

Acute, severe scrotal pain is the consistent presentation of testicular torsion, which is sometimes associated with nausea, vomiting and low-grade fevers (Riyad et al., 2009). On physical examination, the hemiscrotum of the

affected side is typically swollen, tender and inflamed, with pain unrelieved by elevation of the scrotum (Noske et al., 2005).

Experimentally, the testis can be rendered ischemic via two different methods. One method is to twist the spermatic cord and the other method is to clamp the spermatic cord or artery. Both procedures have been used in animal models; however because the twisting of the spermatic cord more closely resembles clinical testicular torsion, it is most commonly used (Riyad et al., 2009). It is important to point out that the injury to the tissue occurs due to both the ischemic period and the reperfusion (Riyad et al., 2009).

Arginine is one of the twenty amino acids that constitute protein. It exists as L – arginine and D- arginine form (Chin – Dusting et al., 1996). However L- arginine form is more compatible to the human body (Chin- Dusting et al., 1996). It is involved in several physiological and pathological processes including regulation of blood flow (Jing et al., 2009). It may have antioxidative properties and reduces accumulation of compounds such as ammonia and plasma lactate, by-product of physical exercise (Long et al., 2006).

Food sources of arginine include peanuts, almond nuts, walnuts, hazelnuts, lentils, brazilnuts, cashew nuts, flax seed, beans, pecan nuts, soya beans, wheat flour, garlic, onion, egg milk, pork, chicken and shrimp (USDA nutrient Database, 2006). Both acute and chronic administration of L-arginine evoke benefits in improving endothelial function, although the precise molecular mechanisms by which L- arginine improves function remains puzzling (Bode- Boger, 2005).

L- arginine has been used as supplementation in various conditions in man as well as experimentation animals. These include cardiovascular conditions, genitourinary conditions, preeclampsia, HIV infection and Aids, growth cancer, diabetes and other conditions (Thorne, 2005). Other L- arginine benefits include maintenance of nitrogen balance, removal of excess ammonia, liver detoxification, reduction of alcohol toxicity effects and wound healing (Chin- Dusting et al., 1996).

Doses of arginine used in clinical research have varied considerably from as little as 500mg/day for oligospermia to as much as 30g/day for cancer, preeclampsia and premature uterine contractions (Thorne, 2005). It has also been helpful in situations characterized by oxidative stress, but its effects are yet to be verified on testicular tissue that underwent testicular torsion.

Hence this study is designed to test the usefulness of L- arginine in testicular torsion and evaluates its effect on testicular histology (semminiferous tubules and the interstitium) following 720° torsion-detorsion at different intervals ranging from 15minutes to 45minutes

MATERIALS AND METHODS

Experimental Animals: A total of twenty male wistar rats, weighing 130 – 200g were used for the experiment. The animals were procured from Isaac animal farm in Ipetu Local Government of Osun State. They were kept in the animal house of the Anatomy Department, College of Medicine, University of Lagos, at an average temperature of $28 \pm 2^{\circ}\text{C}$, with 12hr light/12hr dark cycle and were fed with commercial livestock feeds and tap-water ad-libitum for three weeks. Animals were randomly divided into seven groups (A-G) of three each.

Table 1: The experimental procedure for each group

Group	Torsion Time	L-arginine administration	Detorsion/reperfusion time
A	15 minutes	150mg/kg body weight	1 hour
B	15 minutes	-	1 hour
C	30 minutes	150mg/kg body weight	1 hour
D	30minutes	-	1 hour
E	45 minutes	150mg/kg body weight	1 hour
F	45 minutes	-	1 hour
G	-	-	-

Unilateral Testicular Torsion: Unilateral testicular torsion was created by rotating the left testicles in the clockwise direction along their longitudinal axis 720°. Torsion was maintained in position by fixing the testis to the

scrotum with an atraumatic silk suture (4/0) through the tunica albuginea (Reyes et al., 1997; Dokucu et al., 2000) for one hour before orchietomy was performed and tissues immediately fixed in Bouin's fluid. All surgical procedures were performed under Ketamine anesthesia.

RESULTS

The morphological criteria used for determining the extent of damage in the seminiferous tubules was as described by Chakraborty et al. (1986) and Reyes (1999). Group A (treated) showed normal seminiferous tubules lined by 4-5 cell thickened germ cells in various stages of development (spermatogenic series). The Sertoli cells were intact and Leydig cells were seen in the interstitium. Group B (untreated group) showed atrophic seminiferous tubules characterized by reduction in size and thickness of lining cells of the seminiferous tubules, to about two (2) cell layers thick. Spermatogonia were present but there were only a few luminal spermatozoa. In group C (treated), normal seminiferous tubules were seen. This was characterized by normal spermatogenic series and luminal spermatozoa. The interstitium of this group also remained intact. Group D (untreated) showed mild atrophy of seminiferous tubules. Although luminal spermatozoa are seen, the atrophy was more peculiar to the spermatogonia. Also, the interstitium of this group showed mild oedema. The treated group E, showed normal seminiferous tubules, lined by 4-5 cell thick germ cells in various stages of development, and containing luminal spermatozoa. There was mild oedema in the interstitium. Group F showed severe interstitial oedema as well as loss of germ cells indicating that there was an improvement in the treated group E when compared with the untreated group F. However, the torsioned testes in groups D, E and F showed bleeding into the interstitium.

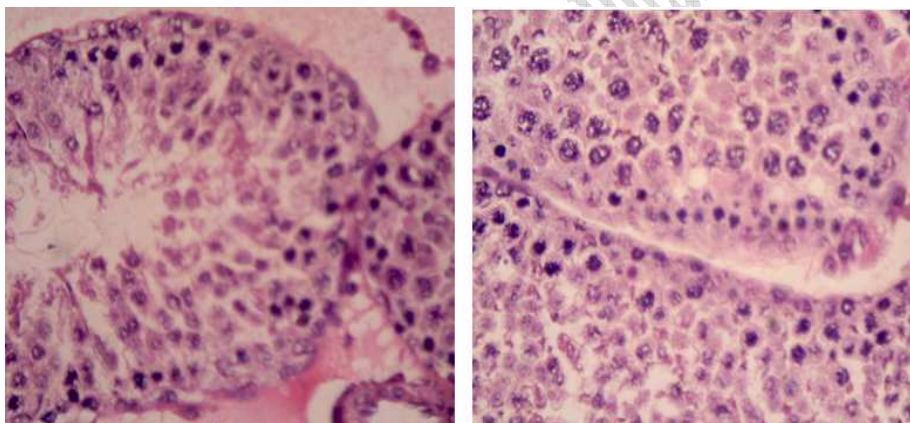


Plate 1: Group G (Control) Testes (H&E X400) showing normal testicular histology.

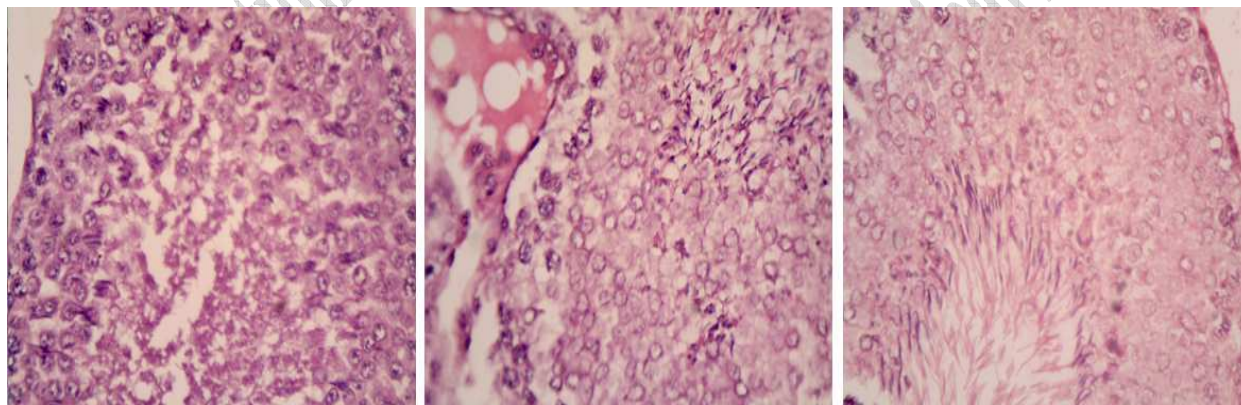


Plate 2: Group A (treated) Testes section (H&E X400) showing normal seminiferous tubules lined by 4-5 cell thickened germ cells in various stages of development (spermatogenic series).

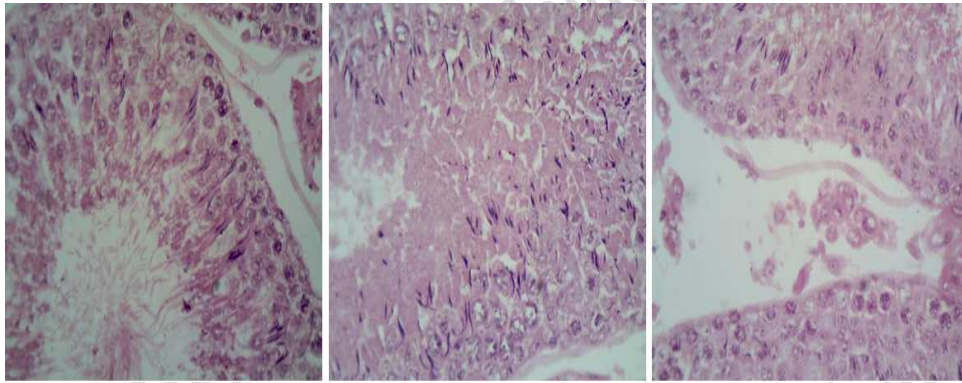


Plate 3: Group B (untreated group) Testes section showing atrophic seminiferous tubules characterized by reduction in size and thickness of lining cells of the seminiferous tubules, to about two (2) cell layers thick. Spermatogonia were present but there were only a few luminal spermatozoa.

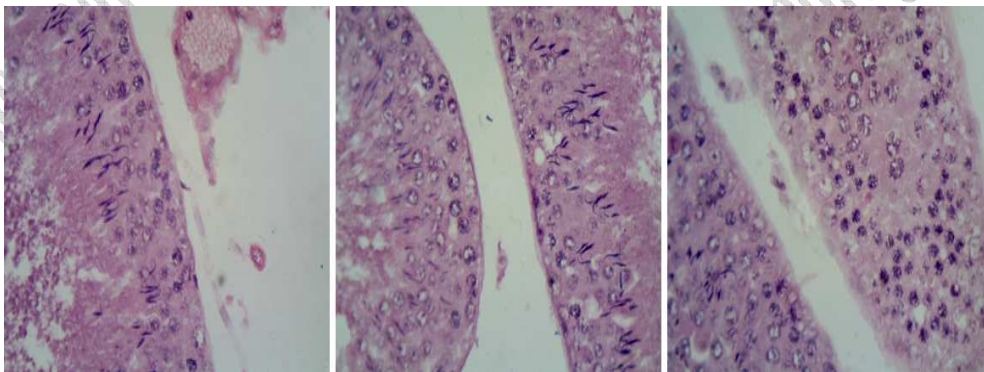


Plate 4: Group C (treated) Testes section (H&E x400) showing normal seminiferous tubules characterized by normal spermatogenic series and luminal spermatozoa. The interstitium also remained intact.

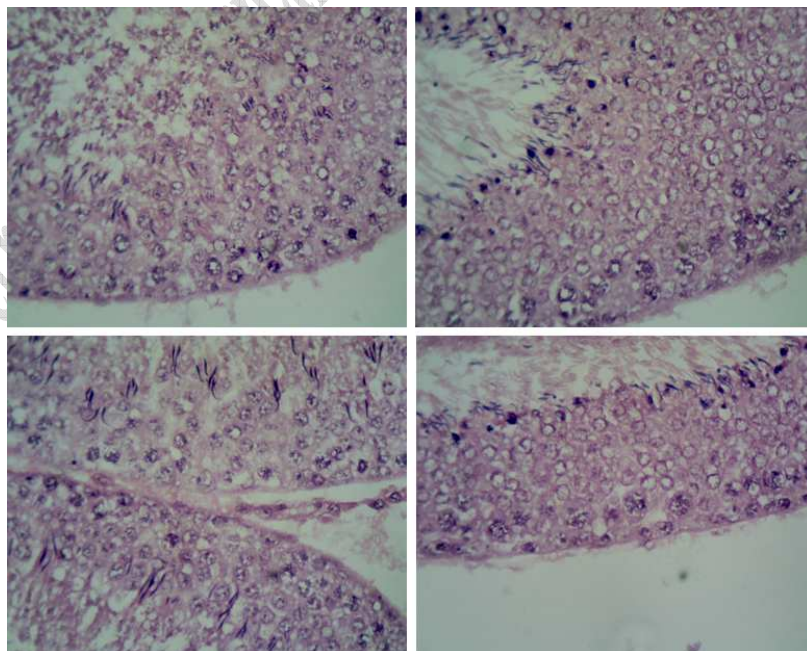


Plate 5: Group D (untreated). Testes (H&E x400) showing mild atrophy of seminiferous tubules. Although luminal spermatozoa were seen, atrophy was more peculiar to spermatogonia and the interstitium showed mild oedema.

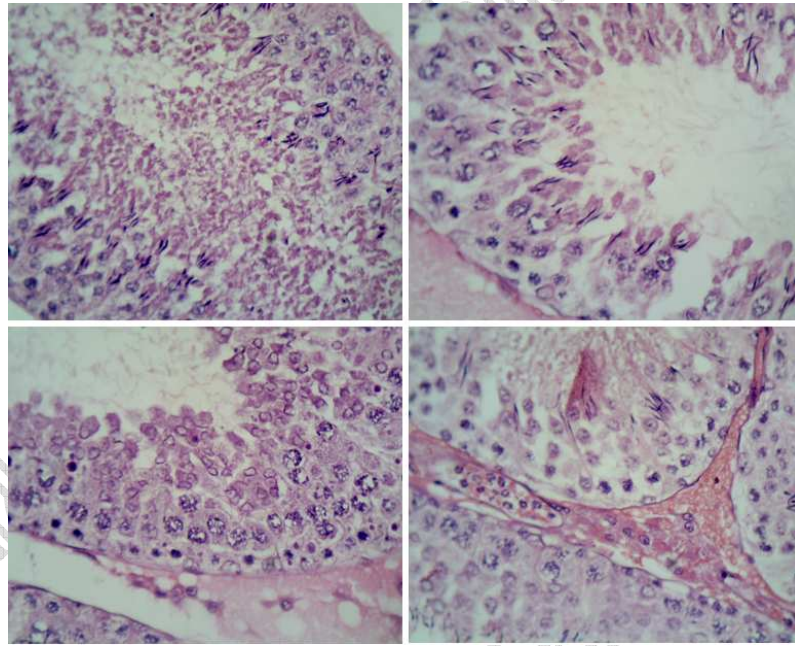
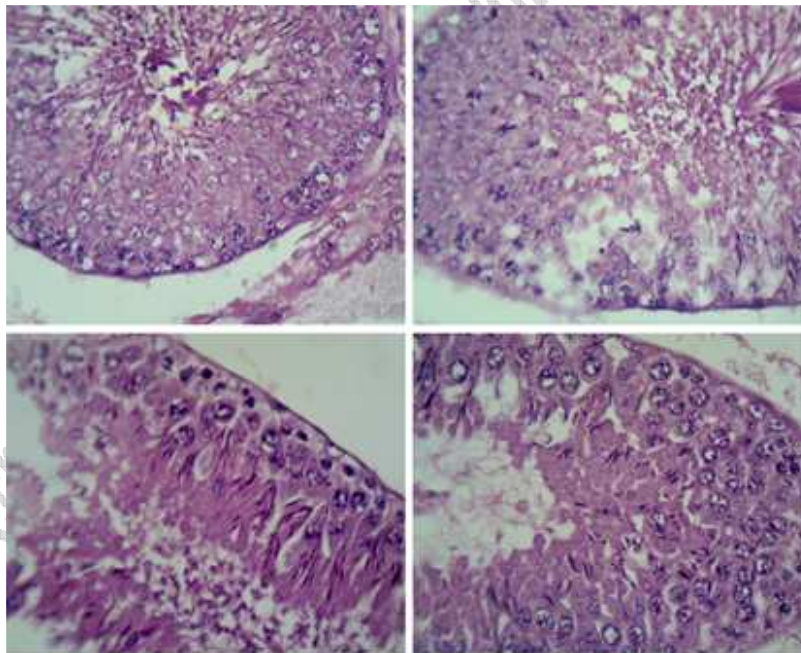


Plate 6: Group E (treated). Testes (H&E x400) showing normal seminiferous tubules, lined by 4-5 cell thick germ cells in various stages of development, and containing luminal spermatozoa.



Group F: Group F (untreated) Testes section (H&E x400) showing severe interstitial oedema as well as loss of germ cells indicating that there was an improvement in the treated group E when compared with the untreated group F.

DISCUSSION

The results of this study have shown that intraperitoneal administration of L-arginine, maintained the spermatogenic cell layers in the treated groups. In fact, the histological observations in group A (treated) and B (untreated) affirms the findings of Viguera et al., (2004). On the whole, the cells of the interstitium appear more sensitive to vascular changes than the germ cells, and in most of the cases, the interstitial cells are degenerated, while the tubules contained a few normal germ cells (Harrison, 2004). According to Schinz and Slotopolsky (1924), the more matured germ cells seem also, to be more sensitive to vascular changes than spermatogonia and sertolic cells.

Furthermore, the interstitial bleeding observed in group D, E, and F, might have been due to increased pressure in the vessels following vascular obstruction. Comparatively, Leydig cells are more prone to degenerative changes when testicular vascularity is compromised than the Sertoli cells and this was evident in the atrophic seminiferous tubules. Usually, testicular torsion, which can occur in both neonates and adults, has adverse effects on seminiferous tubules and testicular interstitium, as it interferes with spermatogenesis (Robert and Spencer, 2011; Schneck et al, 2007).

From the foregoing therefore, our results has shown that L- arginine tends to reduce oxidative stress in torsioned testes and helps maintain the seminiferous epithelium thereby preserving the cells of the spermatogenic series. This specifically affirms L-arginine's antioxidant potentials and its capability to reduce accumulation of compounds such as ammonia and plasma lactate, which are by products of physical stress. However the timing of administration is very important for desired results.

ACKNOWLEDGEMENT

We acknowledged the support provided by the research staff of Anthonio Research Center, Ekpoma-Nigeria towards the success of this study.

REFERENCES

Anim J. T., Kehinde, E. O., Prasad, A., Varghese, R. (2005). Morphological Responses of the rabbit testis to Ischemic/ Reperfusion injury due to torsion. *Urology International* 75: 258 – 263.

Bode-Boger, S. M. (2006). Effects of L-arginine Supplementation on NO production in man. *European Journal of Clinical Pharmacology*. 62: 91-99.

Chakraborty, J., Sinha Hinkim, A. P., Jhunjhunwala, J. (1986). Torsion of the spermatic cord- a long term study of the contralateral testis. *Journal of Urological Research* 14: 257 – 260.

Chin-Dusting JPF., Alexander CT., Amold PJ., Hodgson WU., Lux AS., Jennings GLR. (1996). Effect of in vivo and in vitro L-arginine supplementation on healthy human vessels. *J. Cardio. Pharm.* 28 (1): 158 – 166.

Dorland (2006). *Dorland's illustrated Medical Dictionary*. 29th Edition. W. B. Saunders Company. 1853.

Dukucu AI., Ozturk H., Ozdemir E., Ketani A., Buyukbayram H., Yucesan S. (2000). The protective effects of nitric oxide on the Contralateral testis in prepubertal rats with unilateral testicular torsion. *British J. Urology International*; 85: 767 – 771.

Harrison, R. G. (2004). The distribution of vassal and cremasteric arteries to the testis and their functional importance. *Journal of Anatomy* 83:267- 284.

Long JHD, Lira VA, Soltow QA, Betters JL, Sellman JE, Criswell DS. (2006). Arginine supplementation induces myoblast fusion via augmentation of nitric oxide production. *Journal of Muscle Research and Cell Motility*; 27(8):577–584.

Noske, H. D., Kraus, S. W., Altinkilic, B. M., Weidner, W. (1998). Historical milestone regarding torsion of the scrotal organs. *Journals of urology* 159: 16.

Ozokutan, H. D., Kucukaydin, M., Muhtaroglu, S. (2000). The Role of Nitroxide in testicular Ischemia- reperfusion injury. *Journal of pediatric Surgery*. 35: 101-103.

Reyes, G., Mendoza, E., Viguera, R. M., Villegas, F., Medina, P., Rojas, J. C. (1997). The effect of streptokinase-streptodornase administration on histological damage following testicular torsion. *Proceedings of the Western Pharmacology Society* 42: 77-78.

Ringdahl E. and Teague L. (2006). Testicular torsion. *Am. Fam. Physician*; 74: 1739 – 1743.

Riyad T. E., Parviz K. K., Terry T. T., and Jeffrey J. Lysiak (2009). Twist and Shout: A Clinical and Experimental Review of Testicular Torsion Korean Journal of Urology. Vol. 50 No. 12: 1159-1167.

Robert N. L., Spencer W. B. (2012). Testicular Torsion: Potentials pitfalls in its diagnosis and management. *Journals of Pediatrics and Child health*. 48:E30 – E32.

Schneck FX, Bellinger ME. Abnormalities of the testis and scrotum and their surgical management. In: Wein AJ, Kavoussi LR, Novick AC, Partin AW, Peters CA, eds. *Campbell- Walsh Urology*. 9th ed. Philadelphia, Pa: WB Saunders; 2007:Chapter 127.

Schinz, H. R., Slotopolsky, B. (1924). Beitrage Zur experimentellen Pathologie des Hodens und Zur. Histology und Histogenese des normalen Hodens der Hodenatrophie und der Hodenknrose. N. Derkschr. Schweiz. Naturf. Ges. 61: 27 – 137.

Thorne Research Inc. (2005). L – Arginine. 10 (2): 139 – 147.

Vigueras, R. M., Reyes, G., Rojas, J. C., Rojas, P., Hernandez, R. (2004). Testicular torsion and its effects on spermatogenic cycle in contralateral testis of rats. *Journal of Laboratory Animal* 38: 313 – 320.

AUTHORS' CONTRIBUTIONS

All the authors (Olugbenga, M.A., Duru, F.I.O., Ogedengbe, O.O., Ogbodo L.A. Babatunde A) actively contributed to the successful presentation of this research paper.