

IVERMECTIN-ALBENDAZOLE COMBINATION THERAPY IN LYMPHATIC FILARIASIS OF THE UPPER LIMB: CASE REPORT

*¹EMORDI J.E. and ¹IRIBHOGBE O.I.

¹Department of Pharmacology and Therapeutics, College of Medicine, Ambrose Alli University, Ekpoma, Edo State Nigeria.

Correspondence: drjonathan.emordi@gmail.com

ABSTRACT

The commonest manifestation of lymphatic filariasis is lymphoedema, which on progression leads on to elephantiasis. Even though lower limbs are commonly affected, upper limbs involvement is rarely reported in West Africa especially in females. In the present report a 19 year old female (BMI 20.49 kg/m²) in the West-African sub-region presented with swelling of the right upper limb of 4 weeks duration with associated pruritus and hyperpigmented lesions interspersed with hypopigmentation in the affected limb. There was a dramatic recession in the lymphoedema within 2 weeks following the administration of ivermectin and albendazole combination therapy. The adverse effect observed following the use of this combination was mild. This confirms the efficacy and safety of the above combination in the management of lymphatic filariasis.

Keywords: Lymphatic filariasis, Lymphoedema, Combination therapy, Ivermectin, Albendazole

6th December, 2013

Accepted: 22th January, 2014

Published: 31st January, 2014

INTRODUCTION

Lymphatic filariasis is caused by the lymphatic-dwelling nematodes; *Wuchereria bancrofti*, *Brugia malayi* and *B timori* that are transmitted to humans by mosquitoes (Pani et al., 2005; Kaliwal et al., 2010). It is a common tropical parasitic disease affecting an estimated 120 million people in the world (WHO 2010). About one-third of the affected population lives in India (Swaminathan et al., 2012). *Wuchereria bancrofti* accounts for approximately 90% of the disease burden while *Brugia malayi* contributes the remaining 10% (WHO 1992). Second to psychiatric illness, it is the leading cause of permanent and long-term disability (WHO 1995, Emilio 2008). Advances in medical science have helped not only in better understanding of the pathogenesis of this disease, but also in the diagnosis, management and in planning effective strategies for its global prevention. Newer understanding in the clinical manifestations has helped to improve the current trend in management (Ottesen and Ramachandran, 1995).

In an endemic area, the largest group of affected individuals are healthy young adults and children who in spite of being clinically asymptomatic, harbour microfilaria in their peripheral blood (Anitha and Shenoy, 2001). It is important to note that even at this stage of the disease, abnormalities of the lymphatic vessels like dilatation appears to be irreversible even after treatment (Freedman et al.,

1994). Attacks of fever and chills due to acute adeno-lymphangitis are the commonest acute manifestations, which occur in the affected limbs or sometimes involve the genitalia. These episodes may be seen both in the early and late stages of the disease. The affected area is painful, tender, warm, red and swollen. The lymph nodes in the groin and axilla, are frequently inflamed. These acute adeno-lymphangitis attacks recur many times a year in patients with filarial swelling, their incidence increasing with the degree of lymphoedema. Secondary infections due to bacteria like streptococci are responsible for these acute episodes (Suma et al., 1997). In the affected limbs, lesions which favour entry of these infecting agents can be demonstrated, either in the form of fungal infection in the webs of the toes, minor injuries, eczema, insect bites or infections.

These adeno-lymphangitis attacks are responsible for the persistence and progression of the swelling leading to elephantiasis not only of the limbs but also of the external genitalia and breasts (Shenoy et al., 1999). Acute manifestations directly caused by adult worms are usually rare. They are seen when the adult worms are destroyed in the lymphatics either spontaneously or by drugs like diethylcarbamazine. Small tender nodules form at the location of dead adult worms either in the scrotum or along the lymphatics. Additionally, lymph nodes may become tender and inflamed, large lymphatics may stand out

as long tender cords underneath the skin, usually along the sides of chest or the upper arm and axilla associated with restriction of movement of affected limb. Though transient oedema may occur sometimes, these episodes are not associated with fever, toxemia or evidence of secondary bacterial infections. They generally subside without any treatment (Emilio, 2008).

The commonest chronic manifestation of lymphatic filariasis is lymphoedema, which on progression leads on to elephantiasis. Though lower limbs are commonly affected, upper limbs and male genitalia are also involved. In females rarely, the breast and the external genitalia may also become elephantoid (Dreyer et al., 1997; Emilio, 2008). In repeated adeno-lymphangitis, episodes responsible for the progression of lymphoedema continue to occur. This is due to the fact that the presence of moisture in the web spaces of the closely apposed swollen toes promotes fungal infections damaging the skin, which in turn favour infecting organisms. For this reason, the frequency of adeno-lymphangitis episodes is shown to increase in the rainy season, when people have to wade through water in the lanes (Shenoy et al., 1998). Elephantiasis resulting from *B. malayi* infection typically affects the distal portions of the extremities. Unlike bancroftian filariasis, *B. malayi* rarely affects genitalia and does not cause funiculitis, orchitis, epididymitis, hydrocele, or chyluria; conditions more readily observed with bancroftian infection (John and Petri, 2006).

CASE REPORT

Clinical Presentation: The case involves a 19 year old girl from the South West geo-political zone of Nigeria. Two years prior to presentation she was resident in a riverine community in Sabo, Edo State, before relocating to Ekpoma also in Edo State, Nigeria. While in Sabo, the patient went to the river-side to swim once. Two years after, she presented with a 4 week history of swelling of the right upper limb with associated intense pruritus in the affected limb. The patient also noticed intense feeling of tightness in the affected limb aggravated by placing the limb in water. This was preceded by a sudden onset of intermittent febrile episode and headaches. On examination patient was found to have unilateral oedema of the right upper limb with evidence of hypo and hyper-pigmented skin lesions in the affected limb. However, there was no evidence of peripheral lymphadenopathy.

An initial assessment of lymphatic filariasis was made. Blood samples were collected for microscopy,

hematological and biochemical investigations. Urine sample was also collected for analysis.

Laboratory Findings: Microscopy

- **Giema Stain:** *Plasmodium falciparum* present. Parasite count = 380/ μ L, microfilaria not seen in blood film.
- **Wet mount preparation of Serum:** *Wuchereria bancrofti* present (see plate 1 and 2)
- **Wet mount preparation of urine:** Microfilaria absent.
- **Full Blood Count:** PCV = 37%, Hb=12.3g/dl, WBC=6800/mm³. Differential count: Lymphocytes = 63%, Neutrophils = 36%, Monocytes = 1%, Eosinophils = 0%, Basophils = 0%

Urinalysis

- Appearance: Slightly turbid. Colour: amber
- Blood, bilirubin, glucose, ketone and nitrite = negative
- Urobilinogen = 0.2, pH = 9.0, Specific gravity = 1.005

Liver Function Test

- Total bilirubin = 0.4 (0.1-1.1) mg/dl; Conjugated Bilirubin = 0.2 (\leq 0.5) mg/dl
- AST = 15 (\leq 12) I.U/L; ALT = 11 I.U/L (\leq 12) I.U/L; Alkaline phosphate = 57 (9-35) I.U/L

Electrolyte/Urea/Creatinine

- Potassium = 3.6 (3.5-5.3) mmol/l; Sodium = 139 (135-140) mmol/l
- Urea = 13 (10-55) mg/dl; Creatinine = 0.7 (0.7-1.4) mg/dl

DISCUSSION

This report revealed a rare case of lymphatic filariasis of the upper limb in Ekpoma, Edo State, Nigeria. Surprisingly, lymphadenopathy and eosinophilia were absent at presentation. Additionally, the electrolyte status and hematological findings were essentially normal. Worthy of note was the dramatic response observed following the administration of a single dose combination of ivermectin (0.2mg/kg) and albendazole (400mg). Two days (48 hours) after the use of these agents, the patient complained about a more intense pruritus which receded after the administration of intramuscular promethazine. In the management of this condition the use of crepe bandage in the affected limb also contributed remarkably to the recession in lymphoedema. The finding also demonstrated the efficacy of a single

dose combination of ivermectin and albendazole in

the management of this condition.

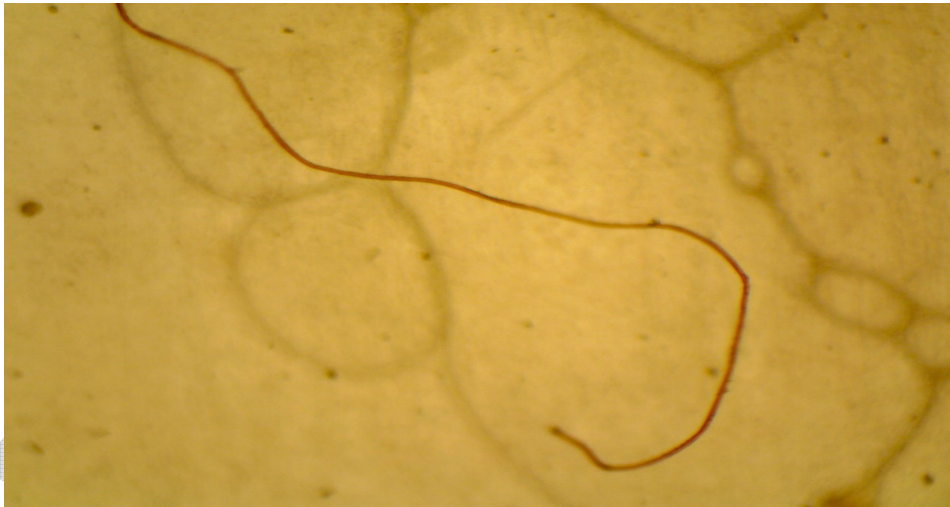


Plate 1: Wet mount micrograph showing anterior end of *W. bancrofti* in serum of patient (X 40 objective)

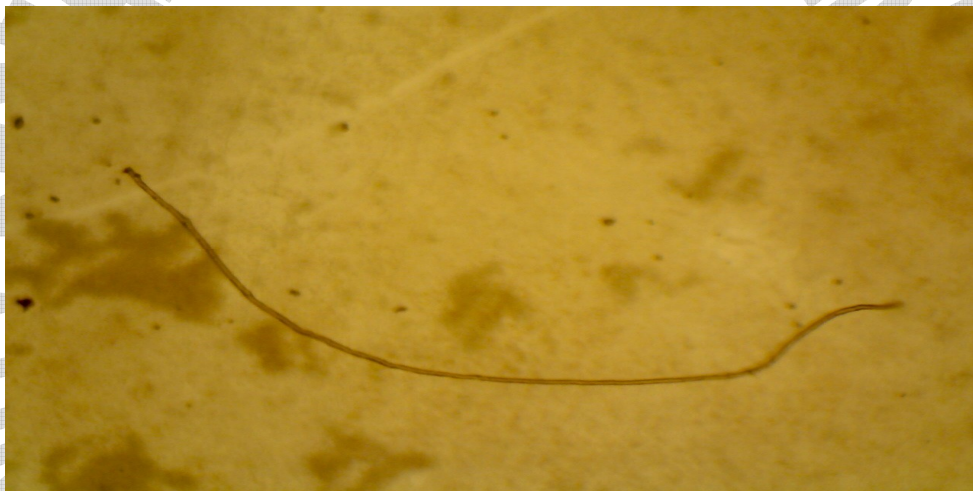

Plate 2: Wet mount micrograph showing anterior and posterior end of *W. bancrofti* in serum of patient (X 40 objective)

Concerning the drug treatment of lymphatic filariasis, diethylcarbamazine (DEC) is effective against both microfilaria and adult worms. DEC lowers the blood microfilaria levels significantly even in single annual doses of 6 mg/kg which is sustained (Emilio, 2008) and as effective as the same dose that was earlier recommended daily for 12 days by WHO (Ottesen et al., 1997). The transmission of this disease is prevented by the sustained destruction of microfilaria from a single annual dose of DEC (Emilio, 2008). The adverse effects produced by the drug are due to their rapid destruction of microfilaria which is characterized by fever, headache, myalgia, sore throat and cough lasting for up to 24-48 hours (Andrade et

al., 1995). These are usually mild and self-limiting requiring only symptomatic treatment. Ivermectin Lowers blood microfilaria like DEC for up to one year by a single dose of 200 to 400ug/kg (Chodakewitz, 1995; Cao et al., 1997).

The adverse effects in microfilaraemic patients are similar to those produced by DEC but are milder due to the slower clearance of parasitaemia. It is the drug of choice for the treatment of onchocerciasis because of its safety and efficacy, when compared to DEC. It is also the drug of choice for prevention of filariasis in African countries endemic for *Onchocerca* and *Loa loa*, where DEC cannot be used due to possible

severe adverse reactions (Emilio, 2008). Albendazole destroys the adult filarial worms when given in doses of 400 mg twice daily for two weeks. The death of the adult worm induces severe scrotal reactions in bancroftian filariasis since this is the common site where they are lodged (Jayakody et al., 1993).

Albendazole has no direct action against the microfilaria and does not immediately lower the microfilaria counts. But when given in single dose of 400 mg in combination with DEC or ivermectin, the destruction of microfilaria by these drugs becomes more pronounced. Albendazole combined with DEC or ivermectin is recommended in the global filariasis eradication programme. This not only will prevent transmission of filariasis in the community by reducing the microfilaria levels, but also will add the benefit of clearing the intestinal helminths (Shenoy et al., 2000).

CONCLUSION

Lymphatic filariasis is a major debilitating parasitic infection in the tropics. Although upper limb involvement is uncommon in our setting, this case report reveals the need to embark on an epidemiological survey in the affected community. Additionally, the use of a single dose combination of ivermectin and albendazole is efficacious in our setting.

ACKNOWLEDGEMENT

The authors are grateful to Dr Anthony Nwaopara of Department of Anatomy, College of Medicine, Ambrose Alli University, Ekpoma, Edo State, for his technical support in preparation of the micrograph. We are also grate to Gladis Akhigbe at Remitch health links laboratory for her immense assistance.

REFERENCES

- Andrade, L.A., Medeiros, Z. and Pires, M.L. (1995). Comparative efficacy of three different diethylcarbamazine regimens in lymphatic filariasis. *Trans. Royal Soc. Trop. Med. Hyg.*; 89: 319-21.
- Anitha, K. and Shenoy, R.K. (2001). Treatment of lymphatic filariasis: Current trends. *Indian J. Dermatol. Venereol. Leprol.*; 67:60-5.
- Cao, W.C., Van Der Ploeg, C.P.B., Plaisier, A.P., Sivera Van Der Sluijs, I.J. and Habbema, J.D.F. (1997) Ivermectin for chemotherapy of bancroftian

filariasis: a meta-analysis of the effect of single treatment. *Trop. Med. Inter. Health*; 2: 393-403.

Chodakewitz, J. (1995). Ivermectin and lymphatic filariasis: a clinical update. *Parasitol. Today*; 11: 233-235.

Dreyer, G., Noroes, J. and Addiss, D. (1997). The silent burden of sexual disability associated with lymphatic filariasis. *Acta Tropica.*; 63: 57-60.

Emilio, P. (2008) Filariasis: diagnosis, treatment and prevention. *Acta Biomed.*; 79: 106-109.

Freedman, D.O., de Almeida, F.P.J., Besh, S., Maiae Silva, M.C., Braga, C. and Maciel, A.I. (1994). Lymphoscintigraphic analysis of lymphatic abnormalities in symptomatic and asymptomatic human filariasis. *J. Inf. Dis.*; 170: 927-33.

Jayakody, R.L., De Silva, C.S.S. and Weerasinghe, W.M.T. (1993). Treatment of bancroftian filariasis with albendazole: evaluation of efficacy and adverse reaction. *Trop. Biomed.*; 10: 19- 24.18.

John, D.T. and Petri, W.A. (2006), Markell and Voge's Medical Parasitology (9th ed.), St. Louis: Saunders Elsevier.

Kaliwal, M.B., Kumar, A., Shanbhag, A.B., Dash, A.P. and Javali, S.B. (2010). Spatiotemporal variations in adult density, abdominal status & indoor resting pattern of *Culex quinquefasciatus* Say in Panaji, Goa, India. *Indian J. Med. Res.*; 131: 711-719.

Ottesen, E.A. and Ramachandran, C.P. (1995). Lymphatic filariasis infection and disease: control strategies. *Parasitol. Today*; 11: 129-131.

Ottesen, E.A., Duke, B.O.L., Karam, M. and Behbehani, K. (1997). Strategies and tools for the control/elimination of lymphatic filariasis. *Bulletin of the World Health Organization*; 75 (6): 491-503.

Pani, S.P., Kumaraswami, V. and Das, L.K. (2005). Epidemiology of lymphatic filariasis with special reference to urogenital-manifestations. *Indian J. Urol.*; 21:44-9.

Shenoy, R.K., Suma, T.K., Rajan, K. and Kumaraswami, V. (1998). Prevention of acute adenolymphangitis in brugian filariasis: comparison of the efficacy of ivermectin and diethylcarbamazine, each combined with local treatment of the affected limb. *Ann. Med. Parasitol.*; 92: 587-94.

Shenoy, R.K., Kumaraswami, V., Suma, T.K., Rajan, K. and Radhakuttyamma, G. (1999). A double blind placebo controlled study of the efficacy of oral penicillin, diethylcarbamazine or local treatment of the affected limb in preventing acute adenolymphangitis in lymphoedema caused by brugian filariasis. *Ann. Trop. Med. Parasitol.*; 93: 367-77.

Shenoy, R.K., John, A., Babu, B.S., Suma, T.K. and Kumaraswami, V. (2000). Two-year follow-up of the microfilaraemia of asymptomatic Brugian filariasis, after treatment with two, annual, single doses of ivermectin, diethylcarbamazine or albendazole in various combinations. *Ann. Trop. Med. Parasitol.*; 94: 607-14.

Suma, T.K., Shenoy, R.K., Varghese, J., Kuttikkal, V.V. and Kumaraswami, V. (1997). Estimation of ASO titer as an indicator of streptococcal infection precipitating acute adenolymphangitis in brugian lymphatic filariasis. *South East Asian J. Trop. Med. Pub. Health*; 28: 826-30.

Swaminathan, S., Perumal, V., Adinarayanan, S., Kaliannagounder, K., Rengachari, R. and Jambulingam, P. (2012). Epidemiological Assessment of Eight Rounds of Mass Drug Administration for Lymphatic Filariasis in India: Implications for Monitoring and Evaluation. *PLoS Negl. Trop. Dis.*; 6(11): e1926.

World Health Organization (2010). Global programme to eliminate lymphatic filariasis. Progress report 2000-2009

World Health Organization (1992). Lymphatic filariasis; the disease and its control. Fifth report of the WHO expert committee on filariasis. WHO Technical Report Series.; 821:1.

World Health Report (1995). Geneva, World Health Organization.

AUTHOR(S) CONTRIBUTION

Clinical diagnosis was made by Dr Emordi J.E. The case was reviewed by Dr Iribhogbe O.I. Case report was written by both authors.