



ASN-PH-020919
ISSN: 2315-5388

International Journal of Basic, Applied and Innovative Research
IJBAIR, 2012, 1(3): 73 - 77
www.antrescentpub.com

RESEARCH PAPER

MICROWAVE OVEN-INDUCED DECALCIFICATION AT VARYING TEMPERATURES: A COMPARATIVE STUDY OF TWO DECALCIFYING FLUIDS

¹Eloka C.C., ¹Bankole J.K., ²Okofo C.J., ¹Oguanya F.C., ³Odigie B.E.

Department of ¹Medical Laboratory Science, Ambrose Alli University, Ekpoma, Edo Nigeria, ²Medical Microbiology, University of Nigeria Teaching Hospital, Itoku Ozalla, Enugu-Nigeria. ³Medical Laboratory Science, School of Basic Medical Sciences, College of Basic Medicine Science, University of Benin, Benin City Nigeria.

Corresponding author: elokahidebere@yahoo.com

Received: 29th May, 2012

Accepted: 6th July, 2012

Published: 30th September, 2012

ABSTRACT

This study was designed to evaluate the effect of decalcifying fluid types on bone tissue architecture and its staining properties following decalcification at varying temperatures. A decalcification methodology using Golding and Stewards (GS) fluid, and Jenkings fluid (JK), and a modern household microwave oven to accelerate the decalcification rate of bone tissue samples, was adopted for microscopic investigations at room temperature, 30^oC, 40^oC, and 50^oC respectively. Bone biopsy was obtained from a rabbit's limb and fixed immediately for 24hrs in 10% formalin. The result showed that micrographs from bone tissue sections decalcified with 5% GS presented excellent histological architecture when compared with those decalcified with 5% JK at 30^oC while 5% JK presented good histological architecture when compared with those decalcified with 5% GS at 40^oC. Severe cyto-architectural distortion was observed for bone tissues decalcified with 5% GS at 50^oC, while bone tissues decalcified with 5% JK at 50^oC, presented cyto-architectural distortions that were however, not as severe as those of 5% GS at 50^oC. Our findings suggest therefore, that decalcification with 5% GS at 30^oC, comparatively gives optimal histological results and preserves the tissues' best staining properties.

Key words: *microwave oven, temperatures, bone decalcification, Histology,*

INTRODUCTION

The choice of decalcifying agents used in histology for decalcification of tissue has been a difficult issue to deal with as some agents remove the calcium ions completely and rapidly causing adverse effects on the tissues' staining characteristics and histological architecture (Sanjai *et al.*, 2012). However, the effects of decalcifying agents on tissue architectures, its staining characteristics and decalcification rate, had remained important parameters influencing the choice of decalcifying solutions.

Meanwhile, bone and bone-containing specimens are inherently difficult tissues to work with as traditional decalcifications requires long periods of time leading to hydrolysis of bone matrix (Janneke *et al.*, 1999; Pitol *et al.*, 2007 and Lillie *et al.*, 1951). This time lag is detrimental to bone tissue morphology and delay in diagnostic results in clinical settings (Madden and Hansem, 1997 and Carlton, 1979). Sequel to this development, several attempts have been made to select the best decalcifying fluid and induce the decalcification process to produce minimum

effects on the morphology of the tissues after decalcification. One of the attempt to remedy this situation was the use of temperature variations as literature has it that increase in temperature accelerates many chemical reactions including decalcification. But greater temperature elevation (50-60°C) has been observed to be deleterious to tissue morphology (Wegana *et al.*, 1993; Pitol *et al.*, 2007 and Carlton, 1979).It is this temperature concerns that led to the laboratory use of microwave oven which can be manipulated to produce different ranges of temperatures in order to accelerate decalcification rate but with minimum effects on tissue morphology after the decalcification(Mayer's, 1970; Mar and Wong, 2009; Guntz and English, 2011 and Pitol *et al.*, 2007). So far, microwave has been used in histology laboratories for fixation, decalcification and tissue processing (Mar and Wong, 2009).

This study therefore, was designed to evaluate the effect of decalcifying fluid types on bone tissue architecture and its staining properties following decalcification at varying temperatures with Golding and Stewards (GS) fluid and Jenkins fluid (JK).

MATERIALS AND METHODS

Location of Study: This study was conducted in the Histopathology Laboratory of the Department of Medical Laboratory Science, Ambrose Alli University, Ekpoma, Edo State, Nigeria, and the University of Benin Teaching Hospital (UBTH), Benin-City, Edo, State Nigeria.

Bone Samples: 6 pieces bone tissues obtained from a rabbit's limb, were used for this study and were subdivided into two groups (A and B) of 3 pieces each for decalcification with 5% GS and 5% JK at varying temperatures.

Research Design: The bone tissues were fixed for 24 hours in 10% formalin after cutting them into smaller sizes. It was then rinsed in distilled water and transferred into 70% alcohol before decalcification. Decalcification was performed using 5% GS and 5% JK at different temperatures (Room temperature, 30°C, 40°C, and 50°C) with the aid of a modern household microwave oven.

Room Temperature Decalcification Procedure: Bone tissues were suspended in a universal container containing 5% JK and 5% GS. The decalcifying fluids were changed once daily until decalcification was completed. The bone tissues were rinsed in distilled water and transferred to 70% alcohol before suspending in fresh decalcifying fluid. The chemical method of testing for end point of decalcification was carried out daily to evaluate the progress of decalcification until decalcification is completed. After decalcification was completed, the bone tissues were rinsed in distilled water and transferred to 70% alcohol.

Microwave Decalcification Procedure: The microwave oven was operated at different power and time. The power ranges from p10-p100 and thermometer was used to determine the temperature at each power (p). At power p10, p20, p30, the temperatures were determined to be 30°C, 40°C and 50°C respectively.

RESULTS

Group A: Microwave oven decalcification using 5% Gooding and Stewart fluid (GS) at 30°C, 40°C and 50°C respectively as shown in plate 1-3. Micrographs from bone tissue sections decalcified with 5% GS at 30°C, showed very good staining qualities and presented distinct histological features that were comparably the best (Plate 1), while bone tissues decalcified with 5% GS at 40°C showed poor staining qualities but presented normal histological features that were also distinct (Plate 2). However, bone tissues decalcified with 5% GS at 50°C presented severe cyto-architectural tissue distortions (Plate 3).

Group B: Microwave oven decalcification using 5% Jenkins' fluid (JK) at 30°C, 40°C and 50°C respectively as shown in plate 4-6. Micrographs from bone tissue sections decalcified with 5% JK at 30°C (Plate 4) and 5% JK at 40°C (Plate 5) showed good staining qualities and presented distinct histological features, However, bone tissues decalcified with 5% JK at 50°C presented mild cyto-architectural tissue distortions (Plate 6). Generally, the observed histological variations were temperature and decalcifying fluid-type dependent.

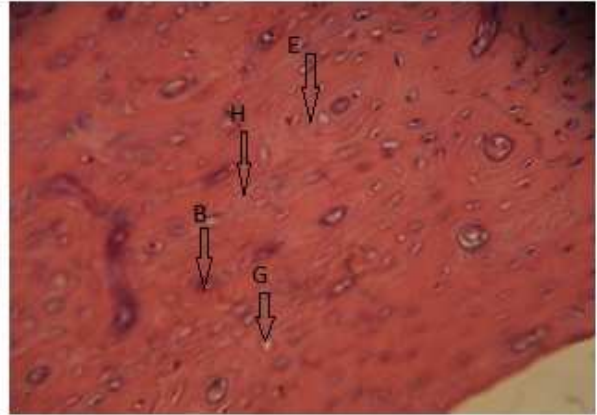
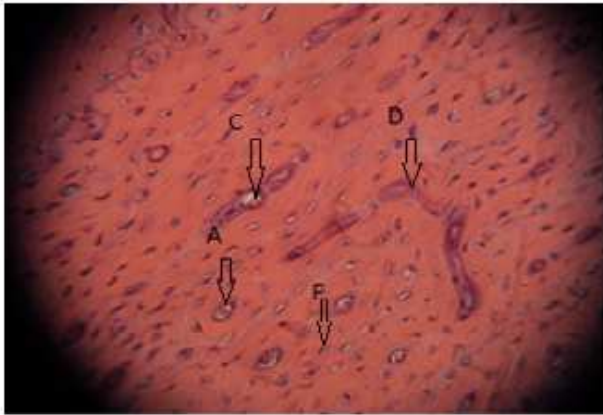
Plate 1: Compact Bone Section (5% GS at 300C; H&E x400) presents the best histological features that are distinct with very good staining quality showing matured osteon with haversian canal, osteocyte and blood vessels (A) as well as Young osteon (B), resolving osteon (C), Volkman's canal (D), osteon lamella (E), lacunae containing osteocyte and empty space occupied with extracellular fluids (F), empty lacunae (G) and cement lines (H). Each of the features are indicated with arrow

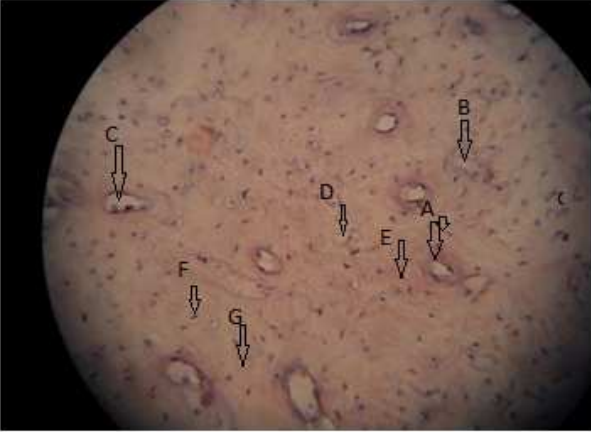

Plate 2: Compact Bone Section (5% GS at 400C; H&E x400) presents normal histological features that distinct with poor staining quality.

Plate 3: Compact Bone Section (5% GS at 500C; H&E x400) presents total destruction of the tissue architecture.

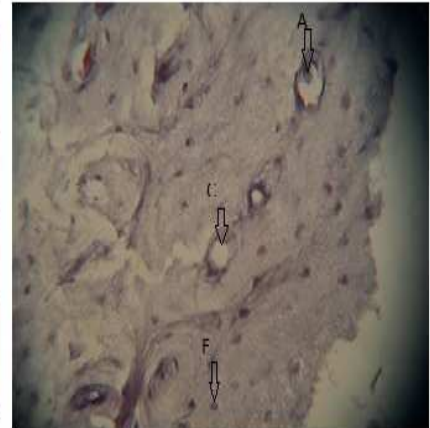
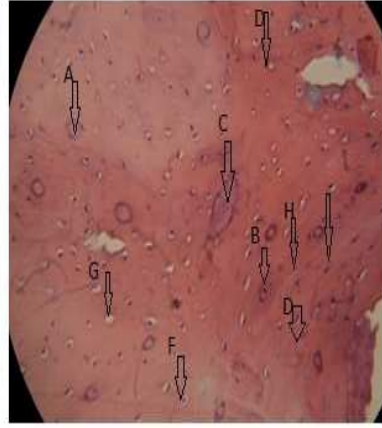
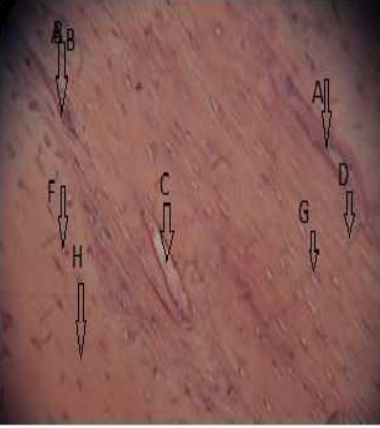
Plate 4: Compact Bone Section (5% JK at 300C; H&E x400) presents normal histological features that are distinct with good staining quality.

Plate 5: Compact Bone Section (5% JK at 400C; H&E x400) presents normal histological features that are distinct with good staining quality.

Plate 6: Compact Bone Section (5% JK at 500C; H&E x400) presents destruction of the tissue architecture with some features seen.

DISCUSSION

This result of this study for 5% JK and 5% GS at 30°C, and 5% GS and 5% JK at 40°C, is in line with the report of Guntz and English, (2011) who conducted microwave bone decalcification with formic acid at 40°C and reported no adverse effects on tissue architecture. Similar findings were also reported by Pitol et al. (2007) and Mar and Wong (2009) who conducted microwave bone decalcification at 37°C (which is within the range of 40°C) and reported no adverse effect on the tissue histology and staining characteristics.

Meanwhile the report by Jamur *et al.*, (1993) supports the fact that temperature increases up to 60°C accelerated EDTA decalcification without the risk of maceration unlike the observation this study for decalcification with 5% JK and 5% GS at 50°C, suggesting that temperature effects on tissues during decalcification, varies with the type of decalcifying fluid.

Similarly, the assertion by Jamur *et al.*, (1993), might explain the comparative difference in the histological observations for 5% JK and 5% GS at 30°C and 40°C as bone tissue decalcification with 5% GS at 30°C presented the best histological architecture than 5% JK at 30°C, while 5% JK at 40°C presented the best histological architecture than 5% GS at 40°C.

Our findings suggest therefore, that decalcification with 5% GS at 30°C, comparatively gives optimal histological results and preserves the tissues' best staining potentials.

ACKNOWLEDGEMENT

We acknowledge the assistance provided by the research students of the Department of Medical Laboratory Sciences, Ambrose Alli University, Ekpoma, Edo-Nigeria.

REFERENCES

- Carlton, H. (1979). Bone and decalcification: Carlton's Histological Techniques, 5th ed. Messrs Churchill Livingstone, London. Pp. 199-207.
- Guntz, L. S. and English, H. (2011). Expedited bone throughput using microwave decalcification. *Technical Bulletin for Histology*.44:1.
- Jamur, M. C., Faraco, C. D., Lunardi, L. O., Siraganian, R. P. and Oliver, C. (1995). Microwave fixation improves antigenicity of glutaraldehyde sensitive antigens while preserving ultra-structural detail. *J. Histochem. Cytochem.*43:307-311.
- Jenneke, C. A., Pieter-Jeap, K., Kees, J. V. and Herman, V. D. (1999). Effect on bone decalcification procedures on DNA in situ hybridization and comparative genomic hybridization. *Journal of Histochemistry Cytochemistry*. 47(5):703-709.
- Lillie R. D., Askey, A., Greco, J., Jacquier. B. H. and Jones, P. (1951). Decalcification of bone in relation to staining and phosphatases technics. *Am. J. Clin.Pathol.* 21:711-722.
- Madden, V. J and Henson, M.M. (1997). Rapid decalcification of temporal bones with preservation of ultra-structure. *Hearing Res.* 111:76-84.
- Marr, A. L. and wong, A. (2009). Effects of microwave fixation to decalcification on rodent tissue. *Journal of Histotechnology*. 32(4):191.
- Mayers, C. P. (1970). Histological fixation by microwave heating. *J. Clin.Pathol.*23:273-275.
- Pitol, D. L., Caetano, F. H. and Lunard, I.O. (2007). Microwave-induced fast decalcification of rat bone for electron microscopic analysis: An ultra-structural cytochemical study. *Dent. J.* 18(2):153-157.
- Sanjai, K; Kumarswamy, J; Patil,A; Papaiah, L; Jayaram, S and Krishnan, L. (2012). Evaluation and comparison of decalcification agents on the human teeth. *J.Oral Maxillaofac Pathol.* 16(2):222-227.

Wagenaar, F., Kok, G. L., Broekhijzen-Davies, J. M. And Pol, J. M. A. (1993). Rapid cold fixation of tissue by microwave irradiation goes it uses in electron microscopy. *Histochem. J.* 25:719-725.

AUTHOR(S) CONTRIBUTION

All authors (Eloka C.C., Bankole J.K., Okoro C.J., Oguanya F.C. and Odigie B.E.) actively took part in the tissue monitoring and presentation of this article.