



ASN-PH-020919  
ISSN: 2315-5388

## International Journal of Basic, Applied and Innovative Research

IJB AIR, 2012, 1(2): 68 - 72

[www.antrescentpub.com](http://www.antrescentpub.com)

### RESEARCH PAPER

#### THE EFFECTS OF GROUNDNUT, SPICES, MONOSODIUM GLUTAMATE AND SALT COMBINATIONS ON THE BRAIN

\*<sup>1</sup>Okpalaugo, O.C., <sup>1</sup>Eigbe, T. O., <sup>1</sup>Ekakitie, O.O.

Department of <sup>1</sup>Physiology, University of Benin, Benin City, Edo State, Nigeria.

Correspondence to: [cynmaruwa@yahoo.com](mailto:cynmaruwa@yahoo.com)

Received: 11<sup>th</sup> May, 2012

Accepted: 29<sup>th</sup> June, 2012

Published: 30<sup>th</sup> June, 2012

#### ABSTRACT

This study was intended to determine the effect of salt, groundnut, monosodium glutamate and spices, especially in combinations as used in *Yaji*, on the histology of the brain. The rats were divided into nine (9) groups (A – I) of eight rats (8) each. Groups A, B, C, D, E, F, G, H, constituted the test groups whereas group I served as the control group. The rats were allowed to acclimatize for three weeks and weighed before being fed for 8 weeks with feed pellets made by mixing the test substances as follows: Group A received 3g each of the substances under study + feed; Group B received 3g of salt + feed; Group C received 3g of clove + feed; Group D received 3g of monosodium glutamate + feed; Group E received 3g of ginger + feed; Group F received 3g of red pepper + feed; Group G received 3g of black pepper + feed; Group H received 3g of groundnut + feed. The histological findings show that excessive consumption of these substances especially in combination have deleterious effects on the brain. Hence, a regulated consumption pattern is advocated.

**Keywords:** spices, brain, histology, *Yaji*.

#### INTRODUCTION

Over the years, plants and spices have been used traditionally as coloring agents, flavoring agents, preservatives and food additives (Lee et al., 2004). Recently, the use of spices has increased greatly all over the world due to their anti-parasitic (Choi et al., 2012), anti-helminthic (Majeed, 2011), antibacterial (Rahman et al., 2011), anti-microbial (Nwaopara et al, 2009), anti-oxidant (Okpalaugo, 2012), analgesic (Gill et al., 2010), sedative (Iyer et al., 2009), anti-diabetic (Srinivasan, 2005) and anti-obesity (Akpamu et al., 2011) potentials.

Of a concern however, is *Yaji* – a complex meat sauce used to serve the meat delicacy called *suya*. It contains ginger, clove, red pepper, black pepper, salt, monosodium glutamate and groundnut is known to be a complex combination without a standardized format (Nwaopara et al, 2007).

Literatures indicate that the active ingredients in *Yaji*, on individual basis, are known to be harmful (Nwaopara et al, 2004). Hence, excessive consumption implies excessive consumption of the spices and additives. Interestingly, several studies have been done on the effect of *Yaji* and *Yaji*-components on different body organs (Nwaopara et al., 2004; 2007a, b; 2008a, b; 2009; 2010a, b).

Considering the existing findings from several studies on *Yaji* and *Yaji*-components and the aforementioned active components of *Yaji*, this study is therefore designed to investigate the effects of *Yaji* components especially in combination, on the histology of the brain in adult rabbits.

## MATERIALS AND METHODS

**Experimental animal:** Adult rats bought from the animal house of the College of Medicine, Ambrose Alli University, Ekpoma Edo State, Nigeria, and moved to the site of the experiment at No. 5B Palmwell Street Ujemen, Ekpoma Edo State, Nigeria were used for this study. They were allowed to acclimatize for three (3) weeks during which period they receive feed (Growers mesh; Bendel Feeds and Flour Mills (BFFM) Ewu, Edo State, Nigeria) and water *ad libitum*.

The animals were weighed on the first day of the acclimatization period and then sub-divided into nine (9) groups (A – I) of eight (8) rats each. The groups A, B, C, D, E, F, G, and H, constituted the test groups whereas group I served as the control.

**Substance of Study:** The feeds for this experiment were weighed using a Goat Scale weighing balance (China; calibrated 20kg x 100g). The powdered spices and additives were measured using an Electric Balance (Denver Company USA; 200398. 1REV.C XP-3000).

Pellets were made by mixing 3g of each of the components of Yaji to feed as required with sprinkles of water. The paste formed was then split into bits and allowed to dry under the sun.

**Administration:** The animals received as follows; Group A received 3g of each of the components of Yaji respectively plus feed. Group B received 3g of Salt + Feed; Group C received 3g of clove + Feed; Group D received 3g of Monosodium Glutamate +Feed; Group E received 3g of Ginger + Feed; Group F received 3g of Red peer + Feed; Group G received 3g of Black peer + Feed and Group H received 3g of Groundnut + Feed.

**Duration of study:** The duration of feeding with experimental substance lasted for eight (8) weeks. However, the study lasted for a period of four months.

**Sample Collection:** At the end of the study, the brain was harvested via dissection and kept fixed in containers containing formaldehyde.

**Histological Processing:** Cut sections of the rat brain was processed for histological study via routine histochemical method of fixation, dehydration, clearing, impregnation, embedding, sectioning and staining as described by Jiang et al. (2005).

## RESULTS

Histological observations showed normal histological architecture of the brain in group I (control). Similar presentations were observed in group C, E and F. However, tissue micrographs from group A presented moderate vacuolar degeneration of neurons and some red neuron degeneration (figure 1).

Tissue micrographs from group B showed moderate vacuolar degeneration of neurons consistent with cellular oedema and some red neuron degeneration (figure 2).

Those from group D showed severe vacuolar degeneration of neurons and some red neuron degeneration suggestive of ischemic injury (figure 3), while those from group G and H showed mild red neuron degeneration and mild vacuolar degeneration of neurons respectively (figure 4).

## DISCUSSION

The result of this study further confirms the fact that excessive consumption of salt, monosodium glutamate and groundnut, especially in combinations, can result in neuronal degeneration. Although the mechanisms involved were not experimentally determined, there exists however, reports that it could be an apoptotic or a necrotic cell death. These two types differ morphologically and biochemically (Wyllie, 1980).

Pathological or accidental cell death is regarded as necrotic and could result from extrinsic insults to the cell such as osmotic, thermal, toxic and traumatic effects (Farber et al., 1981), while apoptotic cell death can be triggered by neurotoxins (Waters et al., 1994). Cell death in response to neurotoxins occurs as a controlled event involving a genetic programme in which caspase enzymes are activated (Waters et al., 1994).

On the other hand, the vacuolations observed in this study might have been induced by excessive salt, black pepper and MSG ingestion. Available evidence showed that MSG administration can lead to excite-toxic neuronal degeneration of the cerebellum in chicks (Espinara et al., 2000). It has also been reported that MSG produces neuronal degeneration in several brain regions when administered in neonatal rats (Urena-Guerrero et al., 2003).

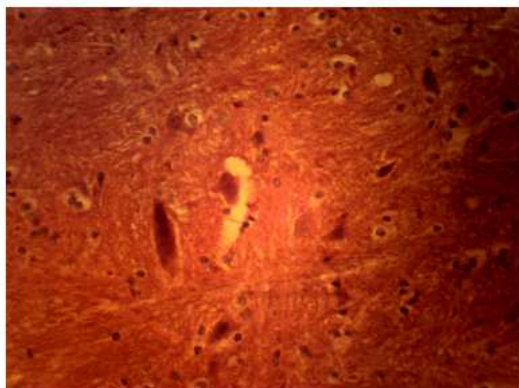


Figure 1: Brain Section (H & E X400) showing normal histological architecture of the brain

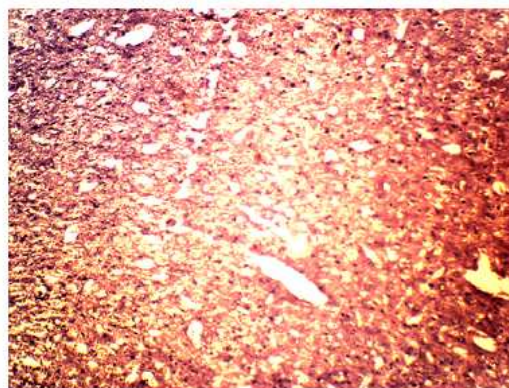


Figure 2: Brain Section (H & E X400) showing moderate vacuolar degeneration of neurons consistent with cellular oedema and some red neuron degeneration

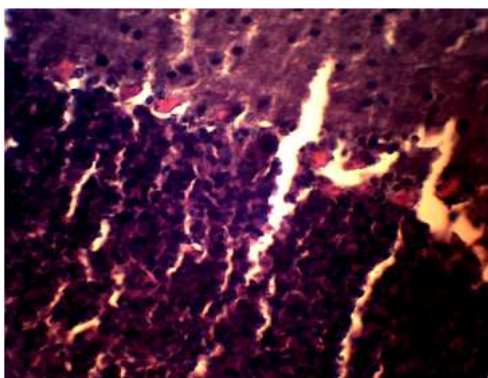


Figure 3: Brain Section (H & E X400) showing moderate vacuolar degeneration of neurons consistent with cellular oedema and some red neuron degeneration

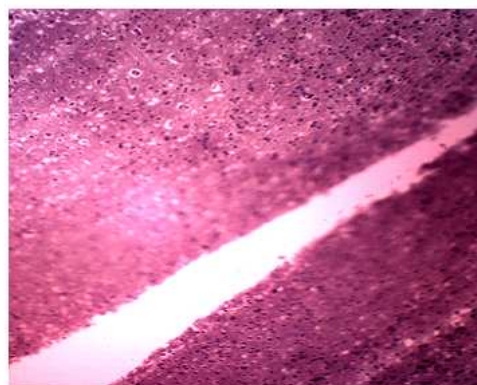


Figure 4: Brain Section (H & E X400) showing mild red neuron degeneration and mild vacuolar degeneration of neurons

Scientist has also shown that ischaemic or pharmacologic disruption of cellular transporters can be associated with parenchyma swelling (glial, endothelia and neurons) of the medial geniculate body and this could be induced by drug poisoning, water intoxication, hypoxia from asphyxia and acute hyponatremia (Johnson, 1995). In fact, severe cytotoxic oedema of the brain can lead to marked reduction in the size of the ventricular system and basal cisterns (Johnson, 1995).

Furthermore, the observed pyknotic neurons is in line with the work reported by Adjene and Caxton Martins (2006) as Eweka and Om'Iniabohs (2007) acknowledges that such a result implies an adverse effect on the functions of the brain. Also, the reduction in the activity of several enzymes has been reported as one of the consequences of oxidized oil ingestion (Odotuga *et al*, 1997; 1999; Odotuga and Ologan, 1999). Jimoh and Odotuga (2002) investigated histological changes in the lungs and heart of rats fed oxidized groundnut oil. The changes observed in group H would probably be due to oxidized oil ingestion. Even Kieckebuf *et al* (1962) had reported an exaggerated response of the central nervous system to stimuli as well as spontaneous movement as arising from the ingestion of oxidized oil.

From the forgoing therefore, our results further suggest, that the excessive consumption of groundnut, spices, salt and MSG, especially in combinations, could affect the histology of the Brain. Moreover, MSG and some of the spices have been proven to be excite-toxic while groundnut can easily be contaminated with aflatoxin. Hence, a regulated consumption pattern is advocated.

## ACKNOWLEDGEMENT

We express our profound gratitude to Dr. Nwaopara A.O. for his assistance. We also commend the efforts of Oare Amina, Erua Constance, Omigie Mary, Omos, Ohis, Ovbiagele Evelyn and Ebosele Angela, who worked with us to ensure the completion of this project.

## REFERENCES

- Adjene J.O. and Caxton-Martins A.E. (2006). Some histological effect of chronic administration of Chloroquine on the medial geniculate body of adult Wistar rat. *Afri. J. Med. Sci.* 35: 131-135.
- Akpamu U., Nwaopara A.O., Izunya A.M., Oaikhen G.A., Okhia O., Idonije B.O. and Osifo U.C. (2011). A comparative study on weight changes in rats fed with diet containing *Yaji*, *Yaji-additives* and *Yaji-spices*. *Biology and Medicine*; 3 (5): 6 - 15.
- Choi W., Jiang M. and Chu J. (2012). Antiparasitic effects of *Zingiberofficinale*(Ginger) extract against *Toxoplasma gondi*. *J Appl Biomed*; 10: (in press)
- Espinar A., García-Oliva A., Isorna E.M., Quesada A., Prada F.A. and Guerrero J.M. (2000). Neuroprotection by melatonin from glutamate-induced exocitotoxicity during development of the cerebellum in the chick embryo. *J. Pineal Res*; 2: 81 - 88.
- Eweka A.O. and Om'Iniabohs F.A.E. (2007). Histological Studies Of The Effects Of Monosodium Glutamate On The Cerebellum Of Adult Wistar Rats. *The Internet Journal of Neurology*; 8:2.
- Farber J.L., Chein K.R. and Mitnacht S. (1981). The pathogenesis of irreversible cell injury in ischemia. *American Journal of Pathology*; 102: 271-281.
- Gill N.S., Bansal, R.K., Garg, M., Sood, S., Muthuraman, A. and Bali M. (2010). Evaluation of antioxidant, anti-inflammatory and analgesic potential of *Citrulluslanatus* seed extract in rodent model. *Internet J. Nutri. Wellness*;9:2
- Iyer A., Panchal S., Poudyal H. and Brown L. (2009). Potential health benefits of Indian spices in the symptoms of the metabolic syndrome. *Indian Journal of Biochemistry and Biophysics*; 46: 467 – 48.
- Jiang X., Kalajzic Z., Maye P., Braut A., Bellizzi J. et al. (2005). Histological Analysis of GFP Expression in Murine Bone. *Journal of Histochemistry and Cytochemistry*; 53:59.
- Jimoh F.O. and Odutuga A.A. (2002). Histological changes in the lungs and heart due to dietary oxidized groundnut oil. *Nigerian Journal of Biochemistry and Molecular Biology*; 17: 1-6.
- Johnson C.E. (1995). Effects of fluid imbalances: Neuroscience in Medicine: P. Michael Conn JB Lippincott Company. pp. 187-189.
- Kieckebfu W., Jahr K., Czok G., Griem W., Bassler K., et al. (1962). Physiologische Wirkungen Autozydierter Ole KlinWach 40: 1076
- Lee K.W., Everts H. and Beynen A.C. (2004). Essential oils in broiler nutrition. *Int. J. Poult. Sci.* 3:738–752.
- Majeed A.S. (2011). Antihelmintic activity of *salvadorapersicar*root extract against *pheretimaposthuma*. *International Journal of Pharmaceutical Sciences and Research* 2(9):2343-2346.
- Nwaopara A.O., Anyanwu L.C., Oyinbo C.A. and Anaikot I.C. (2004). The histological changes in pancreas of Wister rats fed with diets containing *Yaji* (Local meat Sauce). *J. Experimental and Clinical Anatomy*; 3(2): 44 – 47.
- Nwaopara A.O., Odike M.A.C., Inegbenebor U. and Adoye M.I. (2007a). The Combined effects of excessive consumption of ginger, clove, red pepper and black pepper on the histology of the liver. *Pakistan Journal of Nutrition*; 6(6): 524-527.



Nwaopara A.O., Odike M.A.C., Ikhuorah T.A. and Anyanwu L.C. (2007b). Potential Health Hazards in Yaji: The Complex Suya Meat Sauce. *Medilink Journal*; 8(74): 34-38.

Nwaopara A.O., Odike M.A.C., Inegbenebor U., Nwaopara S.O. and Ekhoje E.I. (2008a). A comparative study on the effects of excessive consumption of ginger, clove, red pepper and black pepper on the histology of the Heart. *Electronic Journal of Biomedicine*; 3: 61-64.

Nwaopara A.O., Odike M.A.C., Inegbenebor U., Nwaopara S.O. and Ewere G.I. (2008b). A comparative study on the effects of excessive consumption of ginger, clove, red pepper and black pepper on the histology of the Kidney. *Pakistan Journal of Nutrition*; 7(2): 287 – 291.

Nwaopara A.O., Anibeze C., Akpuaka F. and Nwaopara S.O. (2009a). Antimicrobial potentials of Yaji-Spices: The constituents of a complex Nigerian suya meat sauce inducing histological investigations. *The Internet Journal of Alternative Medicine*. 6 (2).

Nwaopara A.O., Anibeze C.I.P. and Akpuaka F.C. (2009b). Histological signs of oligodendroglioma in the brain of rats fed with diet containing Yaji: The complex Nigerian suya meat sauce. *J. Clin. Review & Opinions*;1(2):021-025.

Nwaopara A.O., Anibeze C.I.P. and Akpuaka F.C. (2010a). Histological signs of neurodegeneration in the cerebrum of rats fed with diet containing Yaji: The complex Nigerian suya meat sauce. *Asian J. Med. Sci.* 2(1):16 - 21.

Nwaopara A.O., Anibeze C.I.P. and Akpuaka, F.C. (2010b). Induced histological features of hypoxia-ischaemia in the brain of rats fed with diet containing Yaji: The complex Nigerian meat sauce. *Research Journal of Applied Sciences, Engineering and Technology*; 2(1): 67 – 72.

Odutuga A.A. and Ologan F.O. (1999). Effect of thermally oxidized soyabean oil on alkaline and acid phosphates in rat liver and serum. *Biosci..Res .Commun.*11:281 –285.

Odutuga A.A., Obaleye J.A. and Ologan F.O. (1997). Hermodied Soybean oil: Spectroscopic investigation and effects on selected rat tissues. *Biokemistri* 1: 45 58.

Okpalaugo O.C. (2012). Antioxidant potential of Yaji spices. *International Journal of Herb and Pharmacological Research*; 1 (2):

Rahman S., Parvez A.K., Islam R. and Khan M.H. (2011). Antibacterial activity of natural spices on multiple drug *Escherichia coli* isolated from drinking water, Bangladesh resistant. *Annals of Clin. Microb. Antimicrobials*; 10:10

Srinivasan K. (2005): Plant foods in the management of diabetes mellitus: spices as beneficial antidiabetic food adjuncts. *Int. J. Food Sci. Nutr.* 56(6):399-414.

Urena-Guerrero M.E., Lopez-Perez S.J. and Beas Zaratel B. (2003). Neonatal Monosodium glutamate treatment modified glutamic acid decarboxylase activity during rat brain postnatal development. *Neurochem. Int*; 42(4): 269-276.

Waters C.M., Wakinshaw G., Moser B. and Mitchell I.J. (1994). Death of neurons in the neonatal rodent globus pallidus occurs as a mechanism of apoptosis. *Neuroscience* 63: 881-894.

Wyllie A.H. (1980). Glucocorticoid-induced thymocyte apoptosis is Associated and endogenous endonuclease activation. *Nature* 284:555-556.

#### **Author(s) contribution**

Okpalaugo, O.C. and Eigbe, T.O. performed this study with assistace from Ekakitie, O.O. All authors were involved in the preparation and final correction of this article.