



## Thoracic Endometriosis Syndrome: a case series and review of literature

Ogbudu SO<sup>1,2</sup>, Echieh CP<sup>1,2</sup>, Nwagboso CI<sup>1</sup>, Eze JN<sup>1</sup>, Edet EE<sup>3</sup>, Okpe AE<sup>3</sup>, Etiuma AU<sup>1,2</sup>, Bassey OO<sup>1</sup>, Ekanem AI<sup>3</sup>

<sup>1</sup>Division of Cardiothoracic Surgery, Department of Surgery, University of Calabar Teaching Hospital, Calabar, Nigeria.

<sup>2</sup>Department of Surgery, University of Calabar, Calabar Cross River State, Nigeria.

<sup>3</sup>Department of Obstetrics and Gynaecology, University of Calabar Teaching Hospital, Calabar, Nigeria.

### Abstract

**Background:** The presence of endometrial tissue in the tracheobronchial tree, pleural, and lung is normally referred to as thoracic endometriosis. The association of catamenial pneumothorax, catamenial haemothorax, catamenial haemoptysis and pulmonary nodules is referred to as thoracic endometriosis syndrome (TES). TES is rare but not as rare as it has always been thought of.

### Case summaries:

**Case 1:** We present EA, a 26-year-old chef/baker who presented to our unit on account of recurrent cyclical right sided chest pain and difficulty in breathing, recurrent haemoptysis and cyclical abdominal pain and swelling with multiple tender umbilical nodules. On general physical examination she was found to be in respiratory distress but not cyanosed with peripheral arterial oxygen saturation 97% on room air. Examination of the chest revealed a right sided chest fullness and reduced movement with breathing. Percussion note was stony dull and absent of breath sound on right hemithorax. Abdominal examination revealed a moderately distended abdomen with positive fluid thrill. Both Pleurocentesis (thoracocentesis) and paracentesis abdominis yielded a haemorrhagic fluid acellular and pleural and lung biopsy demonstrated endometrial stroma and glands. Imaging examination by way of chest X-ray showed a homogenous opacity of the right hemithorax, and pulmonary nodule following drainage. A diagnosis of Thoracic Endometriosis Syndrome was made. She had VAT with lung and pleural biopsy, pleural abrasion and a thoracostomy tube drainage.

**Case 2:** We present IAE, a 29-year-old Po+0 who presented to our unit on account of recurrent cyclical right sided chest pain and difficulty in breathing, unproductive cough. On general physical examination she was found to be in moderate respiratory distress but not cyanosed with peripheral arterial oxygen saturation of 98% on room air. Chest examination revealed an apical fluttering of anterior chest wall with left trachea deviation. Percussion note was stony dull on the right lower third and hyper resonance middle and upper zones of right hemithorax. Pleurocentesis (thoracocentesis) yielded air and haemorrhagic fluid acellular and pleural and lung biopsies demonstrated endometrial stroma and glands. Imaging examination by way of chest X-ray and chest CT-scan showed air fluid level of the right hemithorax. A diagnosis of TES was made. She had Laparoscopy and VAT at the same sitting with pleural and lung

### Corresponding Author:

**Dr Stephen Omirigbe Ogbudu,**

Department of Surgery, College of Medical Sciences, University of Calabar, Calabar, Nigeria/Division of Cardiothoracic Surgery, Department of Surgery, University of Calabar Teaching Hospital, Calabar, Cross River State, PMB 1276, Calabar 54271, Nigeria.

[ogbudustepheno@unical.edu.ng](mailto:ogbudustepheno@unical.edu.ng) | +2348037244560

DOI: 10.61386/imj.v17i1.399

biopsies. She was managed medically after closed thoracostomy tube drainage. She had partial collapse of right lower lobe and thoracotomy with right lower lobectomy was planned but patient declined. She also had Stage IV endometriosis by (rASRM)/ENZIAN systems

**Case 3:** We present JA a 29-year-old lady, a filling station attendant who presented to our unit with a

history of gradual onset of right sided chest pain, progressive difficulty in breathing and non-productive cough, and abdominal pain and swelling. On general physical examination she was found to be in respiratory distress but not cyanosed with SPO<sub>2</sub> of 98% on room air. Examination of the chest revealed a right apical flattening, reduced ipsilateral chest movement with breathing. Percussion notes were stony dull and absent air entry on the ipsilateral hemithorax. Abdominal examination showed a mildly distended abdomen with a positive shifting dullness. Both Pleurocentesis (thoracocentesis) and paracentesis abdominis yielded a haemorrhagic fluid acellular at cytology and pleural and lung biopsy demonstrated endometrial stroma and gland. Imaging examination by way of chest X-ray showed a homogenous opacity of the right hemithorax. A diagnosis of Familial Thoracic Endometriosis Syndrome (FTES). Had USS guided lung and pleural biopsy and a thoracostomy tube drainage. She had chemical pleurodesis with tetracycline

**Conclusion:** Thoracic endometriosis syndrome is the diagnosis in a lady of reproductive age who present with cyclic or a cyclical recurrent right sided chest pain, cyclical or a cyclical dyspnoea, haemoptysis, cyclical or a cyclical abdominal swelling and peritonitis.

### Introduction

The presence of functional endometrial tissue in the tracheobronchial tree, pleura and lung is referred to as thoracic endometriosis (TE) or extra genital endometriosis.<sup>1,2</sup> The most common extragenital site of endometriosis is within the thoracic cavity.<sup>3</sup> The association of catamenial pneumothorax, catamenial haemothorax, catamenial haemoptysis and catamenial pulmonary nodules is referred to as thoracic endometriosis syndrome (TES).<sup>4</sup> Thoracic endometriosis was described as early as 1912 by Di Palo S et al were the first to describe endometriosis as causing pulmonary lesions consisting of endometrial glands and stroma. Endometriosis is a disease in women of child bearing age or mid 30s,<sup>5</sup> however, endometriosis has been reported in men and postmenopausal women on prolonged estrogen.<sup>6</sup> While the peak incidence of TES has been reported to occurs between 30-35years, which is a decade later than the genital endometriosis,<sup>7</sup> our patients are 26, 29 and 29years. First and the last are

biological siblings. other symptoms like recurrent cyclical chest pain and recurrent cyclical difficulty in breathing are not uncommon,<sup>9</sup> Several theories have been proposed to explain these mechanisms of TES including Sampson's theory of retrograde menstruation, Meyer's coelomic metaplasia theory, Halban's lymphovascular microembolization theory and the prostaglandin F<sub>2</sub> bronchoconstriction theory, yet not one of these theories have adequately explain all the phenomenon observed in this entity.<sup>10,11</sup>

The prevalence of TES in Nigeria is not known, although genital endometriosis is quite common among Nigerian women evaluated for gynaecological symptoms.<sup>12</sup> There are few reported cases of TES in Nigeria often characterized by instance of delayed diagnosis, inappropriate and incomplete treatment.<sup>13</sup> CP has been reported to be the commonest clinical presentation of TES, there is difference in the clinical presentation of TES in some studies

**Case report 1:** A 26-year-old chef/baker who presented to us via Accident and Emergency with a history of recurrent cyclical right sided chest pain, recurrent cyclical difficulty in breathing, recurrent cyclical generalized abdominal pain and recurrent cyclical abdominal swelling with severe umbilical tenderness. No history of chronic cough nor contact with anyone with chronic cough. She had haemoptysis which began a week before her menses lasting for nearly three weeks, no history of fever nor weight loss. Examination showed a young lady in severe respiratory distress with respiratory rate of 32cycled per minute, she was not pale and not dehydrated. Examination of the chest revealed reduced right sided chest movement with respiration, there was an associated stony dull percussion notes and absence air entry on middle and lower lung zones. Abdominal examination revealed a mildly distended abdomen which move with respiration. And associated multiple tender umbilical nodules and with a positive fluid thrill. Digital Rectal Examination was essentially normal. Pleurocentesis (thoracocentesis) and paracentesis abdominis yielded haemorrhagic fluid both of which were acellular at cytology. Pre VAT chest-Xray showed homogenous opacification of right hemithorax (Fig 1).

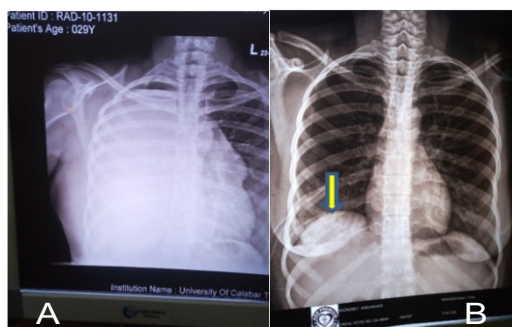


Fig 1 Haemorrhagic effusion Pre (A) and post drainage (B) showed a pulmonary nodule: A well-defined oval mass that lies at the right lower lung zone and obscures the right costophrenic angle. The mass measures 3.5cm in wide X 2.5cm in height (yellow)

Benign, malignancy and infective conditions that could present in these ways were all investigated and excluded. Pleural fluid biochemistry is in keeping with exudative pleural effusion. A diagnosis of TES was made after VAT with pleural biopsy and umbilical node biopsy. Chest X-ray post VAT drainage and biopsy showed a well-defined oval mass that lies at the right lower lung zone and obscures the right cardiophrenic angle. The mass measures 3.5cm wide and 2.5cm in height. Histology demonstrated endometrial tissue, stroma and glands.

**Case report 2:** Mrs. IAE is a 29-year-old  $P_0^{+0}$  being investigated for primary infertility, who was later referred to the Division of Cardiothoracic surgery by the gynaecologist with a history of recurrent progressive right-sided chest tightness and pain, worsening difficulty in breathing and progressive abdominal swelling of two years. These symptoms were non-cyclical. She noticed streak of frank blood while clearing her airway on this last admission which resolved without treatment. No fever nor weight loss. Physical examination revealed anxious-looking lady in moderate respiratory distress with respiratory rate of 28 cycles per minute, but not cyanosed with peripheral arterial oxygen saturation of 98% on room air. Other vital signs were essentially normal. Examination of the chest revealed reduced right-sided chest movement with respiration and chest expansion. Percussion notes were tympanic up to mid-zone of right chest and stony dull in lower zone. No air entry on auscultation. Abdominal examination showed a

moderately distended abdomen that moves with respiration and with positive shifting dullness. Digital Rectal Examination was essentially normal. Pleurocentesis (thoracocentesis) yielded air and haemorrhagic fluid, and paracentesis abdominis yielded haemorrhagic fluid both of which were acellular at cytology. Pre-VAT CXR showed air fluid level (right haemopneumothorax). GeneXpert and AFB were negative for tuberculosis. CA125: 206.7  $\mu$ /ml (0-35 units/ml) and CT-scan of abdomen and lower chest showed gross intraperitoneal fluid collection in all abdominal recesses as well as the pelvis. There was a massive right-sided haemopneumothorax with mediastinal shift to the contralateral side. She was placed on duphaston 20mg daily for three months. A repeat of CA-125 was 84.6 units/ml which excludes an ovarian carcinoma.

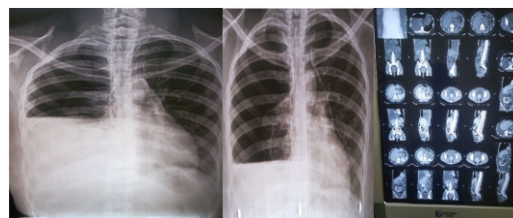


Fig 2. CXRs and Chest CT-scan demonstrating Haemopneumothorax

**Case report 3:** Miss J A. A 29-year-old lady, a filling station attendant who presented to us via Accident and Emergency with a history of gradual onset of right-sided chest pain, severe at outset and later dull and continuous, made worse with lifting heavy objects, this is associated with a progressive difficulty in breathing, initially after a whole day work but recently it is precipitated by walking from one pump to another and less with rest. She noticed a gradual onset of generalized abdominal discomfort and generalized abdominal swelling. There was an associated non-productive cough. No personal history of chronic cough nor contact with anyone with chronic cough and no haemoptysis. No history of fever nor weight loss. Examination showed a young lady in severe respiratory distress with a respiratory rate of 36 cycles per minute, she was acyanosed, she was not pale and not dehydrated. Her vital signs were essentially normal. Chest examination showed a reduced right-sided chest movement with respiration, there was an associated stony dull percussion notes and absence of air entry on



the right hemithorax. Abdominal examination showed a mildly distended abdomen which move with respiration, and with a positive shifting dullness. Digital rectal examination was essentially normal. Pleurocentesis (thoracocentesis) and paracentesis abdominis yielded haemorrhagic fluid both of which were acellular at cytology. Pre closed thoracostomy tube drainage chest X-ray showed homogenous opacification of right hemithorax. Full blood count, Erythrocyte sedimentary rate, Pleural aspirate AFB and GeneXpert were non diagnostic. A trucut pleural and lung biopsy demonstrated endometrial gland and stroma

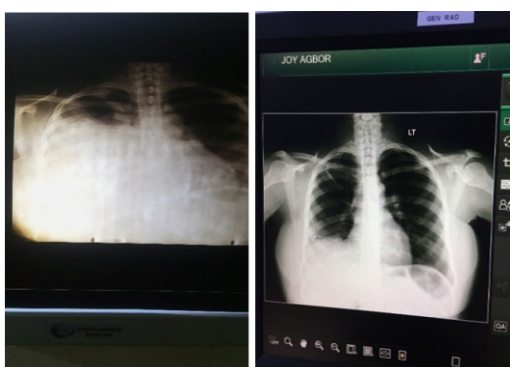


Fig 3. Catamenial haemothorax pre and post drainage

## Discussion

The prevalence of pelvic endometriosis in Calabar and Nigeria is unavailable. However, Fawole et al reported a prevalence of 48.1 % in Ibadan<sup>12</sup> and Adamou N in Kano reported a prevalence of 8.1%.<sup>13</sup> The prevalence of TES is equally unavailable. TES is a disease of the female gender as 100% of our patients were women within their reproductive life.<sup>14-17</sup> Two (66.6%) of our patients were biological siblings elder was diagnosed with the disease at age 26years while the younger was diagnosed at age 29year, it occurs early in the elder sibling that is three-year earlier than the younger sibling and a more severe form of TES, highlighting the fact that TES is a familial disease.<sup>18</sup> Two (66.6%) of our patients had no family history of the disease two of our patients had at least one TOP. Only one (33.3%) is married with primary infertility and with a stage IV genital endometriosis. Right sided chest pain, difficulty in breathing and non-productive cough were the most frequent presenting symptoms (100%) while generalized abdominal pain and

swelling was only present in 66.6% of our patients. Catamenial haemoptysis and haemopneumothorax<sup>15-17</sup> were less frequent findings (33.3%)

All our patients require closed tube thoracostomy<sup>15-17</sup> for complete drainage (100%), two (66.6%) had complete drainage and lung re-expansion (66.6%) and one had persistent lung collapse requiring lobectomy as imaging studies did not show air bronchogram nor Silhouette signs excluding atelectasis. Laparoscopy and VAT were indicated in all patients for management but only two could afford them. USS/CT-scan guided biopsy are other modalities in making definitive diagnosis. Medical management is quite expensive. Pregnancy seems to be the only natural means of delaying its manifestation and progression if fertility is desired.

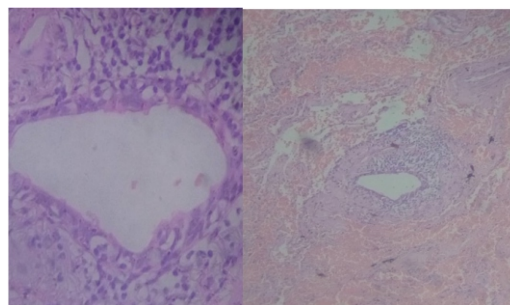


Fig.4: Histology of endometrial stroma and gland of lung biopsy

## Specific clinical entities

### Catamenial pneumothorax

Catamenial Pneumothorax (CP) account for 2.5-5% of cases in women with spontaneous pneumothorax,<sup>19,20</sup> even though it accounts for 73% of cases of TES. The first case of CP was described by Maurer et al in 1958 but the term CP was not introduced until 1972 CP described as spontaneous and recurrent occurring within 72hours following onset of menstruation.<sup>21</sup> According to Karpel et al, the numbers of pneumothoraces ranges from 2-42 per patient.<sup>22</sup>

Three theories have tried to explain this phenomenon. The first is transdiaphragmatic movement of air from the vagina to the peritoneum via the fallopian tubes, and subsequently into the pleural space through diaphragmatic fenestrations. This is believed to occur during menstruation when the cervix ostium is open.<sup>9</sup> The second is air leakage triggered by sloughing of the endometrial implants

located on the pleural surfaces.<sup>9</sup> The third mechanism is hormonal mediated process in which a high level of prostaglandins from the thoracic endometrial implants cause vascular and bronchiolar vasoconstriction leading to ischaemic injury with alveolar rupture and subsequent air leakage.<sup>9</sup> The aetiology of CP is multifactorial given that none of these theories alone accounts for the varied clinical presentations of CP. Patients with CP usually present with right sided pleuritic chest pain and dyspnoea<sup>9</sup> as our index patient. Rousset-Jablonski et al reported<sup>21</sup> that right sided pleuritic scapular pain was specific for Cp. Accurate diagnosis is enhanced with a high index of suspicion among women in their reproductive years who present with right sided chest pain and difficulty.

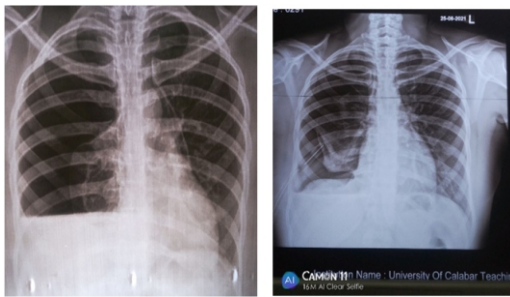


Fig 5: Catamenial Pneumothorax Pre and Post drainage

### Catamenial haemothorax

CH account for 14% of all cases of TES<sup>9</sup> but overall is a rare cause of pleural effusions like CP, the right hemithorax is commonly involved, bilateral haemothorax has been reported and left sided CH has been described. Clinical presentation includes acute onset of chest pain and dyspnoea. Diagnostic imaging usually reveals pleural effusion which range from 200-2000mls. CH is often associated with Pelvic and pleural endometriosis implants and diaphragmatic defects as seen during VAT23 suggesting pelvic-thoracic migration in keeping with the theory of retrograde menstruation.

### Catamenial haemoptysis

CHp is an uncommon presentation of TES, accounting for only 7% of all cases of TES and is rarely mentioned in the differential diagnosis of haemoptysis unlike other forms of TES. Pleuritic chest pain is not a common clinical presentation. Symptoms may not occur with every menstrual cycle although they can still occur frequently

throughout a patient's life time. Hibbard LT et al reported a patient with CHp with over 200 menstrual cycles. It is believed to be caused by endobronchial or lung parenchymal endometrial implantation<sup>24</sup> which is best explained by the microembolization theory. In a retrospective report by Kim CJ et al. 84.2% of their patients developed haemoptysis following obstetric and gynecologic procedure,<sup>24</sup> which is supported by the notion that trauma and uterine manipulation are predisposing factors for microembolization. Massive haemoptysis can result in asphyxiation and deaths, although death has not been reported.<sup>24</sup>

### Pulmonary nodules

Catamenial Pulmonary nodule (CPn) are rare presentation of TES, it is responsible for 6% of all cases of TES as such CPn is never mentioned as a differential diagnosis of solitary pulmonary nodule. The commonest clinical presentation of TES pulmonary nodules is haemoptysis because the implanted endometrial tissue may communicate with a bronchus, as primary pulmonary nodules are often asymptomatic (Fig.1).

Pulmonary nodule occurs commonly in older women in their late thirties compared with the other manifestations of TES with mean age of 34years. The implanted endometrial tissue may be surrounded by fibrotic tissues, appearing on pulmonary imaging as a mass or infiltrate and therefore mistaken for malignancy. Lee CH et al reported a pulmonary nodule as a well demarcated subpleural ovoid mass with cavitation or hyperintense nodules, are right sided<sup>25</sup> and commonly posterior as our index patient. Symptoms hardly correlate with menses and so time is wasted investigating for differential diagnosis of solitary pulmonary nodule which delays diagnosis.

### Diagnosis

These diagnostic modalities are found useful in guiding the diagnosis of TES. Such useful modalities include chest radiographs (CXR), computed tomography (CT), magnetic Resonance imaging (MRI) and bronchoscopy. CXR and CT are regarded as the most sensitive imaging modalities for detecting pneumothorax and haemothorax, MRI is considered preferable for the diagnosis of diaphragmatic endometriosis with a reported

Table 1. Showing patients' characteristics

PATIENT'S CHARACTERISTICS	IAE	EA	JA
SEX	Female	Female	Female (100%)
AGE@DIAGNOSIS	29years	26years	29years
FAMILY HISTORY	No	No	Yes (33.3%)
TOP	No	Yes (1)	Yes (1) (66.6%)
MARITAL STATUS	Yes	Single	Single
Chest Pain	Right sided	Right sided	Right sided (100%)
Difficulty in Breathing	Yes	Yes	Yes (100%)
Cough	Non-productive	Non-productive	Non-productive (100%)
Haemoptysis	No	Yes	No (33.3%)
Right Haemopneumothorax	Yes (33.3%)	Haemothorax (Right)	Haemothorax (Right)(66.6%)
Abdominal Pain/Swelling	No	Both	Both (66.6%)
Fertility	1°Infertility	Single	Single (33.3%)
Closed Thoracostomy Chest Drainage	Yes	Yes	Yes (100%)
Laparoscopy	Yes	Yes	No (66.6%)
VAT	Yes	Yes	No (66.6%)
Mechanical Pleurodesis	Yes	Yes	No (66.6%)
Chemical Pleurodesis	No	No	Yes (33.3%)
Medical Treatment	Yes	Yes	No (66.6%)

sensitivity of 73% to 83% and low specificity.<sup>25</sup> Pneumothoraces on CXR or CT can be of any size, these are usually right sided in 88%-100%, and may cause mediastinal shift<sup>26</sup>. Signs of TES that may be seen on CXR or CT includes pneumomediastinum, pneumoperitoneum, ground glass opacifications, bronchial wall thickening, thin walled cavities within the pulmonary parenchyma, or bullae formations.<sup>27</sup> Bronchoscopy, VAT biopsies and cytological brushing and washing are often limited as most endobronchial endometrial implants lies peripherally rather than on the mucosa of large bronchi.<sup>29</sup> Kul PH et al reported brush cytology to be superior to bronchoscopy-directed biopsies in bronchopulmonary endometriosis. VAT is considered to be the gold standard in the definitive diagnosis of diaphragmatic endometriosis.<sup>30</sup> In one of the largest review of patients with CP 52.1% were diagnosed with thoracic endometriosis based on VAT findings. The most commonly reported intraoperative findings includes diaphragmatic lesions 38.8%, endometriosis of the visceral pleura (29.6%), discrete lesions such as bullae, blebs or scarring 23.1% and no findings 8.5%.<sup>31</sup> In all the diagnostic imaging and tissue biopsies have variable results. The diagnosis of thoracic endometriosis by endoscopic visualization can be delayed due to focus on genital endometriosis, the variable appearance of endobronchial endometriotic lesions, experience of the endoscopist and the non-visualization of the diaphragmatic lesions behind the liver.<sup>8,31</sup> The

diagnostic imaging and biopsies may be improved if done at the time of menses than at the midcycle as the endobronchial lesions may have disappeared. The combination of VAT and VL approach as described by Nezhat et al in 2009 improve endoscopic evaluation for diagnosis of TES and use of atraumatic liver retractor to retract the liver caudally is advocated. In some cases, dividing the falciform ligament is necessary to allow for complete evaluation of the right hemidiaphragm. In addition, the use of a 30-degree endoscope or the adjustable viewing angle endoscope can further aid visualization.<sup>8,31</sup>

## Treatment

### Medical management

Medical management is the first line treatment for TES with the aim of suppressing ovarian hormone production. Medical treatment can be as neo adjuvant or adjuvant therapy to reduce the risk of recurrence. Typically, GnRH analogs are used as first line drugs, these are effective in suppressing the hypothalamus-pituitary- ovarian axis and the growth of endometrial like cells, and these are associated with the development of menopausal like symptoms and osteoporosis. Alternative to GnRH analogs include oral contraceptive, progestins, danazol, aromatase inhibitors and recently GnRH antagonist their efficacy is similar in these medications. Surgery should be considered in patients with refractory or recurrent disease.

### Surgical management

Surgical management require a multidisciplinary approach as genital endometriosis co-exist with TES in most cases When a patient present with symptoms suggestive of genital and TES a multidisciplinary surgical approach is required to treat both thoracic and genital endometriosis in a single setting this provides an optimal result. This approach combines VAT performed by a thoracic surgeon and VL performed by a gynecologic surgeon who are familiar with endometriosis. This method was used for 66.7% of our patients VATs is the gold standard in diagnosis and treatment of TES, mostly for CP and CH.<sup>9,28</sup> VATs allows for multiple treatment modalities depending on the location and identified lesions, in case of superficial endometriosis implant, it can be fulgurated using bipolar diathermy, CO<sub>2</sub> laser, Nd-YAG laser, argon



laser or plasma energy while deep endometriosis implant should be excised using sharp dissection.<sup>9</sup> In the case of wide spread parenchymal endometriotic nodules or large lesions, the appropriate operative course is a parenchymal sparing procedures such as wedged resection with stapling device, segmentectomy, or in some cases, lobectomy.<sup>9,19</sup> Other alternative intervention for TES is pleurodesis, this can be done mechanically with pleural abrasion and partial pleurectomy at VAT or chemically done with talc or tetracycline.<sup>9</sup> The use of pleurodesis has demonstrated to allow a median recurrence free interval of 61 months in 28 patients. It was reported to decrease the recurrence rate of CP after VATs by 20%-25% compared with those who did not have pleurodesis performed at the time of the surgery.<sup>9,32</sup>

### Treatment of Diaphragmatic Lesions

Endometrial tissue implantations on the diaphragm are seen commonly as black, blue, or reddish-purple in appearance. However, there is significant variety in the morphological appearance of endometriotic lesions with clear vesicular lesions, fibrotic white lesions, and liver adhesions has been reported.<sup>12</sup> For endoscopic treatment of diaphragmatic endometriosis, hydrodissection followed by excision or CO<sub>2</sub> laser vaporization for superficial lesions has been recommended.<sup>12</sup> Compared with electrocautery, the CO<sub>2</sub> laser is more precise with significantly less depth of penetration and less thermal spread. It can also reach areas behind the liver that are often difficult to access. When a CO<sub>2</sub> laser is not available other options are plasma jet energy and ultrasonic energy. These are preferred to the use of cold scissors due to the potential for bleeding. VAT's diagnosis and treatment of diaphragmatic endometriosis begins with an approach that will maximize visualization. Placement of a 10-mm port at the umbilicus and two or three additional ports in the left or right upper quadrant, depending on implant location, allows for inspection of the abdominopelvic cavity, posterior right hemidiaphragm, and the entire left hemidiaphragm. Optimal visualization of the diaphragm is obtained by positioning the patient in steep reverse Trendelenburg while gently pushing the liver caudally.<sup>28</sup>

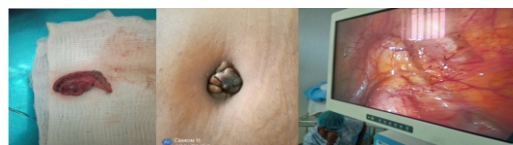


Fig 7. A. Lung biopsy at VAT B. Umbilical nodules and Laparoscopic findings

### Conclusion

When TES present with cyclical or acyclical right sided chest pain, cyclical or acyclical dyspnoea and haemoptysis, time and resources are usually wasted on investigating some common causes of haemoptysis in our environment. The diagnosis of TES can be made on accounts of these symptoms and if there is a family history made it more likely.

### References

1. Nezhat C, Falik R, McKinney S, King LP. Pathophysiology and management of urinary tract endometriosis. *Nat Rev Urol*. 2017; 14:359–372.
2. Nezhat C, Li A, Falik R. Bowel endometriosis: Diagnosis and management. *Am J Obstet. Gynecol*. 2018; 218:549–562.
3. Nezhat C, Main J, Paka C, Nezhat A, Beygui RE. Multidisciplinary treatment for thoracic and abdominopelvic endometriosis. *JSLs*. 2014; 18
4. Alifano M, Trisolini R, Cancellieri A, Regnard JF. Thoracic endometriosis: current knowledge. *Ann Thorac Surg* 2006; 81:761–9(4).
5. Young-Ranj L, Yo WC, Seok CJ, Seung SP, Jung-Ho K. Pleuropulmonary endometriosis: CT–pathologic correlation. *AJR* 2006; 186: 1800–1.
6. Al-Obaidy KI, Idrees MT. Endometriosis with cystic degeneration: a rare disease of males. *Int J Surg Pathol* 2018; 27:311–14.
7. Azizad-Pinto P, Clarke D. Thoracic endometriosis syndrome: case report and review of literature. *Perm J* 2014; 18:61–5.
8. Nezhat C, Main J, Paka C, Nezhat A, Beygui RE. Multidisciplinary treatment for thoracic and abdominopelvic endometriosis. *JSLs*. 2014; 18
9. Alifano M, Trisolini R, Cancellieri A, Regnard JF. Thoracic endometriosis: current knowledge. *Ann Thorac Surg* 2006; 81:761–9(4).
10. Vassilopoulou L, Matalliotakis M, Zervou MI, Matalliotaki C, Spandidos DA, Matalliotakis I, et al. Endometriosis and in vitro fertilisation.

- Exp Ther Med 2018; 16:1043–51.
11. Kesieme EB, Prasadov G, Welcker K, Abubakar U. Thoracic endometriosis syndrome: current concept in pathophysiology and management. *Orient J Med* 2016; 28:1–10.
  12. Fawole AO, Bello FA, Ogunbode O, Odukogbe AA, Nkwocha GC, Nnoaham KE, et al. Endometriosis and associated symptoms among Nigerian women. *Int J Gynaecol Obstet* 2015; 130:190–4.
  13. Adamou N, Umar UA, Mohammed FL. Prevalence of endometriosis among women undergoing diagnostic laparoscopy in a tertiary hospital North-West Nigeria. *N Niger J Clin Res* 2020; 9:65-8
  14. Ezemba N, Okafor OC, Emeruem NU, Adiri CO. Thoracic endometriosis syndrome in Nigeria: a single-centre experience. *Interact CardioVasc Thorac Surg* 2020; doi:10.1093/icvts/ivaa249
  15. Ekpe EE, Bassej EA, Umanah IN. Thoracic endometriosis syndrome; not so rare: report of 3 cases. *Case Study Case Rep* 2013; 3:95–102.
  16. Adeoye PO, Adeniran AS, Adesina KT, Ige OA, Akanbi OR, Imhoagene A, et al. Thoracic endometriosis syndrome at University of Ilorin Teaching Hospital. *Afr J Thorac Crit Care Med* 2018; 24:87–91.
  17. Adesanya OA, Kolawole OE. Thoracic endometriosis syndrome: cutting the Gordian knot—a case report and review of the literature. *Int J Surg Case Rep* 2020; 66:68–71
  18. Terzic M, Aimagambetova G, Kunz J, Bapayeva G, Aitbayeva B, Terzic S, et al. Molecular Basis of endometriosis and endometrial cancer: current knowledge and future perspectives. *Int J Mol Sci* 2021;22(17):9274
  19. Alifano M, Roth T, Broët SC, Schussler O, Magdeleinat P, Regnard JF. Catamenial pneumothorax: a prospective study. *Chest* 2003 Sep;124(3):1004-8.
  20. Furuta C, Yano M, Numanami H, Yamaji M, Taguchi R, Haniuda M. Nine cases of catamenial pneumothorax: a report of a single center experience. *J Thorac Dis* 2018; 10:4801–5.
  21. Rousset-Jablonski C, Alifano M, Plu-Bureau G, Camillen-Broet S, Rousset P, Regnard J, et al. Catamenial pneumothorax and endometriosis-related pneumothorax: clinical features and risk factors. *Hum Reprod* 2011;26(9):2322-9. DOI: <http://dx.doi.org/10.1093/humrep/der189>.
  22. Azizad-Pinto P, Clarke D. TES; case report and review of the literature. *Perm J*.2014; 18:61-5
  23. Nwiloh J. Diaphragmatic patch: a useful adjunct in surgical treatment of recurrent catamenial hemothorax. *Rev Port Pneumol* 2011;17(6):278-80.
  24. Kim CJ, Nam HS, Lee CY, Yum HK, Yang SH, Seo KH, et al. Catamenial hemoptysis: a nationwide analysis in Korea. *Respiration* 2010;79(4):296-301.
  25. Lee CH, Huang YC, Huang SF, Wu YK, Kuo KT. Thoracic endometriosis: rare presentation as a solitary pulmonary nodule with eccentric cavitations. *Thorax* 2009;64:919-20
  26. Marchiori E, Zanetti G, Rodrigues RS, Souza LS, Souza AS, Francisco FAF, et al. Pleural endometriosis: Findings on magnetic resonance imaging. *J Bras Pneumol*.2012; 38:797– 802.
  27. Legras A, Mansuet-Lupo A, Rousset-Jablonski C. Pneumothorax in women of child-bearing age: An update classification based on clinical and pathologic findings. *Chest*. 2014;145: 354–360.
  28. Rousset P, Rousset-Jablonski C, Alifano M, Mansuet-Lupo A, Buy JN, Revel MP. Thoracic endometriosis syndrome: CT and MRI features. *Clin Radiol*. 2014; 69:323–330
  29. Fukuda S, Hirata T, Neriishi K, Nakazawa A, Takamura M, Izumi G, et al. Thoracic endometriosis syndrome: Comparison between catamenial pneumothorax or endometriosis-related pneumothorax and catamenial haemoptysis. *Eur J Obstet Gynecol Reprod Biol*. 2018; 225:118–123
  30. Nezhat C, Nezhat, F, Nezhat, C. Nezhat S. Video-Assisted and Robotic-Assisted Laparoscopy and Hysteroscopy with DVD. 4th ed. New York: Cambridge University Press; 2013.
  31. Nezhat C. A multidisciplinary approach to diaphragmatic endometriosis. *MDedge. ObGyn News*.2017;1–7.
  32. Chen JS, Tsai KT, Hsu HH, Yuan A, Chen WJ, Lee YC. Intrapleural minocycline following simple aspiration for initial treatment of primary spontaneous pneumothorax. *Respir Med*. 2008; 102:1004–1010.