



Congenital lung cyst: Report of two cases

Ogbudu SO^{1,2}, Nwagboso CI¹, Echieh CP^{1,2}, Eze NJ¹, Etiuma AU^{1,2}, Bassey OO¹, Ugbem TI^{2,3},
Abdulrasheed J⁴

¹Division of Cardiothoracic/Vascular Surgery, Department of surgery, University of Calabar Teaching Hospital, Calabar, Nigeria

²Department of Surgery, College of Medical Sciences, University of Calabar, Nigeria

³Department of Pathology, University of Calabar Teaching Hospital, Calabar, Nigeria

⁴Department of Paediatrics, University of Calabar Teaching Hospital, Calabar, Nigeria

Abstract

Background: Bronchogenic cysts are lesions of congenital origin derived from the primitive foregut and are the most prevailing primary cysts of the mediastinum. Most commonly unilocular, they contain clear fluid or mucinous secretions or, less commonly, haemorrhagic secretions or air. They are lined by columnar ciliated epithelium, and their walls often contain cartilage and bronchial mucous glands. It is unusual for them to have a patent connection with the airway, but when present, such a communication may promote infection of the cyst by allowing bacterial entry. The first successful surgical excision of a bronchogenic cyst was reported by Maier in mid twentieth century leading to its classification based on Mailer postulation. No such reports have been described in South/South Nigeria.

Case summaries

Case 1: We present C.H. N, a 16year-old student who presented to us on account of recurrent foul-smelling productive cough and recurrent shortness of breath of 14years. She received several treatments for bronchial asthma and chest infection from a private hospital with no remarkable improvement. She also had occasional high-grade fever which also subside with this treatment. On general physical examination she was found to be in mild respiratory distress and not cyanosed with SPO₂ of 96-98% on room air. Examination of the chest revealed a left apical anterior chest wall flattening with the trachea deviated to the ipsilateral side, the percussion notes was dull and with bronchial breath sounds, and widespread crepitation and wheezes. Spirometric measurement revealed restrictive abnormality. Chest X-ray showed a homogenous opacity of left lower lung zone with no radiological evidence of bronchial wall thickness nor increased lung markings. A diagnosis of left congenital bronchogenic cyst was made. She was started on chest physiotherapy with a postural drainage, antibiotics, bronchodilators and exercise. She underwent left pneumonectomy.

Case 2: We present B F, a 5day-old neonate who presented to us on account of progressive difficulty in breathing and low peripheral arterial oxygen saturation of less than 60% on room air 12 hour after birth which improved to 98% on oxygen by nasal prong. She was delivered at a referral hospital in town and was subsequently referred to and admitted into the sick baby unit (SBU) of the University of Calabar

Corresponding Author:

Dr Dr Stephen Omirigbe Ogbudu,
Department of Surgery, College of Medicine, University of
Calabar, /Division of Cardiothoracic Surgery, Department of
Surgery, University of Calabar Teaching Hospital, PMB 1276,
Calabar 54271, Nigeria.

dveogbudustepheno@unical.edu.ng | +2348037244560

DOI: 10.61386/imj.v17i1.393

Teaching Hospital. General physical examination revealed a post termed neonate on oxygen by nasal prong, not in any form of distress, she was not cyanosed with SPO₂ of 98% on 1L/min of oxygen. She was mildly dehydrated. Examination of the chest revealed a bulging right chest wall with trachea deviation to the contralateral side. The Percussion notes were dull with absent air entry

over the right half of the hemithorax. The Chest X-ray showed an air-filled mass occupying the right middle and the lower lung zone causing mediastinal shift to the contralateral side with compressive collapsed of left lung. A diagnosis of congenital bronchogenic cyst was made. She was started on prophylactic vitamin K, antibiotics, IVF and nil per oral. She had blood workup and she underwent thoracotomy and cyst excision.

Conclusion: The diagnosis of congenital bronchogenic cyst should be made in adolescent or in neonates who presents with lung compression or recurrent infection symptoms.

Introduction

Bronchogenic cysts are lesions of congenital origin derived from the primitive foregut and are the most prevalent primary cysts of the mediastinum as in these two reported cases. Most often unilocular, they may contain clear fluid or mucoid secretions or, less commonly, haemorrhagic secretions or air. They are lined by columnar ciliated epithelium, and their walls often contain cartilage and bronchial mucous glands. It is not common for them to have a patent connection with the airway, but when present, such a communication may promote infection of the cyst by allowing bacterial entry. The first successful surgical excision of a bronchogenic cyst was reported by Maier in mid twentieth century leading to its classification called Maier's classification¹. No such reports have been described in South/South Nigeria.

Case report:

Case 1: We report a 16year-old student who presented to us with a history of recurrent cough productive of copious foul-smelling sputum of 14year with associated recurrent difficulty in breathing on severe exertion and lately at rest, however, there is no history of orthopnoea nor bipaedal swellings, there was a history of recurrent high-grade fever with chills and rigors at onset of each episode which subside to low grade and continuous fever. She is not a known asthmatic but was placed on occasional bronchodilators with no significance relieve of symptoms. She was seen in our surgical outpatient clinic on referral and admitted, investigated for a congenital bronchogenic cyst and to exclude pulmonary

tuberculosis. Results of investigations: AFB X3 was no MTB detected, sputum microscopy, culture and sensitivity did not grow bacteria, lung function tests at presentation and following weeks of chest physiotherapy, and post operation as showed in table 1. She underwent pneumonectomy with operative findings of left lung cyst occupying the upper part of the lower lobe extending downward and upward compressing the left lung with hypoplasia of the upper lobe which was non inflatable even with continuous positive airway pressure ventilation (CPAP) and adhesion of the lung to the pleurae, pericardium and mediastinum.

Table 1: Preoperative exercise equivalent of 5 flight of steps is predictive of survival post operation

Dates	FVC	FEV1	Predicted post-operative FEV1=FEV1 [1-no of lung segment 0.0526] (L)	Post-operative FEV1=FEV1 [1-no of lung segment 0.0526] (%)
18/11/12	1.64L	1.64L	0.86L	22.9
25/11/12	2.68	1.36	0.72L	24.1
2/12/12	2.79	1.74	0.92	30.7
13/12/12	1.78	1.01		35
15/12/12	1.85	1.11		37

Histology: Sections shows lung tissue displaying interstitial pneumonia, composed of lymphocytic exudates involving the interalveolar tissue. In some alveolar space there are fibrin exudates. The pleurae are involved in organizing pleurisy with large area of progressive fibrosis with occasional desquamate changes are seen in the smaller airway.

Case 2: We report a 5day-old neonate who presented to us on account of progressive difficulty in breathing and low peripheral oxygen saturation of less than 60% on room air which improved to 98% on oxygen by nasal prong. She was delivered at a referral hospital in town by vertex delivery and child cried immediately after birth. She was later referred to and admitted into the sick baby unit (SBU) of the University of Calabar Teaching Hospital. The pregnancy was postdate and uneventful. The general physical examination showed a post termed neonate on oxygen by nasal prong, not in any form of distress, she was not cyanosed with SPO2 of 98%. She looked mildly dehydrated. Examination

Table 2: Patient's characteristics

Patient's characteristics	Case 1	Case 2	Remarks
Sex	Female	Female	100%
Age at Presentation	16 th Year	Second day of life	
Difficulty in breathing	Mild	Severe	
SPO2 at presentation	97-98%	60%	Large cyst with severe compression
Features of Infection	Recurrent chest infection requiring hospital admission	Nil	
Side of cyst	Left sided, in between lobes and compress both lobes	Right sided, in between the middle and lower lobes compressing both lobes	50%
Types of Presentation	Acute on chronic	Acute	
Type of Surgery	Lt Pneumonectomy	Rt cyst excision	
Location of cyst	Upper part of Lt lower lobe	Between the Rt middle and lower lobes	Both were the intrapulmonary cysts

of the chest revealed a bulging right chest wall with trachea deviation to the contralateral side and move less with breathing. The percussion notes were dull on the right half of the hemithorax and on the left lower half of the left hemithorax with absent air entry over the right lower half of the hemithorax and lower half of the left hemithorax. The chest X-ray showed an air-filled mass occupying the right middle and the lower lung zones causing mediastinal shift and compression collapsed of left lower lobe. A diagnosis of right congenital bronchogenic cyst was made. She was started on prophylactic vitamin K, antibiotics, IVF and nil per oral. Both had a successful surgery and are living normal lives.

Discussion

The girl presented to us 14 years after the onset of recurrent cough productive of copious foul-smelling sputum with associated recurrent difficulty in breathing present both on severe exertion and lately at rest but no bipaedal swelling. This was associated with initial high-grade fever with chills and rigors which subside to low-grade continuous fever. These findings are similar to work done by Sarper, et al¹ that concluded that symptomology of bronchogenic cysts are variable. She was not a known asthmatic but had received steroids, bronchodilators and antibiotics. She was seen at the outpatient clinic following referral, she was admitted, investigated for pulmonary tuberculosis. Results were all negative for tuberculosis. Chest X-ray (Fig 1 & 2) suggested a mass on the left lung

field occupying almost the entire left hemi thorax and the CT-Scan (Fig 5) showed a huge emphysematous bulla in the left upper lung zone with the rest of the field showing extensive dilated cyst occupying almost the entire lower lung zone with multiple cystic bronchiectasis of the left lung. She had a combination of chest physiotherapy, pre-operative exercise, antibiotics and bronchodilators. She eventually had dry cough with an improved lung function test as showed in table 1. She had a left pneumonectomy due to long standing compression of otherwise health lung with extensive fibrosis and non-inflation of the lung. Pathologic examination confirmed the diagnosis of bronchogenic cyst (Fig 7).

Patient presented with FEV1 of 1.6L which was inadequate for pneumonectomy, she had chest physiotherapy, antibiotics and pre-operative exercise with a marginal increase in FEV1 to 1.7L (Table1) and considering other physiological parameters and ECOG of zero, she had pneumonectomy with initial drop in FEV1 but presently patient is doing well at full capacity. The second patient was a 5-day old female neonate who presented to us although, referred twelfth hour after birth because of progressive difficulty in breathing and low peripheral arterial oxygen saturation. She had a Chest X-ray and a chest CT-scan (Fig 7) both of which showed an air containing cyst. She was managed on oxygen by nasal prong, nil per oral, intravenous fluid and antibiotics, her father became her walking donor. The size of the cyst determines the time of patient's presentation. The larger the size of the cyst, the worse the compressive symptoms and the early the presentation as in this second case. She had the cyst excised through a muscle sparing right posterolateral thoracotomy and excision of the cyst.

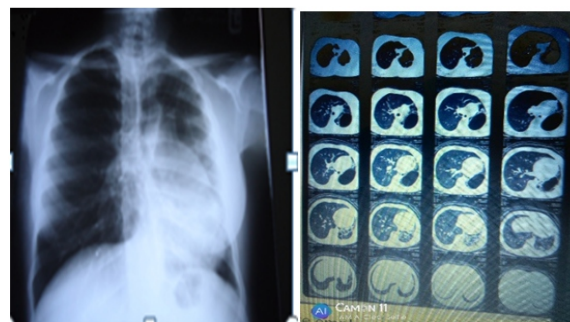

Fig 1. Chest X-ray / CT-scan showing a mass occupying almost the left hemi thorax (Case 1)

Congenital bronchogenic cyst is a congenital pulmonary malformation from the primitive foregut with a prevalence of 1: 42,000-68,000. It is the most common primary cyst of the mediastinum¹, it constitutes 13-15% of the congenital lung cyst and 6-10% of all primary intrathoracic masses in the infancy and children. They are formed from the abnormal budding of the ventral foregut anywhere along the respiratory system and oesophagus². The location of the bronchogenic cyst can vary depending on the time of their formation³ Up to 85% are in the mediastinum and 12% in the lung parenchyma involving the lower lobes whereas, in one of our patients it was located in the upper part of the left lower lobe enlarging downward and upward compressing the lower and upper lobe parenchyma. While in the second patient it arises from the junction between the right middle and right lower lobes.

Sarper, et al¹ in their series reported 4 of their 6 cases were located in the upper lobe However, un-usual locations like the neck, pericardium or abdomen have been reported.^{4,5} There is a male preponderance in patients with bronchogenic cyst with a male to female ratio of 81.8%:18.2%.^{1,5} Whereas all of our only patients were female. The age at diagnosis ranges from the neonatal period through the sixth decade.

However, the majority of bronchogenic cysts are diagnosed in patients below the age of 10years, one third diagnosed by the age 2 and 10% in the neonatal

period.^{1,5}

Tibet, et al reported that bronchogenic cysts were symptomatic in 70.8% of all affected children,¹ these symptoms are either secondary to their compressive effect of the enlarged cyst on adjacent structures or infection in the cyst². In our first patient it was a combination of both compression and infection. In the second patient it was more of compressive symptoms.

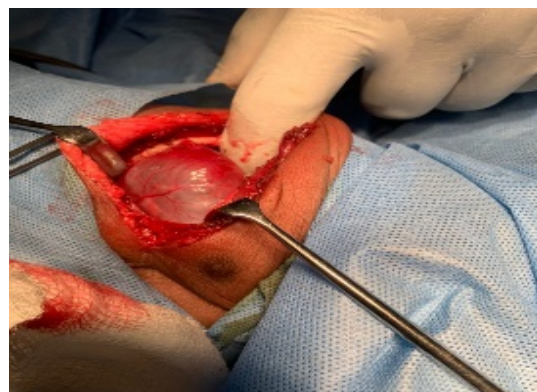

Fig. 5 The bronchogenic cyst as seen at operation (case 2)

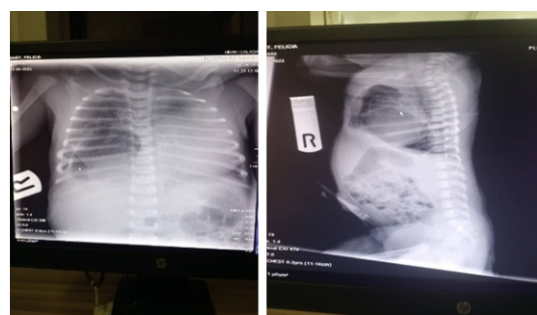


Fig 6: Right Upper lobe congenital cyst (case 2)

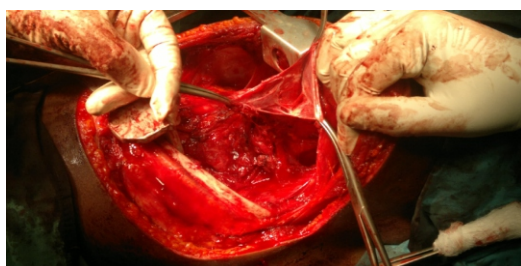


Fig. 3 (case 1)

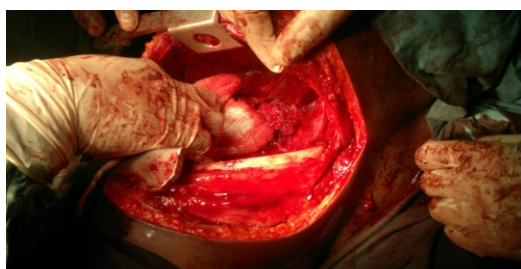


Fig. 4 (case1)

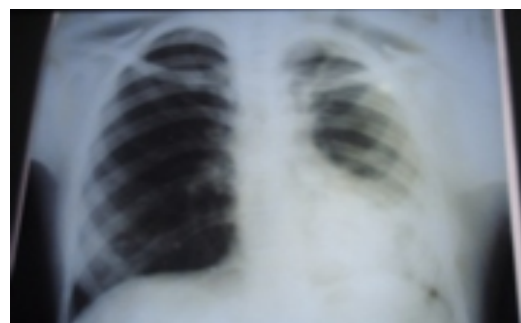


Fig 2: Chest X-ray showing the mass occupying almost the left hemi thorax following chest physiotherapy, bronchodilators and antibiotics pre operation

Compression is common in infants and young children presenting as intercostal recession, cough, and wheeze while infection is more common in the adults presenting as recurrent pneumonia.¹ Considering the duration of symptoms in our first patient it is a combination of both infant and adult's symptoms. In rare conditions congenital mediastinal bronchogenic cyst can present in the neonatal periods with severe respiratory distress and stridor¹ as in our second case.

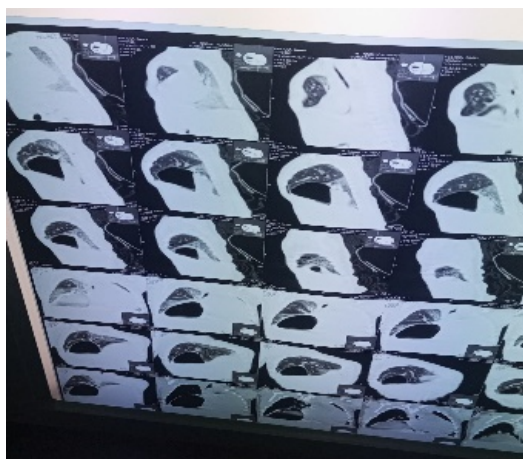

Fig 7: Chest CT Scan showing cyst occupying half of the right chest. (Case 2)

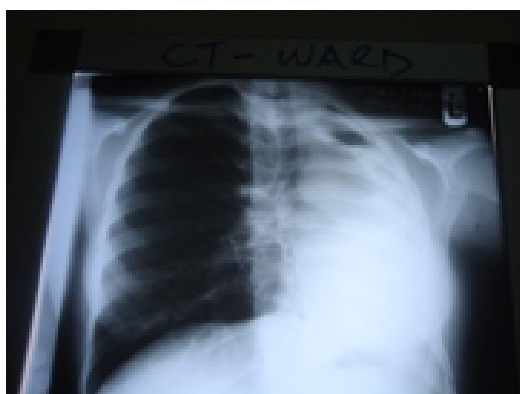

Fig 8. Post-pneumonectomy (Case 1)

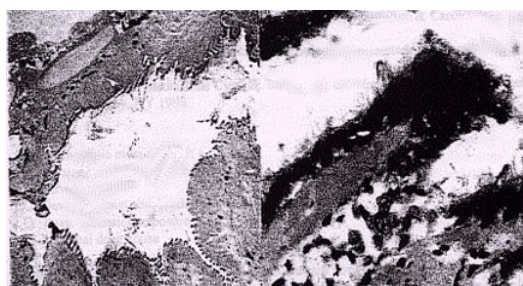


Fig 9a: Histology for case 1

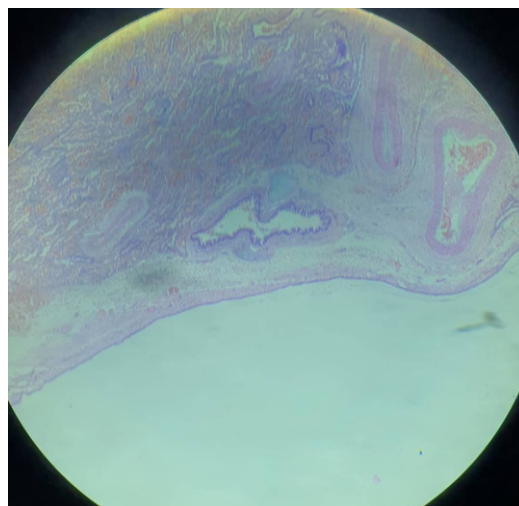


Fig: 9b (case 2)

Conclusion

Congenital bronchogenic are rare primitive foregut malformations that can present at birth and up to the 6th decade. It usually presents with either compressive or infective symptoms or a combination of the two. The diagnosis is easy to make if patient present in neonatal periods than in adolescent and adulthood where quality time and resources are wasted in investigation and treatment for other conditions.

References

1. Sarper A, Ayten A, Golbasi J, Demircan A, Isin E. Bronchogenic Cyst. *Tex Heart Inst J*. 2003;30(2):105-108.
2. Abushahin A, Zarrong A, Wagdi M, Janah I. Bronchogenic cyst as an un usual cause of a persistent cough and wheeze in children: A case Report and literature Review. *Hindawi*. 2018; 1:1-4.
3. Jiang JH, Yen SL, Less SY, Chuang JH. "Differences in the distribution and presentation of bronchogenic cysts between adult and children " *Journal of Pediatr. Surgery* 2015;50(3):399-401.
4. Chowdhury MM, Chakraborty S. "Imaging of congenital lung malformations" *Seminars in Paediatric Surgery* 2015;24(4):168-175.
5. Lee EY, Boiselle PM, Cleverland RH. "Multidetector CT evaluation of congenital lung anomalies" *Radiology* 2008; 247(3):632-648.