

Medical Case Report

HSI Journal (2023) Volume 4 (Issue 1):481-484. <https://doi.org/10.46829/hsijournal.2023.6.4.1.481-484>



Open
Access

Spontaneous pneumothorax in pregnancy: a case report and literature review

Ama A TAMATEY ^{1*}, Kwame A ADOMAKO ², Gordon OFFEI-LARBI ²,
Isaac OKYERE ³, Michael Y NTUMY ¹

¹ Department of Obstetrics and Gynaecology, University of Ghana Medical School, College of Health Sciences, University of Ghana, Accra, Ghana; ² National Cardiothoracic Centre, Korle-Bu Teaching Hospital, Korle-Bu, Accra, Ghana; ³ Directorate of Surgery, School of Medical Sciences, Kwame Nkrumah University of Science and Technology, Kumasi, Ghana

Received July 2022; Revised March 2023; Accepted May 2023

Abstract

Spontaneous pneumothorax occurring in pregnancy is a rare condition that can be life-threatening if not recognized and treated on time. We present a 38-year-old primigravida at 34 weeks gestational age who presented with a 2-week history of progressive dyspnoea. Clinical assessment was consistent with a right pneumothorax which was confirmed by a chest x-ray. She was managed with a right chest tube insertion. She later had an elective cesarean delivery. Six months later, both mother and baby were fine. The clinical significance of this article is that pneumothorax in pregnancy may mimic some complications of pregnancy itself and may thus be missed if the clinician does not have pneumothorax also in mind.

Keywords: Spontaneous pneumothorax, pregnancy, dyspnoea, clinical significance, Ghana

Cite the publication as Tamatey AA, Adomako KA, Offei-Larbi G, Okyere I, Ntummy MY (2023) Spontaneous pneumothorax in pregnancy: a case report and literature review. HSI Journal 4 (1):481-484. <https://doi.org/10.46829/hsijournal.2023.6.4.1.481-484>

INTRODUCTION

Pregnant women may present with dyspnoea due to an underlying disease condition or the pregnancy itself. Dyspnoea during pregnancy is caused by a decrease in the pulmonary functional reserves, which can be attributed to increased oxygen consumption by the placenta, fetus, and maternal organs [1]. The physiologic effects of anaemia in pregnancy may also lead to dyspnoea [2]. Pneumothorax, which occurs when air enters the pleural cavity, is a serious medical condition that can cause sudden chest pain and dyspnoea. It is usually due to the rupture of apical blebs or bullae. This condition is particularly dangerous during pregnancy and can have severe consequences for both the mother and fetus. Although rare, the occurrence of pneumothorax during pregnancy has been reported in only about 82 cases in the medical literature as of 2018 [3].

CASE

A 38-year-old primigravida at 34 weeks gestational age presented with a 2-week history of progressive dyspnoea. She was initially dyspnoeic with mild exertion and subsequently became dyspnoeic at rest. There was no prior history of chest trauma, cough, fever, weight loss, loss of appetite, or drenching night sweats. She had two myomectomies done eight and six years ago. The antenatal scans showed normal scan parameters, and the pregnancy was also uneventful. On initial assessment, she was dyspnoeic, anicteric, afebrile, not cyanosed with a pulse rate of 100 beats per minute (bpm) and blood pressure of 110/75 mm Hg. Heart sounds were normal, and no murmurs were heard. The respiratory rate was 26 breaths per minute. The percussion note was hyper-resonant on the right, with a reduced air entry. The peripheral oxygen saturation (SpO₂) was 97% on room air. An abdominal lead shield protection chest x-ray showed a right pneumothorax. There was an area of radiolucency with absent lung markings and partial lung collapse. Other examination findings and tests were within normal limits for her gestational age.

* Corresponding author
Email: aatamatey@ug.edu.gh

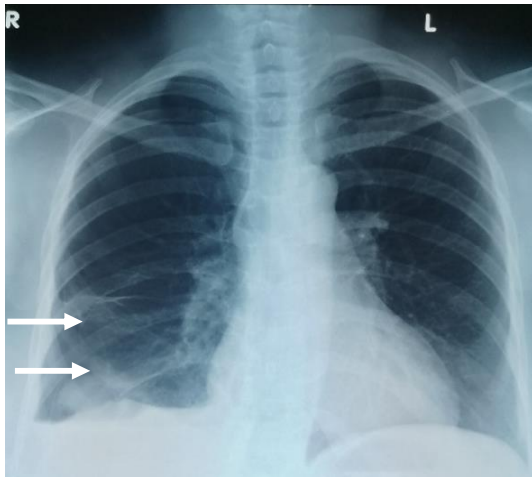


Plate 1: Chest x-ray showing right pneumothorax (arrows).
R, right; L, left

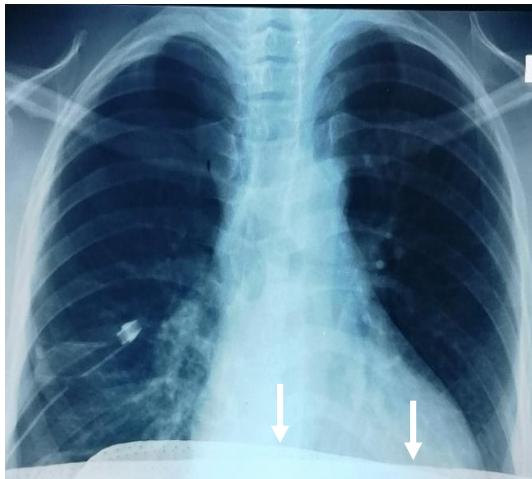

Plate 2: Chest x-ray with chest tube in-situ, with an abdominal shield (arrows)

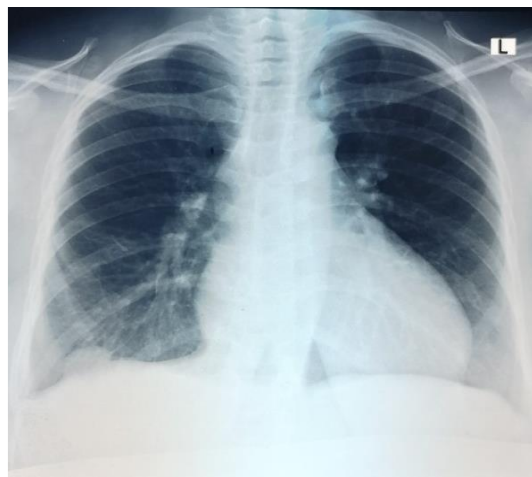

Plate 3: Chest x-ray showing full lung expansion after chest tube removal

She was managed by a multidisciplinary team of cardiothoracic surgeons and obstetricians together. A right chest tube was inserted. The patient's condition improved. The chest tube stopped bubbling after 9 days. A repeat chest x-ray confirmed full lung expansion. The chest tube was removed, and she was discharged from the hospital. She was readmitted at 38 weeks of gestational age and had an uneventful caesarean delivery. The caesarean delivery was on account of two previous myomectomies. Repeat chest x-ray and Computed Tomography (CT) scan six 6 months later were normal.

DISCUSSION

There are a lot of physiological changes which affect the respiratory system during pregnancy. There is increased oxygen demand reaching 20% above baseline values by term, which may further increase to 50% above baseline values during delivery [4]. There is also an increase in minute ventilation by 30 to 50% due to the direct stimulation of the respiratory centre by progesterone. This primarily increases the tidal volume [4,5,6]. Despite the cephalad displacement of the diaphragm caused by the gravid uterus, there is an increase in angulation from 68 to 103 degrees, representing an increase of 50%. This further leads to an increase in the tidal volume [5]. Any impairment in this complex physiology during pregnancy leads to hypoxia in the mother which can adversely similarly affect the fetus.

Primary spontaneous pneumothorax is the presence of air in the pleural space in an otherwise healthy individual with no lung pathology and without a precipitating external event. This pathology, occurring during pregnancy is rare, with less than 50 cases reported as of 2007 [7], and 56 cases by 2010 [8]. By 2020, 87 cases had been reported [9]. Due to the paucity of cases, there have been no clear guidelines for its management. Even though this condition is rare, it has a high reoccurrence rate in the same and subsequent pregnancies up to parturition [10]. The majority of patients with this condition are young, with an average age of 26.6 years, and have low parity, with a mean gravidity of 1.9. The majority of the cases occur in the perinatal period while others occur in the first or second trimester [3]. The patient described in our current study was not young but had a low parity as she was pregnant for the first time. The major differential diagnoses include acute pulmonary embolism, pleuritis, pneumonia, myocardial ischaemia or infarction, pericarditis and musculoskeletal pain [3,4].

Rupture of small apical subpleural blebs or bullae is the most common cause of pneumothorax in pregnancy. Although the mechanism of a bleb or bulla formation is unknown, it is thought to be due to either increasing negative pressure or greater mechanical alveolar stretch at the apex of the lungs during growth or a congenital phenomenon in which lung tissue at the apex grows more quickly than the vasculature, thereby outstripping its blood supply [8,11]. Other causes of this condition include

cavitary tuberculosis, asthma, pulmonary lymphangioliomyomatosis, endometriosis, cocaine abuse, current or past cigarette smoking, hyperemesis gravidarum, previous pneumothorax, and alcohol use [8,11]. Clinical presentations of spontaneous pneumothorax include pleuritic chest pain, acute dyspnoea, and easy fatigability. The pain is usually felt on the ipsilateral side since pneumothorax is usually unilateral but may be central or bilateral in rare cases with bilateral pneumothorax. Dyspnoea may be mild to severe relating directly to the volume of air in the pleural space and indirectly to the degree of pulmonary reserve. It may progress to tension pneumothorax, which may be fatal for both the pregnant woman and her fetus. The diagnostic investigations are chest X-rays and or CT scans, using a lead shield to protect the fetus from ionizing radiation [12]. Bedside ultrasonography is helpful, especially in unstable patients.

The treatment of pneumothorax in pregnancy is the same as in non-gravid patients. Mild cases can be managed conservatively if the patient is not dyspnoeic [3]. For more severe cases, aspiration or a chest tube insertion is performed. Patients with persistent air leaks or recurrences may have pleurodesis, video-assisted thoracoscopic surgery (VATS) thoracotomy or open thoracotomy [3]. Our patient had a chest tube insertion which lasted for 9 days after which the air leak stopped. Persistence of the air leak beyond 14 days would have necessitated a VATS thoracotomy or an open procedure. Pleurodesis was not done for this patient because this was the first occurrence with no further episodes in the current pregnancy. Subsequent pregnancies have been known to occur without recurrence of the pneumothorax. Follow-up examinations showed no recurrence even after 6 months, indicating that further intervention was not necessary. In the absence of obstetric indications for cesarean delivery, it is recommended to plan for an assisted delivery with epidural anaesthesia to minimize maternal pushing effort as much as possible, particularly when nearing term [3,11]. Due to the patient's history of two previous myomectomies, she underwent an elective cesarean delivery at term under spinal anaesthesia.

Conclusion

Pneumothorax in pregnancy is a rare condition but clinicians need to have a high index of suspicion of it when there is dyspnoea in pregnancy.

DECLARATIONS

Ethical considerations

Informed consent was obtained from the patient's caregivers for this report. Ethical approval was not required because the report is a single case presentation with de-identified patient information. All ethical issues have been considered to protect the patient's rights.

Consent to publish

All authors agreed to the content of the final paper.

Funding

This research was conducted with personal funds, with no external sponsorship or financial support

Competing Interests

No potential conflict of interest was reported by the authors.

Author contributions

AAT, KAA, and MYN were involved in the management of the case, drafting of the report, and final review of the report. GO-L contributed to the management of the case and provided a final review of the report. IO reviewed the report. All authors have reviewed and agreed to the content of the final paper.

Acknowledgements

The authors are grateful to the staff of the Korle Bu Teaching Hospital Department of Obstetrics and Gynaecology and the National Cardiothoracic Center for their support in the management of the patient.

Availability of data

All relevant information is provided in the manuscript. The published information is available from the corresponding author upon a reasonable request.

REFERENCES

1. Bonica JJ (1974) Maternal respiratory changes during pregnancy and parturition. *Clin Anesth* 10:1-32.
2. Prowse CM, Gaensler EA (1965) Respiratory and acid-base changes during pregnancy. *Anesthesiology* 26:381-392.
3. Lateef N, Dawood M, Sharma K, Tauseef A, Munir MA (2018) Recurrent spontaneous pneumothorax in pregnancy – a case report and review of the literature. *J Community Hosp Intern Med Perspect* 8(3):115–118.
4. Akçay O, Uysal A, Samancılar O, Ceylan KC, Sevinc S, Kaya SO (2013) An unusual emergency condition in pregnancy: pneumothorax. Case series and review of the literature. *Arch Gynecol Obstet* 287:391-394. <http://doi.org/10.1007/s00404-012-2510-4>.
5. Bobrowski RA (2010) Pulmonary physiology in pregnancy. *Clin Obstet Gynecol* 53:285-300.
6. Crapo RO (1996) Normal cardiopulmonary physiology during pregnancy. *Clin Obstet Gynecol* 39:3-16.
7. Lal A, Anderson G, Cowen M, et al (2007) Pneumothorax and pregnancy. *Chest* 132:1044–1048
8. Garg R, Sanjay DV, Usman K (2008) Spontaneous pneumothorax: an unusual complication of pregnancy—a case report and review of the literature. *Ann Thorac Med* 3:104–105.
9. Agrafiotis AC, Assouad J, Lardinois I, Makou GA (2020) Pneumothorax and pregnancy: a systematic review of the current literature and proposal of treatment recommendations. *Thorac Cardiovasc Surg* 69(1):95-100. <http://doi.org/10.1055/s-0040-1702160>.
10. Terndrup TE, Bosco SF, McLean ER (1989) Spontaneous pneumothorax complicating pregnancy - case report and review of the literature. *Emerg Med* 7:245–248.

11. Tanase Y, Yamada T, Kawaryu Y (2007) A case of spontaneous pneumothorax during pregnancy and review of the literature. *Kobe J Med Sci* 53:251–255.
12. Van Winter JT, Nichols FC, Pairolero PC (1996) Management of spontaneous pneumothorax during pregnancy: case report and review of the literature. *Mayo Clin Proc* 71:249–252.

Thank you for publishing with

