

## **PYRIDOXINE RESPONSIVE MEGALOBLASTIC ANAEMIA IN PREGNANCY: A CASE REPORT OF TWO PATIENTS**

\*AMINU S.M., \*BABADOKO A.A., \*SULEIMAN A.M., \*ISAH A.D., \*\*RANDA W A A.J.,  
\*\* ANEKWE N.

\* Departments of Haematology and "Obstetrics and Gynaecology Ahmadu Bello University Teaching Hospital, Zaria - Nigeria.

Correspondence:

Dr. BABADOKO A.A.  
Department of Haematology  
Ahmadu Bello University Teaching Hospital, Zaria. Email-  
ababadoko@yahoo.com

### **ABSTRACT**

In pregnancy megaloblastic anaemia commonly results from folic acid deficiency partly due to placenta transfer to fetus, but mainly because of increased folate catabolism due to cleavage of folate coenzymes in rapidly proliferating tissues. Cobalamin deficiency causing megaloblastic anaemia has been described in infants born to severely cobalamin deficient mothers, but its deficiency is very rare. Similarly Pyridoxine deficiency is also rare but if it does occur, it is often in association with deficiency in several B- Complex vitamins. We report a case of megaloblastic anaemia in pregnancy which was responsive to pyridoxine with a view to increasing the awareness of pyridoxine deficiency complicating megaloblastic anaemia.

**KEY WORDS: Megaloblastic Anaemia, Pyridoxine Deficiency, Pregnancy**

### **INTRODUCTION**

Megaloblastic anaemias are a group of disorders characterized by the presence of a distinctive morphological appearance of the developing red cells in the bone marrow.<sup>1</sup> They are a consequence of a disturbance of DNA synthesis that results from cobalamin deficiency, folic acid deficiency, and acquired and congenital defects of purine and pyrimidine

metabolism.<sup>1,2</sup> Anaemia due to Cobalamin deficiency generally stems from an inability to absorb the vitamin (pernicious anaemia) from food rather than dietary deficiency.<sup>1,3,4</sup> Cobalamin deficiency is uncommon in pregnancy, partly because of the rarity of pernicious anaemia and partly because of the infertility that accompanies it.<sup>3,4</sup> Nevertheless there have been isolated reports of newborn infants with dietary Cobalamin deficiency due to maternal anaemia or to maternal dietary deficiency associated with a vegan diet.<sup>5</sup> Pregnancy normally causes a relative folate deficiency, as do haemolytic disorders with a high turnover of cells and DNA synthesis.<sup>2</sup> Normal folic acid requirements can usually be met from dietary intake except when cooking methods destroy the folic acid available in food or when starvation occurs? Without folate supplementation, more than a third of pregnant women show signs of subnormal post partum serum folate levels and up to 3.4% have megaloblastic anaemia.<sup>6</sup> Megaloblastic anaemia due to severe folate deficiency in late pregnancy with normal red cell folate level has been reported in Chelsea and Westminster Hospital, London, United Kingdom.<sup>7</sup> This leads to the consideration of giving folate supplementation for all women throughout pregnancy in order to avoid dietary deficiency.<sup>7</sup>

Isolated pyridoxine deficiency rarely occurs and is often associated with deficiency in other B complex vitamins.<sup>8</sup> Pyridoxine concentrations are said to decline during pregnancy as a physiologic adjustment secondary to increased blood volume or as a result of increased requirement for active transport across the placenta.<sup>8</sup> There is little literature of Pyridoxine deficiency complicating other nutritional deficiency anaemias, in this report we described the first case of pyridoxine responsive megaloblastic anaemia, elucidating the diagnostic and management constraints in our resource limited setting with a view to raising the awareness of such nutritional deficiency interaction.

## **CASE REPORTS**

### **CASE 1**

A 32-year-old para4+0 4 alive female with six months amenorrhoea, was referred to Ahmadu Bello University Teaching Hospital (ABUTH) from a private hospital with anaemia in pregnancy. She was admitted to the antenatal ward having had no antenatal care. She was transfused with 3 units of packed cells in the index pregnancy at the private hospital and another two units in the antenatal ward prior to Haematologist consultation. No bone pains or bleeding from any external orifices. She is a trader and sells furniture and curtain materials. She is the only wife of her husband and neither smoked cigarettes nor ingested alcohol. Her husband is a furniture maker.

Examination revealed a young woman who is ill looking, severely pale but anicteric. The liver, spleen, peripheral lymphadenopathy and kidneys were not palpably enlarged, that could suggest a malignancy. The symphysiofundal height was 22cm. There were no focal neurological deficits.

Complete blood count showed a packed cell volume (PCV) of 0.16, WBC of  $4.2 \times 10^9$  cells/L (Differential count: Neutrophils 66%, Eosinophils 02%, Lymphocytes 32%), Platelet count of  $258 \times 10^9$ /L and reticulocytopenia of 0.01%, indicating a very poor marrow response despite the severe anaemia. Blood film showed anisocytosis, macrocytosis with some hypersegmented neutrophils. Haemoglobin electrophoresis was AA pattern. Bone marrow aspirate and biopsy were hypercellular and megaloblastic with myeloid erythroid reversal, erythroblast with nuclear cytoplasmic maturation asynchrony, giant myelocytes and dysplastic megakaryocytes. Storage iron was adequate with evidence of incorporation. Biochemical analysis of the vitamins such as serum and red cell folates, serum cobalamin, methylmalonic acid, homocysteine, holotranscobalamin and lactate dehydrogenase levels could not be done due to lack of diagnostic tools. Serum chemistry, liver function and viral serology were not contributory. The diagnosis was Severe Megaloblastic anaemia in pregnancy secondary to Nutritional deficiency (Folic acid or Cobalamins ).

The patient had another 2 units of packed red cells transfused, and was empirically treated with oral folate 5mg daily, intramuscular vitamin B12 (hydroxycobalamin 1000ug for 7 days) and an oral dose of ferrous sulphate 200mg thrice daily. She was also advised on a diet with folate and cobalamins-containing food. She had serial haemogram including reticulocytes count on day 1, 3, 7, and 11 of commencement of nutritional correction. There was no appreciable response, the average reticulocytes count was 0.5% with a PCV of 0.18. Following a literature search oral pyridoxine 100mg daily was added on the 12th day and 3 days later the reticulocytes count rose to 5% and 12% by

the 9th day of commencement of vitamin B6. This increase was maintained and plateaus at a PCV of 0.32. Therapy was continued for 6 months and then vitamin B12 once yearly. She had no further transfusion and baby was clinically well at the time of delivery.

## CASE 2

A 30-year-old Nigerian, para3+4 3 alive, was referred to ABUTH, with four months amenorrhoea, anaemia, lower abdominal pains and fever. There was no history of drug administration such as antiepileptic, anticonvulsants or anti-inflammatory agents. No bone pains or bleeding from any external orifices. She was had 2 units of packed cell transfusion, antimalaria (chloroquine) and (analgesic) paracetamol at the referral hospital a week prior to presentation without improvement. She is the only wife of a Baker and neither smoked cigarettes nor drinks alcohol.

Examination revealed a young woman who was acutely ill looking with severe palor. The liver, spleen, lymph nodes and kidneys were not palpably enlarged. The symphysiofundal height was 16cm. There were no focal neurological deficits.

Complete blood count showed a PCV of 0.12, WBC of  $12.8 \times 10^9$  cells/L (Differential count: Neutrophils 76%, Eosinophils 04%, Lymphocytes 20%), Platelet count of  $221 \times 10^9/L$  and reticulocytes count of 0.01%, indicating a very poor marrow response despite the severe anaemia. Blood film showed anisocytosis, macrocytosis, hypersegmented neutrophils with toxic granulation. Haemoglobin genotype was AA. Bone marrow aspirate and biopsy were hypercellular and megaloblastic. Serum chemistry, Liver function test, viral serology were not contributory but Urinalysis revealed a proteinuria of 1+. Serum level of folates and B12 were not done due to lack of

diagnostic tools. The diagnosis therefore was Severe Megaloblastic anaemia in pregnancy secondary to Nutritional deficiency (Folic acid or Cobalamins) with Urinary tract infection.

The patient was transfused with a unit of red cells, antibiotic (ceftriaxone) and empirically treated with oral folate 5mg daily, intramuscular vitamin B12 (hydroxycobalamin 1000ug for 7 days, an oral dose of ferrous sulphate 200mg thrice daily without the expected reticulocytes response after two weeks. She was also advised her on folate and cobalamins-containing food. However with addition of pyridoxine 100mg daily, a remarkably response was obtained as evident by the increase in the reticulocytes count of 4% and 9% on the 3rd and 7th day respectively. She had no further transfusion, mother and baby were well at the time of delivery. Nutritional correction was continued for 6 months except for vitamin B12 which was continued once yearly.

## DISCUSSION

This report is of particular interest in practice, as pyridoxine deficiency is rare. Its deficiency was only entertained, following non response to physiological doses of well known and commonly implicated nutritional deficient nutrients (Folic acid, vitamin B12 and iron). It is not surprising to find a megaloblast marrow as Pyridoxine deficiency occurs usually in association to folic acid and vitamin B12 deficiency.<sup>8</sup> Pyridoxine deficiency has been associated with preeclampsia, carbohydrate intolerance, hyperemesis gravidarum and neurological disease of infants. Although few studies and textbooks report its association with megaloblastic anaemia even though pyridoxine act as a coenzyme in the side chain in the biochemical interaction of folic acid and vitamin B12 metabolism.<sup>1</sup> Lack of radioisotope dilution

or enzyme linked-immunosorbent assays in our locality, which are frequently automated techniques hinders its serum measurement.<sup>1</sup>

These patients are prone to developing megaloblastic anaemia most likely due to folic acid deficiency in view of their poor socioeconomic status, multiple pregnancies which creates a state of depleted folate stores. The present pregnancy may have tilted them to a state of negative balance with no supplementation having had no antenatal care. Of particular interest is the presence of macrocytosis (macro-ovalocytosis) and hypersegmented neutrophils as they are strong markers of Folate deficiency: Studies performed in the 1960s and 1970s in unsupplemented women showed that 25% had evidence of megaloblastic change on bone marrow aspiration in late pregnancy.<sup>9</sup> Pregnancy is associated with a negative folate balance as it is required for growth of the foetus, placenta, and maternal tissues, and the foetus actively accumulates folate reserves.<sup>1,3,4,9</sup> Estimates of the dietary requirement in pregnancy are between 100-600ug. whereas the average daily intake in unsupplemented women in a recent study in United Kingdom was 237ug.<sup>10</sup> megaloblastic anaemia follows 17-19 weeks of negative folate balance.<sup>9</sup> In the UK 0.5-5% of pregnant women not receiving supplementation have been found to have megaloblastic anaemia, with prevalence dependent on nutritional and socioeconomic status.<sup>10</sup> Vitamin B12 deficiency in these patients is unlikely due to rarity of pernicious anaemia couple with the association of infertility with vitamin B12 deficiency and a daily requirement of about 1-3ug with a store of 3mg and an enterohepatic circulation in the range of 0.5-5ug.<sup>1,3,4</sup> Although diagnostic constraints hampers serum assays of these vitamins been the standard of diagnosis. the growing concern that widespread use of folate

supplementation in pregnancy may lead to neurological sequelae because of the unmasking of vitamin B12 deficiency call for the need to add vitamin B12 in the therapy of this patient. There is also a lack of evidence to suggest a coexisting malignancy in these cases. It is often appropriate to establish which of the two deficiencies. folate or Cobalamin, is the cause of the anaemia and treat accordingly. Pregnant women with megaloblastic anaemia being treated with nutritional supplementation may also have a coexisting iron deficiency due to depletion of body stores which may be already poor and worsened with recovery of the bone marrow erythroblasts; this led to a concomitant treatment with iron to avoid iron deficiency.

## CONCLUSION

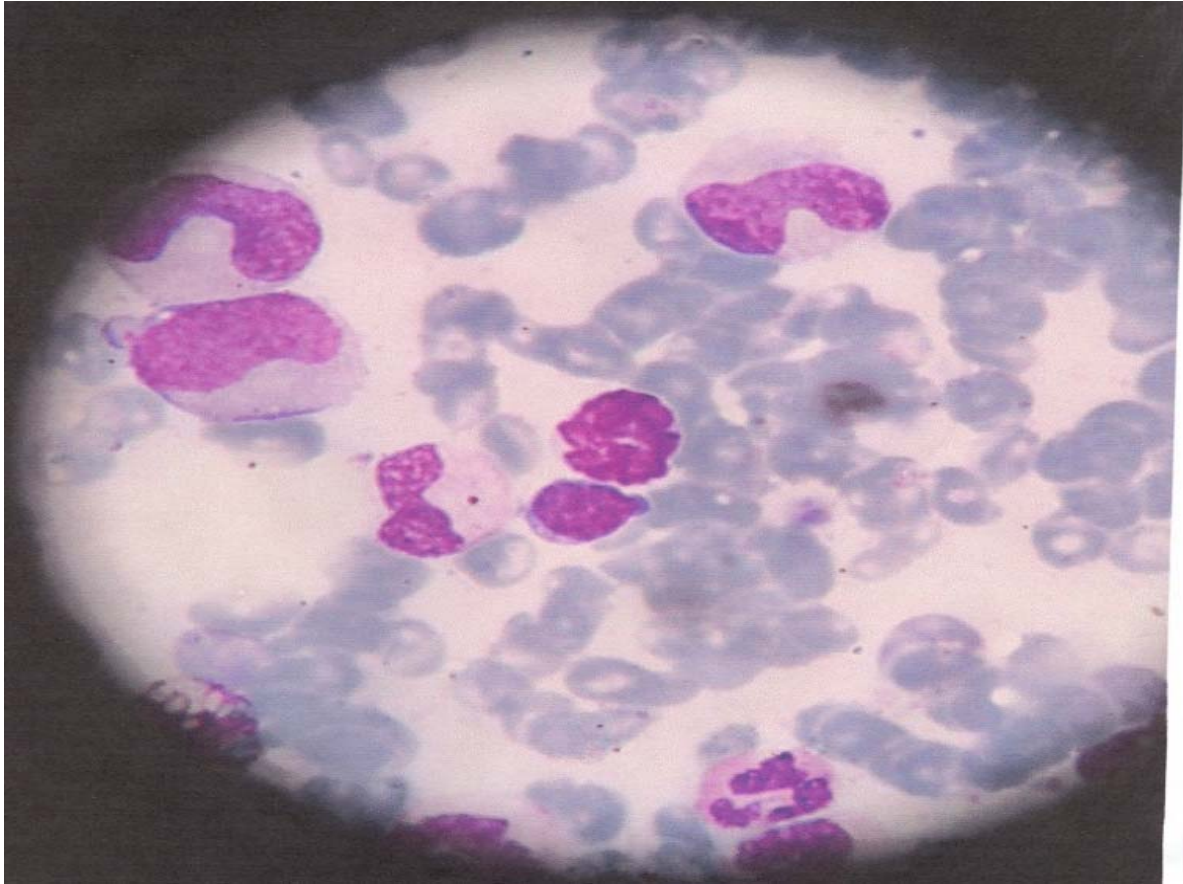
Pyridoxine deficiency may occur in pregnancy usually in association with folate and cobalamin deficiency, as its deficiency alone may not be clinically apparent. We propose that consideration be given to pyridoxine supplementation in addition to iron, folates and vitamin B12 for all pregnancy women where an objective diagnosis of severe megaloblastic anaemia is established.

## REFERENCE

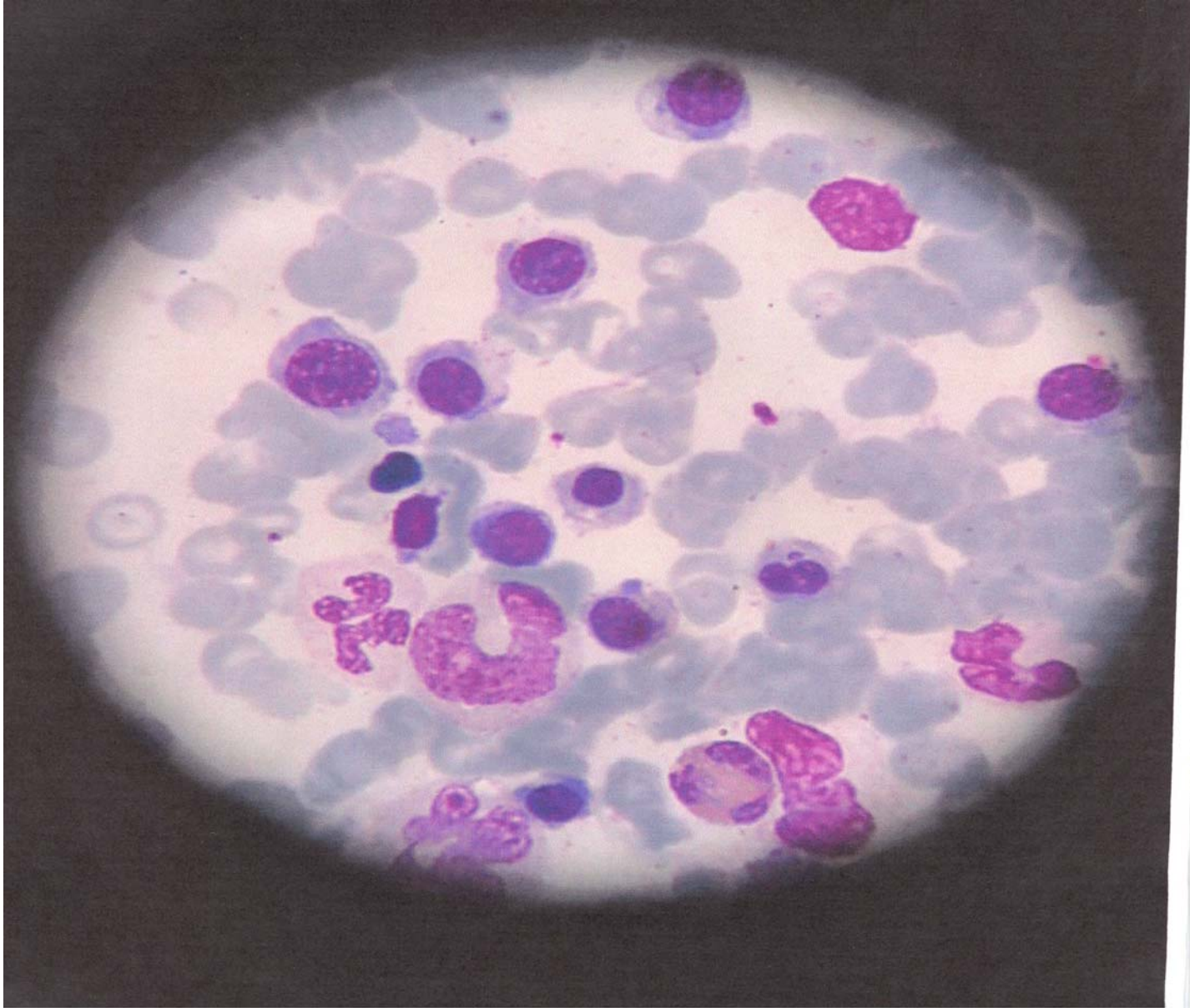
1. Victor A. Hoflbrand and Ralph Green. Megaloblastic anaemia. In: Hoflbrand A.V, Mitchell S. L, and Tuddenham G.D (eds). Post Graduate Haematology. 5th edition. London: Arnold, 2004: 60-84.
2. Cambell BA. Megaloblastic anaemia in pregnancy. Clin. Obste. Gynecol 1995; 38: 455-462.
3. Schilling RF, Williams WJ. Vitamin B12 deficiency: Underdiagnosed, Over treated? Hosp Pract (Off Ed) 1995; 30: 47-52.

4. Pruthi RK, Tefferi A. Pernicious anaemia revisited. *Mayo Clinic Proc* 1994; 69: 184-150.
5. Sklar R. Nutritional Vitamin B12 deficiency in breast-fed infant of vegan-diet mother. *Clin Pediatr (phila)* 1986; 25: 219-221.
6. Willoughby ML, Jewell FG. Folate status throughout pregnancy and in postpartum period. *Br Med J* 1968; 4: 356-360.
7. Rosie Burton, Zoe Kelion, Christine Costello. Severe folate deficiency in pregnancy with normal red cell folate level. *Clin. Lab. Haem.* 2006; 28: 66-68.
8. Moghissi KS. Risks and benefits of nutritional supplements during pregnancy. *Obstet Gynecol* 1981; 58:685-785.
9. Chanarin I. and Rothman D. Further observation on the relation between iron and folate status in pregnancy. *British Medical Journal* ii 1971: 81-84.
10. Langley-Evans S.C and Langley-Evans A. J. Use of folic acid supplements in the first trimester of pregnancy. *Journal of the Royal Society of Health* 2002; 181-186.

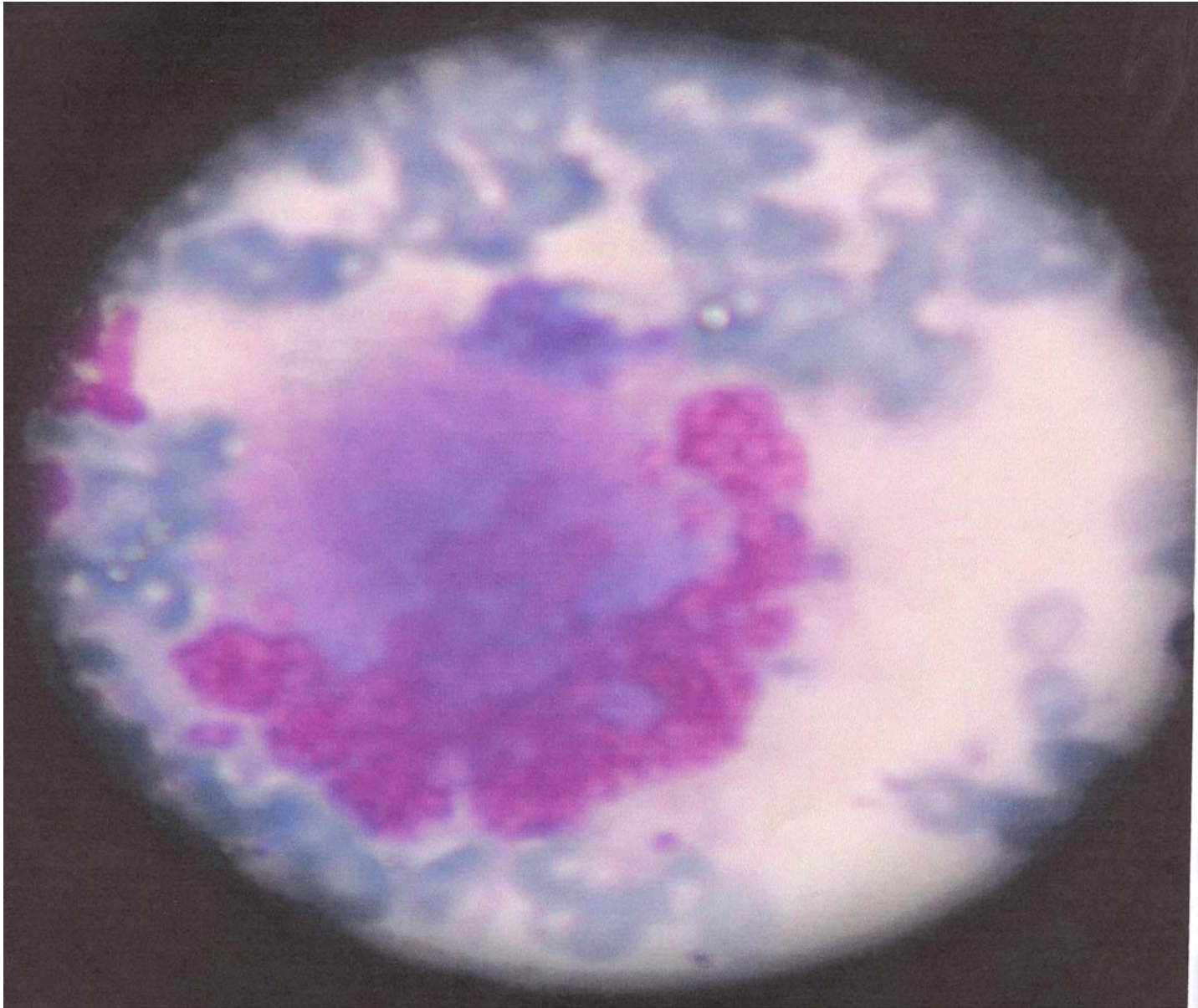
**IMAGES SHOWS HIGH POWER VIEW X100 (OIL IMMERSION) OF BONEMARROW ASPIRATE OF CASE 1**



**B 6-1: SHOWS GIANT MYELOCYTES, METAMYELOCYTES AND BANDED MYELOID PRECURSORS.**



**B 6-2: SHOWS MEGALOBLAST, SOME WITH NUCLEAR CYTOPLASMIC ASYNCHRONY**



**B 6-3: SHOWS DYPLASTIC MEGARKARYOCTES**