

Oropharyngeal stenosis following traditional uvulectomy- case report of challenges in anesthetic and surgical management

Erdo S Isamade¹, Adeyi. A. Adoga², Mangei A Ngeh¹, Andrew A Iduh²

Abstract

Background: Severe oropharyngeal stenosis (OPS) associated with dysphagia and stunted growth is an unusual complication of traditional uvulectomy in children; an unpopular practice still occurring in Africa.

Methods: We present anaesthetic and surgical challenges in the management of a 19 year old female with this complication scheduled for uvulopharyngoplasty.

Results: The peri-operative airway challenge was managed by tracheostomy, which was used for inhalational anaesthesia,

and allowed free surgical access of pharynx for the surgeon.

Conclusion: Patients with severe OPS will benefit from elective pre-operative tracheostomy, to avoid intubation problems and allow sharing of airway for surgical access.

Keywords: Traditional uvulectomy, Oropharyngeal stenosis, Tracheostomy, Uvulopharyngoplasty

Highland Med Res J 2014;14(2):110-112

Introduction

Traditional uvulectomy has been mentioned variously in the past as a harmful practice amongst several societies in Africa^{1, 2} and the Middle East³ presenting with deleterious consequences such as hemorrhage with anemia, septicemia, tetanus and the risk of the human immunodeficiency virus (HIV) infection^{4, 6}. However, traditional uvulectomy is an unusual cause of severe oropharyngeal stenosis (OPS) resulting in difficult intubation and surgery. The common etiological factors of oropharyngeal stenosis listed in literature are corrosive agents and exposure to radiation^{7, 8}. Surgical trauma during adeno-tonsillectomy has been associated with OPS⁹. We report this uncommon complication of traditional uvulectomy and highlight some challenges encountered in the management of oropharyngeal stenosis.

Case Report

A 19-year-old female of Yoruba ethnic group presented to our otolaryngology outpatient clinic with 9-years history of progressively worsening dysphagia to solids,

nasal regurgitation of meals, and recurrent right ear discharge. These symptoms followed traditional uvulectomy she was subjected to by her parents for an unknown throat ailment. Other associated symptoms were occasional right otalgia, bilateral tinnitus and hearing loss. On clinical examination, she was found to be stunted with a height of 1.29 meters and a weight of 27.8 kg with a body mass index of 16.7 kg/m². There was marked narrowing of the oropharynx with a round opening measuring approximately 3cm in diameter. There were fibrous bands extending from the free edge of the soft palate to the superior ends of the tonsil pillars with absent uvula (Figure 1). Otoscopy revealed pus on the floor of the right external auditory canal with approximately 20% central perforation of the right tympanic membrane. The left tympanic membrane was intact, bulging and hyperemic with negative Rinne test on the right, positive Rinne test on the left and Weber test lateralized to the right. Anterior rhinoscopy revealed pus on the floor of the left nasal cavity with patent nostrils. A working diagnosis of oropharyngeal stenosis with velopharyngeal incompetence following traditional uvulectomy was made.

Pure tone audiometry showed mild conduction deafness in both ears with pure tone averages of 41dB in the right ear and 40dB in the left ear. Type B curve was recorded for the right ear while a type C curve for the left ear on tympanometry. Other laboratory investigation results were within normal limits. She was scheduled for an elective oropharyngeal dilatation under general anesthesia. Pre-operative airway assessment was Mallampati 4 indicating the probability of a difficult intubation¹⁰. management intra-operatively. Following

¹Department of Anesthesia, Jos University Teaching Hospital, PMB 2076, Jos, Plateau state, Nigeria

²Department of Otorhinolaryngology, Head and Neck Surgery, Jos University Teaching Hospital, PMB 2076, Jos, Plateau state, Nigeria

All correspondences to:

Dr. E. S. Isamade, Department of Anesthesia, Jos University Teaching Hospital, PMB 2076, Jos, Plateau state, Nigeria

E-mail: eisamade@yahoo.co.uk

IV induction with thiopentone and suxamethonium, laryngoscopy revealed Cormach and Lehane grade IV¹¹.

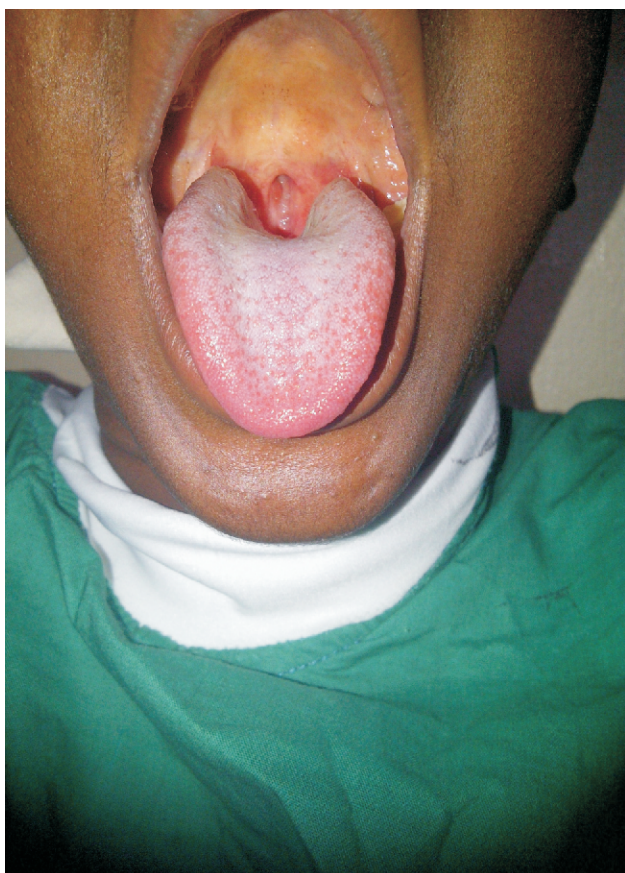


Figure 1. Absent uvula and narrowing of oropharynx with a small opening in a 19 year old girl following traditional uvulectomy

Attempted intubation failed with resulting desaturation (SPO₂ 84%). She was sedated by inhalational anaesthetics in 100% oxygen, and successfully intubated, using movement of laryngeal muscles as guide. Analgesia was with fentanyl and paracetamol. Oropharyngeal dilation was not successful due to inability to identify pharyngeal structures. A temporary tracheostomy was performed with the insertion of a size 6 cuffed portex tube, to avoid post-operative airway obstruction from oedema following traumatic airway manipulation (Figure 2). Subsequently, she then had uneventful modified uvulopalatopharyngoplasty under general anaesthesia where the adhesions were released, with the stenosed oropharynx widened and tonsils dissected. A nasogastric (NG) tube was inserted for immediate post-operative feeding, which was discontinued on the 7th post-operative day as oral feeding around the tube was established 2 days prior to this. The tracheostomy tube was removed on the 10th post-

operative day. Otologic symptoms regressed remarkably following surgery.

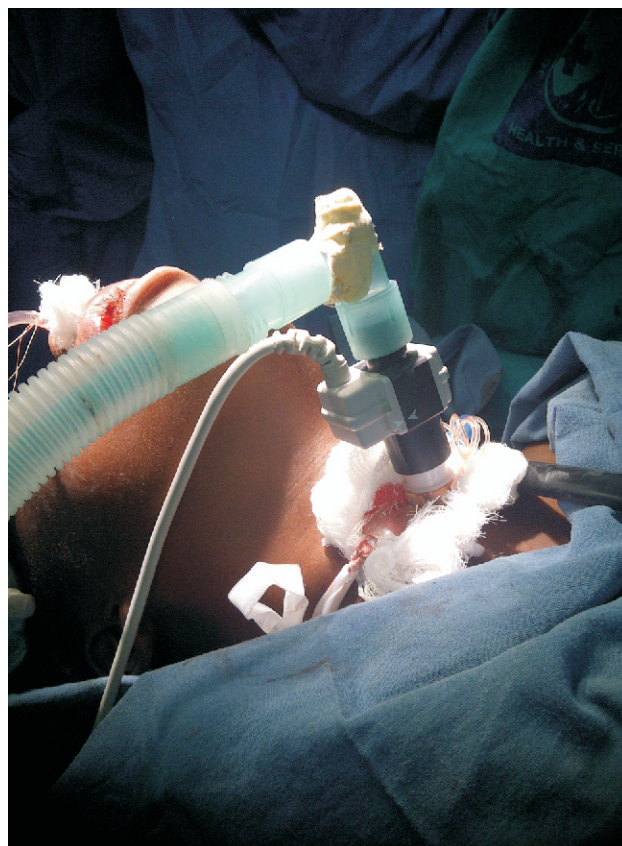

Figure 2. Tracheostomy performed for anaesthesia in a 19 year old girl with oropharyngeal stenosis following traditional uvulectomy

She was discharged home on the 12th post-operative day and followed up in the outpatient clinic without events. There has been significant improvement in audiometry, oropharyngeal structure and functions, evidenced by absence of dysphagia and patient has gained weight.

Discussion

Oropharyngeal stenosis (OPS) is a narrowing of the oropharynx in the region of the soft palate, lateral pharyngeal walls and base of the tongue caused by adhesions of the anterior pillars and inferior tonsillar fossae to the tongue base appearing as a cicatricial scar¹². It is a rare but challenging problem usually caused by corrosives and radiation.^{7,8} The most common aetiology currently is surgical trauma associated with adenotonsillectomy stenosis. In the patient presented, it was due to traditional uvulectomy, a dangerous practice still occurring in Africa and the Middle-East¹⁻³. Oropharyngeal stenosis is an unusual complication of traditional uvulectomy. The common complications

include haemorrhage with anaemia and infections such as septicaemia and tetanus⁴⁻⁶. Despite public enlightenment on the dangers of this traditional practice, it still persists.

Management of OPS is challenging for both anaesthetists and surgeons. These include difficult airway management, narrow surgical field (working in a tunnel as airway is shared), possibility of severe blood loss/ difficulty in assessing blood loss, and if OPS is severe enough, malnutrition due to dysphagia as occurred in the patient presented. Pre-operatively, the airway of the patient was assessed as Mallampati grade 4¹⁰, so difficult intubation was anticipated and prepared for. However, upper airway obstruction was not a presenting feature, hence IV induction and suxamethonium were administered but intubation attempts proved abortive while neuromuscular paralysis lasted. When spontaneous respiration returned, under deep inhalational anaesthesia, and with guidance of laryngeal muscular contraction, the endotracheal tube was successfully passed without visualization of laryngeal inlet. Apart from upper airway obstruction, in other situations where securing the airway is doubtful, intubation may be guided/aided by laryngeal muscular activity during inhalational induction with spontaneous respiration¹³.

Airway problems are not restricted to intra-operative period alone; sequel to airway manipulation and trauma, post-operative airway oedema may present as upper airway obstruction. To avoid this complication, a temporary tracheostomy was performed, and the tube was removed on the 10th post-operative day, when the oedema had subsided.

Sharing of airway by anaesthetists and surgeons is another challenge. The endotracheal tube (ETT) may be on the surgeon's way of dissection, and the mouth gag used for retraction by the surgeon may compress and block the ETT. A north facing nasal RAE (Ring, Adair and Elwyn) tube will allow better surgical access to the oral cavity. This patient had a tracheostomy performed, which was used for administration of inhalational anaesthetics; and it solved the problem of airway sharing.

Uvulopalatopharyngoplasty is associated with severe pain, as this area has a rich supply of nerves to coordinate pharyngeal and laryngeal reflexes. Hence adequate intra and post operative analgesia was given in form of combined opioids and paracetamol intra-operative, and combined non-steroidal anti-inflammatory drugs (NSAIDs) and paracetamol post-operatively. To provide adequate nutrition and hasten recovery, a feeding tube was passed, and discontinued

when oral feeding was established. The patient improved and gained weight, and had no complaints on follow up. Early presentation and management of this patient could have prevented the stunted growth, which cannot be completely reversed at age 19 years.

Patients with severe OPS may benefit from elective pre-operative tracheostomy, to avoid intubation problems and sharing of airway, to allow free surgical access. In the absence of a tracheostomy tube, intubation should be done preferably under deep inhalational anaesthesia rather than muscle paralysis.

Conflict of Interest

None declared in this work.

References

1. Ijaduola GT. Uvulectomy in Nigeria. *J Laryngol Otol.* 1981;95: 1127-1133.
2. Adoga AA, Nimkur LT. The traditionally amputated uvula: still an ongoing practice. *ISRN Otolaryngol.* 2011; 2011: 704924.
3. Ravesloot MJ, de Vries N. A good shepherd but with obstructive sleep apnea syndrome: traditional uvulectomy case series and literature review. *J Laryngol Otol.* 2011; 125: 982-986.
4. Lowe KR. Severe anemia following traditional uvulectomy in Kenya. *Military Medicine.* 2004; 169: 712.
5. Eregie CO. Uvulectomy as an epidemiological factor in neonatal tetanus mortality: observations from a cluster survey. *West Afr J Med.* 1994; 13: 56-58.
6. Johnston NL, Riordan PJ. Tooth follicle extirpation and uvulectomy. *Austr Dent J.* 2005; 50: 267-271.
7. Sun-Yung K, Tae Hoon O, Hwa Mi k et al. A case of corrosive injury-induced pharyngeal stricture treated by endoscopic adhesiolysis using an electrosurgical knife. *Gut Liver.* 2011; 5: 383-386.
8. Sringer R, Priestnall L, Cullen R, Fischer NC. PWE-025 post radiotherapy pharyngeal/proximal esophageal strictures in head and neck malignancy: outcome of endoscopic bougie dilation. *Gut.* 2012; 61: A307.
9. Mc Laughlin K E, Jacobs I N, Todd N W, Gussack G S, Carlson G: Management of nasopharyngeal and oropharyngeal stenosis in children. *Laryngoscope* 1997 ;107: 1322– 1331.
10. Mallampati Gatts P, Guccino LD, Desai P, Waraksa B, Freibergde RP: A clinical sign to predict difficult tracheal intubation: a prospective study. *Can Anaesth Soc J* 1985; 32: 429-434.
11. Cormack R.S, Lehane J. Difficult tracheal intubation in Obstetrics. *Anaesthesia* 1984; 39: 1105-1111.
12. Santos VB, Ruffy ML, Polisar IA. Stenosis of the oropharynx treated with intra-lesional triamcinolone. *Ear Nose Throat J.* 1977; 56:164-167.
13. Hillman DR, Platt PR, Eastwood PR. The upper airway during anaesthesia. *Br. J. Anaesth* 2003; 91:31-39.